



Available online at
ScienceDirect
www.sciencedirect.com

Elsevier Masson France
EM|consulte
www.em-consulte.com/en



ORIGINAL ARTICLE

Cerebral venous thrombosis during relapse of ulcerative colitis: Case report with review of literature



S. Bouchal^{a,d,*}, B. Alami^b, N. Chtaou^{a,d}, M. Abkari^c,
M. Maaroufi^b, F. Belahsen^{a,d}

^a Department of Neurology Hassan II University Teaching Hospital, Fez, Morocco

^b Department of Radiology Hassan II University Teaching Hospital, Fez, Morocco

^c Department of gastroenterology Hassan II University Teaching Hospital, Fez, Morocco

^d Laboratory of Epidemiology, Clinical Research, and Health Community, Faculty of Medicine and Pharmacy, Sidi Mohammed Ben Abdallah University, Fez, Morocco

Received 8 October 2020; accepted 8 December 2020

Available online 14 January 2021

KEYWORDS

Ulcerative colitis;
Cerebral venous
thrombosis;
Relapse;
Risk factor

Summary Cerebral venous thrombosis (CVT) is a rare but serious complication of ulcerative colitis (UC) with a high morbidity and mortality rate. CVT is not usually readily recognized and treatment may be delayed, impacting on the prognosis. Here we are reporting 2 cases of CVT occurring during a relapse of ulcerative colitis (UC) with review of literature. The first patient was a 27-year-old woman with chronic UC who presented with headaches during a relapse of chronic UC. She was found to have cerebral venous sinus thrombosis. The second one was a 45-year-old man who presented with seizures and focal neurological symptom during a relapse of chronic UC. He was found to have cerebral venous sinus thrombosis complicated by left temporal infarction. Both of them were treated with therapeutic anticoagulation with good improvement. The presence of neurological signs in a patient with UC mostly during exacerbation period, should alert health professionals about the possibility of a CVT.

© 2020 Published by Elsevier Masson SAS.

Background

Inflammatory bowel disease (IBD), comprises two major entities Crohn's disease (CD) and ulcerative colitis (UC). It is characterized by a chronic inflammatory condition, which increases the risk of venous thromboembolic events

* Corresponding author. Department of Neurology, Hassan II University Teaching Hospital, Sidi Harazem Road, PO Box 1835, Atlas, Fez, Morocco.

E-mail address: bouchalsiham@gmail.com (S. Bouchal).

(VTEs) especially in UC patients. This complication has been shown to be more frequent in the active phase of IBD being attributed to its prothrombotic state [1]. The incidence of VTE with IBD is 16.7% [1]. Despite this high frequency of VTE, there is still a lack of recognition of this risk among physicians.

Herein, we are presenting two cases of cerebral venous thrombosis (CVT) concurrent a relapse of UC. A review of literature was made to illustrate the high risk of CVT in relapse of UC.

Case report

Case n° 1

A 27-year-old woman with a history of ulcerative colitis since 2018 treated by 5-aminosalicylic acid with poor compliance was admitted to the gastroenterology department for abdominal pain and bloody diarrhea related to the relapse of his IBD. She received 40 mg methylprednisolone infusion per day during five days. During her hospitalization, she developed an acute headache and vomiting. She did not have a fever, seizures, or loss of vision.

On examination, the patient was fully conscious with a Glasgow coma scale of 15/15. She was afebrile, with a normal heart rate and blood pressure. Neurological examination was normal. There were no signs of meningitis. A contrast-enhanced computed tomography of the brain showed thrombosis of the left transverse and sigmoid sinus (Fig. 1). The opening pressure at lumbar puncture was 160 mmH₂O and cerebrospinal fluid analysis were normal.

The patient had microcytic hypochromic anemia with hemoglobin 10.5 g/dL with low ferritin level 10 µg/L. A renal function test, a liver function test, blood sugar, serum electrolytes, prothrombin time and activated partial thromboplastin time were normal.

She was treated with subcutaneous low molecular weight heparin (Enoxaparin 0.6 mL twice per day) during 7 days. Anticoagulation was continued with Acenocoumarol for 6 months. Prednisolone and azathioprine as disease modified therapy for UC were started.

We observed a regression of neurological and bowel symptoms after the first week of treatment without recurrence, after 6 months of follow up.

Case n° 2

A 45-year-old man has been under follow up for 2 years for an UC treated by 5-aminosalicylic acid and oral steroids. He was recently hospitalized in the gastroenterology department for relapse of UC, which was treated by 60 mg methylprednisolone infusion per day during 5 days, and azathioprine was started. Three days later, following his discharge from the hospital, he was admitted to the neurology department for two epileptic seizures with headache and aphasia.

On examination, the patient was fully conscious, afebrile, and had normal blood pressure. Neurological examination noted Wernicke aphasia without other motor or sensory deficit.

A contrast-enhanced computed tomography of the brain showed a left temporal venous infarct with thrombosis of

left transverse and sigmoid sinus (Fig. 2). The opening pressure at lumbar puncture was 140 mm H₂O and cerebrospinal fluid analysis were normal.

The patient had microcytic hypochromic anemia with hemoglobin at 9 g/dL with low serum iron. A renal function test, a liver function test, blood sugar, serum electrolytes, prothrombin time and activated partial thromboplastin time were normal.

He was treated with low molecular weight heparin infusion. Anticoagulation was continued with Acenocoumarol for 6 months.

We observed a regression of neurological symptoms after 5 months of follow-up.

Discussion

UC is a chronic relapsing IBD of unknown etiology, which frequently affects young people. It is considered a systemic disease with numerous extraintestinal complications and it has been established as an independent risk factor for developing VTE. CVT itself is a rare cerebrovascular complication of UC and it represents a serious risk of morbidity and mortality [1,2]. Incidence of CVT in IBD is estimated between 0.5 to 7.5% [3,4]. All sites of VTE during the course of UC are possible. Pulmonary embolism and deep vein thrombosis are more frequent than CVT [3,4].

The pathogenesis of CVT associated with UC is multifactorial and still poorly understood. Several factors have been reported to explain the higher risk of thrombotic events in UC than in general population. Severe inflammation during the flare of UC disease is a serious factor predisposing to thrombosis and which increases significantly the risk of VTE [4]. The cases of CVT occurring with the flare-up of CD are also described [5,6]. CVT in our cases was concomitant with an exacerbation of UC.

The hypercoagulable state created by UC is considered a major risk factor of CVT and it is of a multifactorial origin [2]. Increased D-dimer, prolonged thrombin time, hyperhomocysteinaemia or a shortened activated partial thromboplastin time, and increased platelet activation are proposed as possible explanations for prothrombotic states in UC [7–11]. These abnormalities were correlated with a parallel rise in inflammatory marker levels such as increased fibrinogen levels, C reactive protein, and tumour necrosis factor-alpha. The inflammation associated with UC could activate the system of coagulation, and then promote thrombosis. Anemia and thrombocytosis are frequent in active UC and they were also suggested as significant risk factors of CVT [7–9]. A low serum protein level caused by diarrhea and malabsorption may also cause a prothrombotic state. However, CVT can developed outside the active phase of UC [12].

In addition to the above risk factors, therapeutic procedures for UC, such as the administration of steroids, IBD-related surgery and hospitalization have been recognized as an important risk factor for VTE among IBD patients [0].

Clinical diagnosis of CVT is often difficult as it can present with a plethora of signs and symptoms, mimicking numerous neurological pathologies. The symptoms are usually non-specific and explain delayed diagnosis. Common symptoms include: headache, which is the most frequent presenting

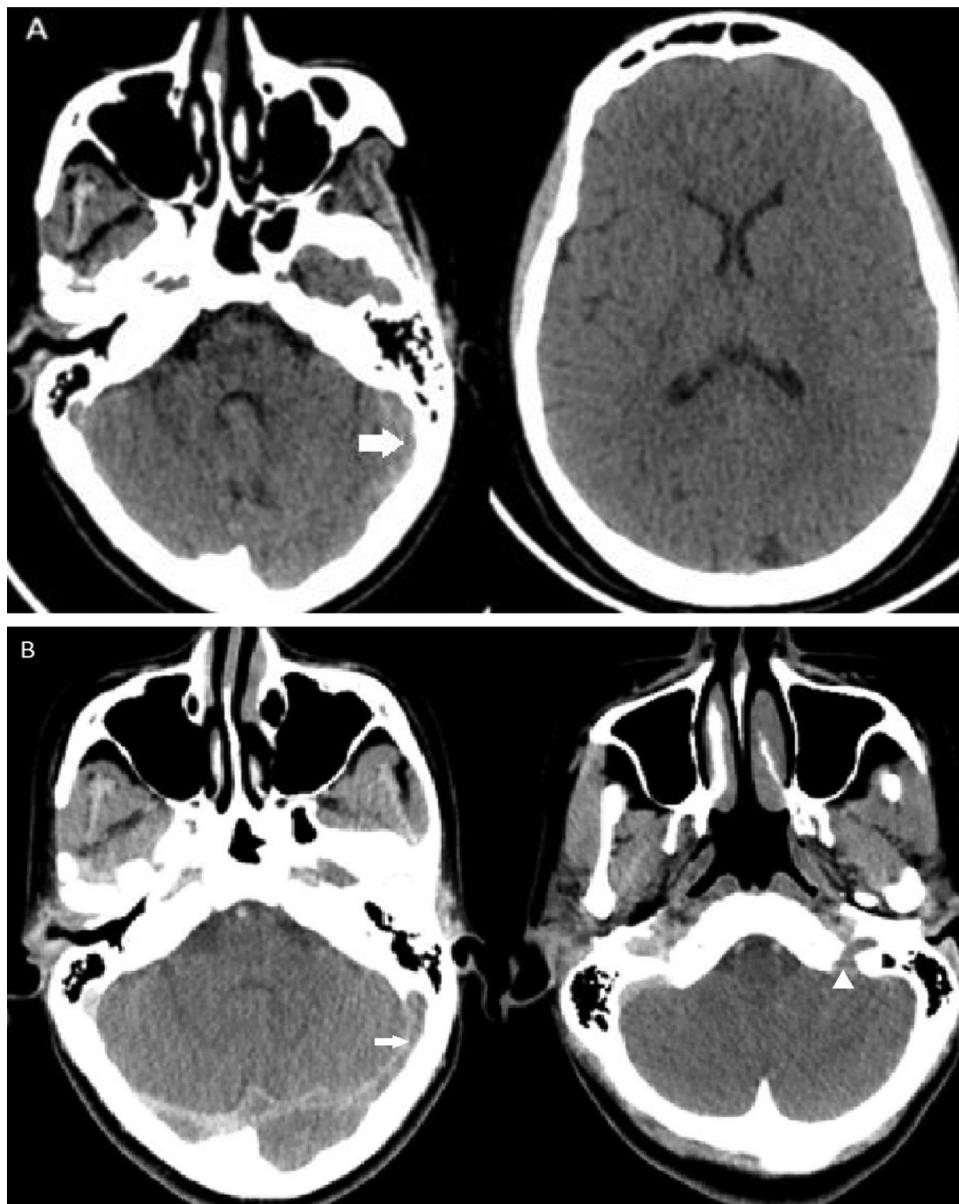


Figure 1 (A) Non-enhanced CT scan demonstrating spontaneous hyperdensity regarding left transverse sinus (white arrow). (B) Enhanced CT scan showing thrombosis of the left transverse and sigmoid sinus (white arrow) extended to the jugular vein (arrowhead).

symptom, papilledema, seizures, focal neurological deficits, and altered mental status. The clinical presentation depends on the site of the thrombosis, and on the structures involved. In some cases, CVT can reveal UC [11].

The neuroimaging plays a key role for diagnosis of CVT. There are numerous imaging techniques that can be used to confirm CVT, such as a computed tomography CT, magnetic resonance imaging (MRI), and angiography. Each one of these techniques has different advantages, and disadvantages. The primary reasons for the almost universal use of CT are the speed acquisition, availability, lower cost, relative absence of contraindications when compared to MRI. The sensitivity and specificity of CT scan are ranging from 75 to 100% [11]. CT modalities include non-contrast CT and contrast CT. CT allows to rule out other causes than CVT,

and confirmed the direct and indirect signs of CVT. Venous ischemia or hemorrhage with non-arterial distributions, parenchymal edema, and cortical grooves effacement are the indirect signs of CVT [13,14]. The non-contrast CT can also help visualize the thrombus [13–15]. Enhanced CT increases significantly the sensitivity to detect thrombosis [13–16]. CT scan confirmed the diagnosis of CVT in both of our patients.

Brain MRI is a more powerful imaging tool and more sensible than CT, but it is not available in all emergency departments. MRI may also demonstrate the direct and indirect signs of CVT. Angiography was previously considered the gold standard but its use has become very restricted [13–15].

We performed literature search for the English and French language publications from 1990 to 2020 for all adult

Table 1 Cerebral venous thrombosis complicating relapse of ulcerative colitis cases: neurologic signs, treatment and outcomes as reported in the reviewed literature.

Reference	Age (years)/Sex	Neurologic signs	Treatment	Outcome
Lee 2018 [7]	35/M	Headache and drowsiness	Heparin infusion+ warfarin + 5-aminosalicylic acid	Complete recovery
Abdalla 2019 [8]	27/M	Right-sided weakness + seizures and headache	Steroid therapy, 5-aminosalicylic acid, and infliximab Levetiracetam; heparin infusion+ Apixaban	Complete recovery
DeFillipis 2015 [9]	30/M	Unknown	LMWH	Partial resolution of symptoms
Taous A 2016 [11]	27/M	Wernicke aphasia	Heparin + intravenous pulse steroid followed by Acenocoumarol + prednisolone	Complete recovery
Deskur A 2019 [16]	25/M	Headache and nausea	LMWH + mesalazine, steroids, and azathioprine	Complete recovery
Dulger AC 2011 [17]	30/M	Headache and drowsiness	Intravenous pulse steroid + mesalazine + LMWH	Died
Fischer CM 2006 [18]	26/F	Headache which later progressed to hemiplegia and coma	Intravenous heparin + intravenous phenytoin craniectomy	Died
Zhu L 2019 [19]	31/M	Headache + nausea and vomiting,	LMWH followed by Warfarin + valproate to prevent epilepsy	Complete recovery
Kothur K 2012 [20]	31/F	Headache + weakness of right hemibody + aphasia + seizures	Urokinase + LMWH + Phenytoin + prednisolone + 5-aminosalicylic acid	Complete recovery
Tsujikawa T 2000 [21]	29/M	Convulsion, confusion, right arm numbness, right hemianopia	Heparin+ urokinase	Complete recovery
Murata S 2004 [22]	19/M	Headache	Heparin	Complete recovery
Nudelman RJ 2010 [23]	23/M	Headaches + left hemiparesis	Steroids No anticoagulation	Died
Menon B 2013 [24]	35/F	Headache +seizures	LMWH, phenytoin, intravenous dexamethasone; aspirin, sulfasalazine	Complete recovery
Cognat E 2011 [25]	25/F	Headache, left hemiparesis, drowsiness	5-aminosalicylic acid; fondaparinux followed by Oral anticoagulation (VKA)	Complete recovery
Connors LM 2018 [26]	17/F	Headache + seizures + confusion	Infliximab + Colectomy + LMWH+ Levetiracetam	Complete recovery

F: female; M: male; LMWH: low-molecular-weight heparin.

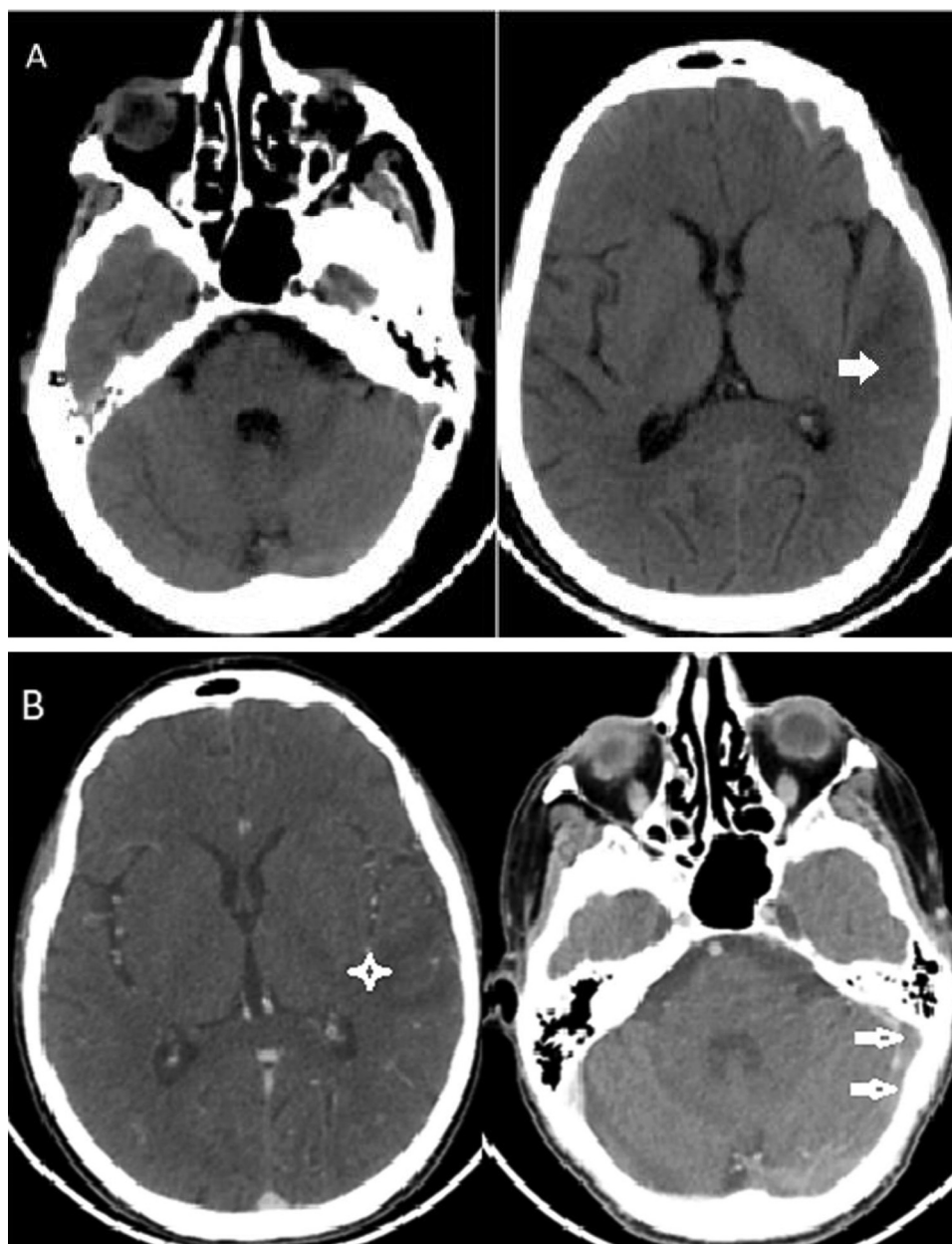


Figure 2 (A) Non enhanced cerebral CT scan showed a left temporal hypodensity. (B) Contrast-enhanced CT scan of the brain showed a left temporal venous infarct (star) with thrombosis of left transverse and sigmoid sinus (arrows).

cases of CVT caused by active UC. We found 15 cases. Clinical data and outcomes of these patients are summarized below (Table 1) [7–9,11,16–26].

Treatment of CVT with UC is similar to CVT of undetermined causes. It is recommended that patients be treated with conventional anticoagulation heparin unfractionated or low molecular-weight heparin. Using anticoagulation is not leading to increase mucosal bleeding in UC patients [21]. Oral vitamin K antagonists followed parenteral anticoagulation for 6 to 12 months [15,27]. There is little data concerning the utilization of direct oral anticoagulants in managing CVT caused by UC [5,9,15,27].

The prognosis of CVT in a UC patient seems to be more severe. It can be explained by delayed diagnosis and hesitation to start anticoagulation in patients with high

risk of digestive bleeding. The risk of mortality was mostly important in patient who are not treated by heparin [23].

To prevent VTE during active IBD, the American college of Gastroenterology and European Crohn's and colitis organization recommend a prophylactic anticoagulation for hospitalized patient especially with active disease [9,15,27].

Conclusion

UC patients, especially in the period of relapse and association with other risk factors such as anemia and medication history, present a prothrombotic state. Prevention, diagnosis, and initiation of anticoagulation in case

of thrombosis and treatment of colitis may prevent fatal complications.

Author contribution

S. Bouchal wrote the manuscript.

B. Alami helped manuscript and figure corrections and provided a critical revision of the manuscript. All authors contributed to writing this manuscript and were responsible for the final approval of the manuscript.

Disclosure of interest

The authors declare that they have no competing interest.

References

- [1] Ando K, Fujiya M, Nomura Y, Inaba Y, Sugiyama Y, Kobayashi Y, et al. The incidence and risk factors of venous thromboembolism in patients with inflammatory bowel disease: a prospective multicenter cohort study. *Digestion* 2019;100:229–37, <http://dx.doi.org/10.1159/000495289>.
- [2] Casella G, Tontini GE, Bassotti G, Pastorelli L, Villanacci V, Spina L, et al. Neurological disorders and inflammatory bowel diseases. *World J Gastroenterol* 2014;20:8764–82, <http://dx.doi.org/10.3748/wjg.v20.i27.8764>.
- [3] Mrabet S, Elleuch N, Slama AB, Jaziri H, Hammami A, Braham A, et al. Thromboembolic events in inflammatory bowel disease. *J Med Vasc* 2020;45:67–71, <http://dx.doi.org/10.1016/j.jdmv.2020.01.148>.
- [4] Kohoutova D, Moravkova P, Kruzliak P, Bures J. Thromboembolic complications in inflammatory bowel disease. *J Thromb Thrombolysis* 2015;39:489–98.
- [5] Cho YH, Chae MK, Cha JM, Lee JI, Joo KR, Shin HP, et al. Cerebral venous thrombosis in a patient with Crohn's disease. *Intest Res* 2016;14:96–101.
- [6] Kim I, Min KH, Yeo M, Kim JS, Lee SH, Lee SS, et al. Unusual case of cerebral venous thrombosis in patient with Crohn's disease. *Case Rep Neurol* 2015;7:115–20.
- [7] Lee J, Hwang SW, Lee J, Jung KH, Kim HI, Park SH, et al. A case of ulcerative colitis presenting with cerebral venous thrombosis. *Int Res* 2018;16:306–11, <http://dx.doi.org/10.5217/ir.2018.16.2.306>.
- [8] Abdalla AO, Alluri D, Hassaballa M, Calvo L, Otaki F. A case of cerebral venous sinus thrombosis presenting during relapse of ulcerative colitis. *Am J Case Rep* 2019;20:419–22, <http://dx.doi.org/10.12659/AJCR.913429>.
- [9] DeFillipis EM, Barfield E, Leifer D, Steinlauf A, Bosworth BP, Scherl EJ, et al. Cerebral venous thrombosis in inflammatory bowel disease. *J Dig Dis* 2015;16:104–8.
- [10] Kaplan GG, Lim A, Seow CH, Moran GW, Ghosh S, Leung Y, et al. Colectomy is a risk factor for venous thromboembolism in ulcerative colitis. *World J Gastroenterol* 2015;21:1251–60, <http://dx.doi.org/10.3748/wjg.v21.i4.1251>.
- [11] Taous A, Berri MA, Lamsiah T, Zainoun B, Ziadi T, Rouimi A. Cerebral venous thrombosis revealing an ulcerative colitis. *Pan Afr Med J* 2016;23:120, <http://dx.doi.org/10.11604/pamj.2016.23.120.9186>.
- [12] Meher LK, Dalai SP, Panda S, Hui PK, Nayak S. Unusual case of cerebral venous sinus thrombosis in patient with ulcerative colitis in remission. *J Clin Diagn Res* 2016;10:OD35–6, <http://dx.doi.org/10.7860/JCDR/2016/20105.7883>.
- [13] Ghoneim A, Straiton J, Pollard C, MacDonald K, Jampana R. Imaging of cerebral venous thrombosis. *Clin Radiol* 2020;75:254–64, <http://dx.doi.org/10.1016/j.crad.2019.12.009>.
- [14] Alami B, Boujraf S, Quenum L, Oudrhiri A, Alaoui Lamrani MY, Haloua M, et al. La thrombose veineuse cérébrale : aspects clinico-radiologiques, à propos d'une série de 62 cas. *J Med Vasc* 2019;44:387–99.
- [15] Kaddourah O, Numan L, Jeepalyam S, Abughanimeh O, Ghanimeh MA, Abuamr K. Venous thromboembolism prophylaxis in inflammatory bowel disease flare-ups. *Ann Gastroenterol* 2019;32:578–83, <http://dx.doi.org/10.20524/aog.2019.0412>.
- [16] Deskur A, Zawada I, Błogowski W, Starzyńska T. Cerebral venous sinus thrombosis in a young patient with ulcerative colitis: A case report. *Medicine (Baltimore)* 2019;98:e17428, <http://dx.doi.org/10.1097/MD.00000000000017428>.
- [17] Dulger AC, Begenik H, Demirtas L, Esen R, Emre H. A flare of ulcerative colitis accompanied with cerebral sinus venous thrombosis and bilateral thalamic infarctus: a case report. *Gastroenterology Res* 2012;5:67–70, <http://dx.doi.org/10.4021/gr403w>.
- [18] Fischer CM, Smith JL, Sanchez LD. Headache in a patient with ulcerative colitis. *Intern Emerg Med* 2006;1:155–9, <http://dx.doi.org/10.1007/BF02936545>.
- [19] Zhu L, Cheng J, Gu P, Liu Y, Liu J, Wang J, et al. Therapeutic strategies of thromboembolic events in patients with inflammatory bowel diseases: two case reports. *Medicine (Baltimore)* 2019;98:e14622, <http://dx.doi.org/10.1097/MD.00000000000014622>.
- [20] Kothur K, Kaul S, Rammurthi S, Srinivasarao Bandaru VCS, Suryaprabha SAT, Rukmini Mrudula K. Use of thrombolytic therapy in cerebral venous sinus thrombosis with ulcerative Colitis. *Ann Indian Acad Neurol* 2012;15:35–8.
- [21] Tsujikawa T, Urabe M, Bamba H, Andoh A, Sasaki M, Koyama S, et al. Haemorrhagic cerebral sinus thrombosis associated with ulcerative colitis: a case report of successful treatment by anti-coagulant therapy. *J Gastroenterol Hepatol* 2000;15:688–92, <http://dx.doi.org/10.1046/j.1440-1746.2000.02190.x>.
- [22] Murata S, Ishikawa N, Oshikawa S, Yamaga J, Ootsuka M, Date H, et al. Cerebral sinus thrombosis associated with severe active ulcerative colitis. *Intern Med* 2004;43:400–3, <http://dx.doi.org/10.2169/internalmedicine.43.400>.
- [23] Nudelman RJ, Rosen DG, Rouah E, Verstovsek G. Cerebral sinus thrombosis: a fatal neurological complication of ulcerative colitis. *Patholog Res Int* 2010;2010:132754, <http://dx.doi.org/10.4061/2010/132754>.
- [24] Menon B, Goyal R, Nihal R, Reddy R. Cerebral venous thrombosis in ulcerative colitis. *J Neurosci Rural Pract* 2013;4:84–6, <http://dx.doi.org/10.4103/0976-3147.105629>.
- [25] Cognat E, Crassard I, Denier C, Vahedi K, Bousser MG. Cerebral venous thrombosis in inflammatory bowel diseases: eight cases and literature review. *Int J Stroke* 2011;6:487–92, <http://dx.doi.org/10.1111/j.1747-4949.2011.00620.x>.
- [26] Conners LM, Ahad R, Janda PH, Mudasir Z. Cerebral venous sinus thrombosis in a patient with ulcerative colitis flare. *Case Rep Neurol Med* 2018;2018:5798983, <http://dx.doi.org/10.1155/2018/5798983> [eCollection 2018].
- [27] Ferro JM, Bousser MG, Canhão P, Coutinho JM, Crassard I, Dentali F, et al. European Stroke Organization. European Stroke Organization guideline for the diagnosis and treatment of cerebral venous thrombosis - endorsed by the European Academy of Neurology. *Eur J Neurol* 2017;24:1203–13, <http://dx.doi.org/10.1111/ene.13381>.