

Ipsilateral Vocal Cord Paralysis after Acute Anterior Ischemic Stroke

Omar Hussein MD; Khalid Swalha MD; Ahmed Abd Elazim MD; Omar Hussein MD; Michel Torbey MD

Introduction

Vocal cords are innervated by the recurrent laryngeal nerve and superior laryngeal nerve which are branches of the vagus nerve. The nucleus ambiguous is the motor nucleus of the vagus nerve and it is located in the medulla. It receives stimuli from the bilateral hemispheres through the corticobulbar tracts. Thus, unilateral cerebral lesions above the level of nucleus ambiguous is unlikely to cause paralysis of the vocal cord.

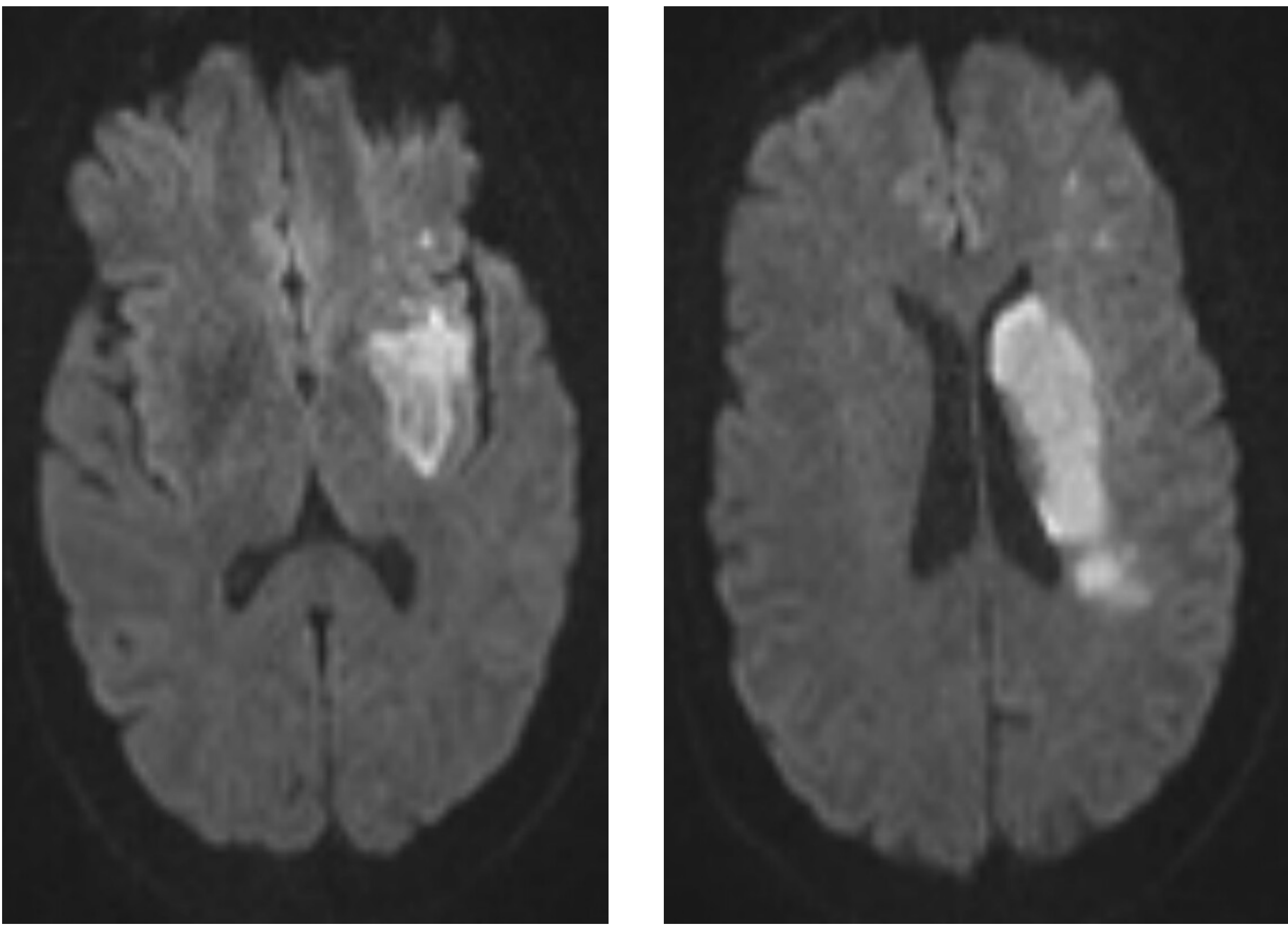
Case

We present a sixty-two-year-old female patient with past history significant for hypertension who presented with acute right-sided weakness and aphasia. CT-head was unremarkable but she was outside the window for thrombolytic-therapy. MRI-brain diffusion scan showed partial middle cerebral artery ischemic stroke while the CT-angiogram of the head and neck showed complete extracranial and intracranial left internal carotid artery occlusion. CT-perfusion showed large penumbra. The patient partially improved after induced hypertensive therapy. She was able to pronounce few words; however, her voice was hypophonic. The otolaryngology team was consulted for vocal-cords evaluation.

Results

Pre induced hypertension CTP showed left cerebral hemisphere large penumbra with significant size core infarction. The patient underwent flexible fiberoptic laryngoscopy which showed a paralyzed left vocal cord. The post induced hypertension CTP showed remarkable resolution of the ischemia. 2 months outpatient follow up flexible fiberoptic laryngoscopy showed improved vocal cord paralysis.

MRI - DWI



Discussion

In literature, there is a reported case of unilateral stroke, in the operculum and insula with bilateral vocal cord paralysis. There is another report of cerebral ICH and transient ipsilateral vocal cord paralysis. Regarding the first case, there is no clear anatomical explanation of how unilateral brain lesion cause bilateral vocal cord paralysis unless this is a coincidental finding and likely related to viral infection. As for the second case, it was reported that the patient's dysphonia has completely resolved in one week thus it was attributed to resolved brain edema around the hematoma at the area of the operculum and insula. We believe that this explanation is likely incorrect because of the less likelihood of the edema to resolve by itself without treatment in that early stage and the authors didn't provide evidence of antiedematous treatment given or any imaging proving the resolution of the edema. Unlike these two cases, our case provides a clear resolution of the cerebral ischemia after aggressive induced hypertensive therapy. We also provided an imaging evidence of resolution of such ischemia correlating with patient's induced ischemia.

Conclusion

Our case is a rare case of transient unilateral vocal cord paralysis associated with ipsilateral cerebral ischemia. The paralysis resolved with resolution of ischemia.

Our case highlights the possible different anatomical variants in cortical control of the vocal cords. Of these, the most common is bilateral control of each vocal cords. Less commonly, contralateral control has been described in the literature.

Our case represents evidence of ipsilateral control that is considered extremely rare.

References

1- Nasrat T et al. Bilateral Vocal Cord Paralysis with Acute Ischemic Stroke.
2- Park O et al. Transient Vocal Cord Paralysis after a Supratentorial Intracerebral Hemorrhage.
3- Toutounchi SJ, Eydi M, Golzari SE, Ghaffari MR, Parvizian N. Vocal cord paralysis and its etiologies.

CT Perfusion – Pre and Post Treatment

