

Cardioembolic Stroke From Atrial Septal Aneurysm

Giuseppe Di Pasquale, MD, Alvaro Andreoli, MD, Paola Grazi, MD,
Paola Dominici, MD, and Giuseppe Pinelli, MD

Atrial septal aneurysm is an uncommon occult cardiac source of cerebral embolism. It is usually asymptomatic, and clinical cardiologic examination and electrocardiography fail to reveal its presence. We report a case of a 34-year-old woman with sudden right hemiplegia and aphasia from occlusion of the left carotid siphon in whom an atrial septal aneurysm was detected by two-dimensional echocardiography. The absence of atherosclerotic risk factors and vascular lesions proximal to the carotid occlusion strengthened a causal relation between atrial septal aneurysm and cerebral infarction. Consequently, two-dimensional echocardiography may be advisable in every patient with unexplained ischemic stroke to detect possible occult embolic cardiac abnormalities. (*Stroke* 1988;19:640-643)

Atrial septal aneurysm is an uncommon localized malformation of the interatrial septum, which protrudes into the right or left atrium or both. This lesion is mainly associated with congenital or acquired heart disease and is rarely present as an isolated lesion.¹⁻⁶ Atrial septal aneurysm is occasionally recognized in asymptomatic subjects. Serious complications such as embolic phenomena may, however, occur.^{3,7-13} About 230 cases of atrial septal aneurysm have been reported so far, but only a few cases have been described in association with cerebral embolism.

We report the case of a young woman with carotid ischemia, in whom the aneurysm was detected by echocardiography. This patient was identified in a prospective study of 350 consecutive patients with cerebral ischemia submitted to two-dimensional echocardiography in our institution between 1982 and 1986.

Case Report

A 34-year-old right-handed woman was admitted 4 hours after abrupt occurrence of right hemiplegia and aphasia. Her medical history was unremarkable; no risk factors for atherosclerosis were present. Cardiac physical examination and electrocardiogram (ECG) were normal; blood pressure was 130/80 mm Hg. Chest x-ray was normal. Computed tomography of the brain was normal on admission but revealed a left fronto-temporal low-density area on the second day (Figure 1). Left carotid angiography, performed on admission, showed occlusion of the carotid siphon in the absence of atherosclerotic lesions proximal to the occlusion (Figure 2). Two-dimensional echocardiography (ATL

MK 300 IC, phased-array sector scanner) performed in the apical four-chamber and subcostal views showed abnormal systolic bulging of the midportion of the interatrial septum. The motion of the aneurysm from the left into the right atrium occurred during mid- and end-systole of the cardiac cycle. The aneurysmal dilatation protruded about 1.5 cm beyond the plane of the interatrial septum. No other echocardiographic abnormalities were noted (Figure 3). Laboratory investigations, including blood rheology, coagulation tests, and antibodies for lupus, were normal. Twenty-four-hour Holter monitoring did not reveal cardiac arrhythmias.

Since a causal relation between stroke and atrial septal aneurysm was deemed very likely, anticoagulant treatment with warfarin was started. After 7 months' follow-up the patient is moderately disabled. No recurrence of systemic embolism has occurred.

Discussion

Cardiac embolic lesions account for about 15% of ischemic strokes in clinical stroke registries.¹⁴ Medical history, physical examination, and ECG permit us to recognize most embolic cardiac abnormalities so routine echocardiography in unselected patients with cerebral ischemia is probably unnecessary.¹⁵

Atrial septal aneurysm is a striking example of an occult embolic cardiac source of cerebral ischemia. The aneurysm, when it occurs in isolation, is not in fact associated with abnormalities of either physical examination or ECG.¹⁶ Also, in our experience, this lesion turned out to be an unexpected echocardiographic finding.

The embolic potential of atrial septal aneurysm has been claimed by several authors reporting systemic or pulmonary embolism.^{3,7-13} Anatomic findings support such a clinical assumption; Silver and Dorsey¹ documented the presence of a thrombus at the base of an aneurysm at autopsy, and Grosogoeat et al⁷ described the histologic appearance of a partly organized thrombus in a resected aneurysm. Another cause of systemic

From the Service of Cardiology (G.D.P., P.G., P.D., G.P.) and First Division of Neurosurgery (A.A.), Bellaria Hospital, Bologna, Italy.

Supported by CRS Research Grant 336/85 from Regione Emilia - Romagna, Italy.

Address for correspondence: Giuseppe Di Pasquale, MD, Servizio di Cardiologia, Ospedale Bellaria, Via Altura, 3, 40139 Bologna, Italy.

Received June 4, 1987; accepted December 2, 1987.

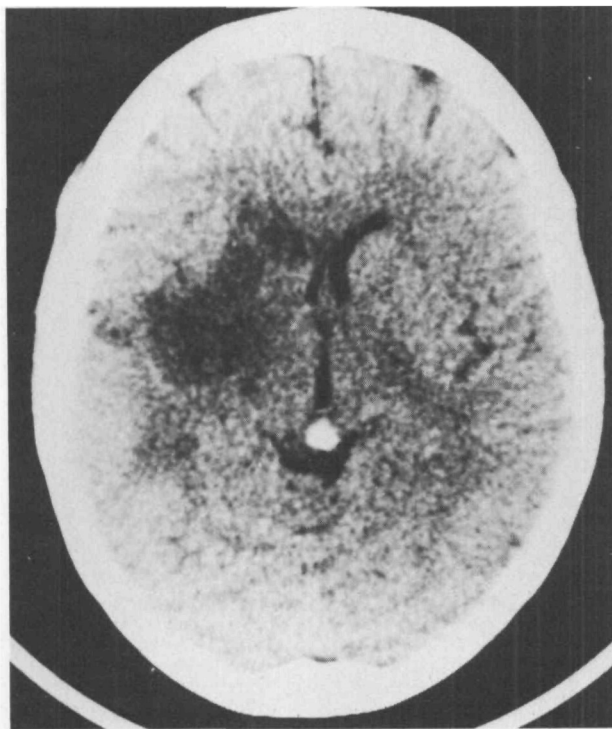


FIGURE 1. Unenhanced computed tomogram performed 2 days after onset of symptoms, revealing left frontoparietal infarction with moderate shift of midline structures to right.

embolism might be paroxysmal supraventricular arrhythmias, which have been observed in patients with atrial septal aneurysm.^{4,17}

A causal relation between atrial septal aneurysm and stroke in our case is supported by clinical and radiographic findings. The clinical features that suggest embolization include abrupt onset of maximal neurologic deficit in a young active woman without atherosclerotic risk factors. The angiographic features that reinforce the diagnosis of cardiogenic embolism are the occlusion of the internal carotid artery in the siphon in the absence of atherosclerotic lesions proximal to the occlusion.

The association of atrial septal aneurysm with cerebral ischemia has been rarely reported in the literature, and a causal relation cannot be assumed with certainty in every case. Between 1973 and 1986, 13 cases of atrial septal aneurysm associated with cerebral ischemia have been described (Table 1).^{7,9-13} However, in only five cases was a causal relation between that cardiac lesion and cerebral ischemia strongly suggested.^{7,9-11}

The diagnosis of atrial septal aneurysm has been made occasionally in the past as an unexpected finding at necropsy.^{1,18,19} Angiocardiography, an invasive technique, is obviously not practical as a routine examination for the detection of the aneurysm. Furthermore, angiocardiography does not allow direct visualization of the interatrial septum but shows a filling defect that may be mistaken for an intra-atrial tumor or thrombus.^{3,20,21} Intravenous digital subtraction angiography⁹ and nuclear imaging¹² have been recently employed for the visualization of atrial septal aneurysm. However, two-dimensional echocardiography is the most useful diagnostic examination for the detection of this lesion.^{4,10-12,22-24} The reliability of this

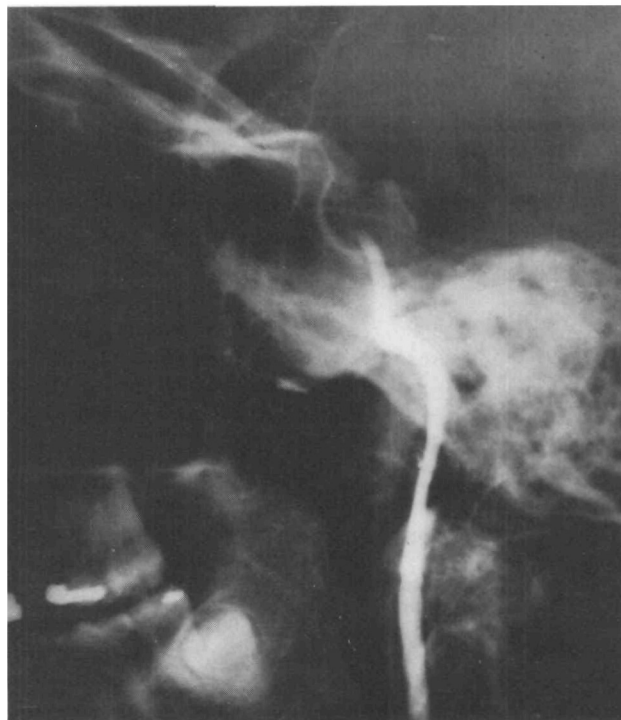
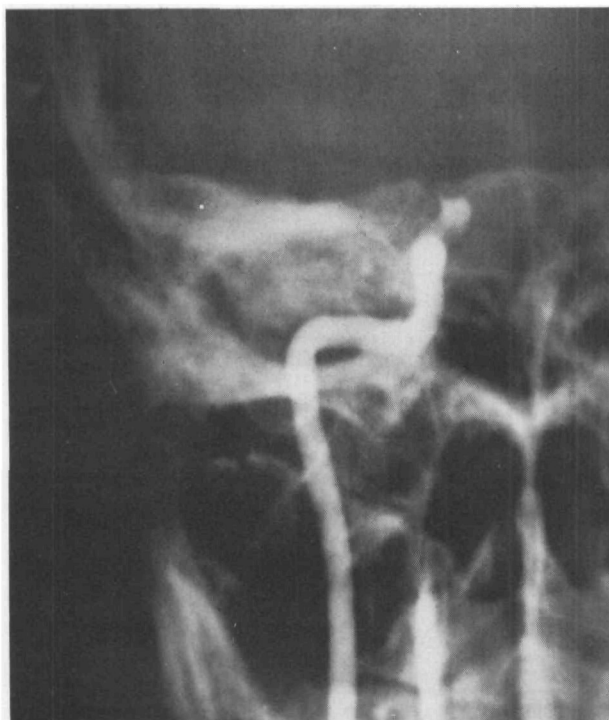
FIGURE 2. Left carotid angiogram in anteroposterior (left) and lateral (right) views showing occlusion of internal carotid artery at siphon level.

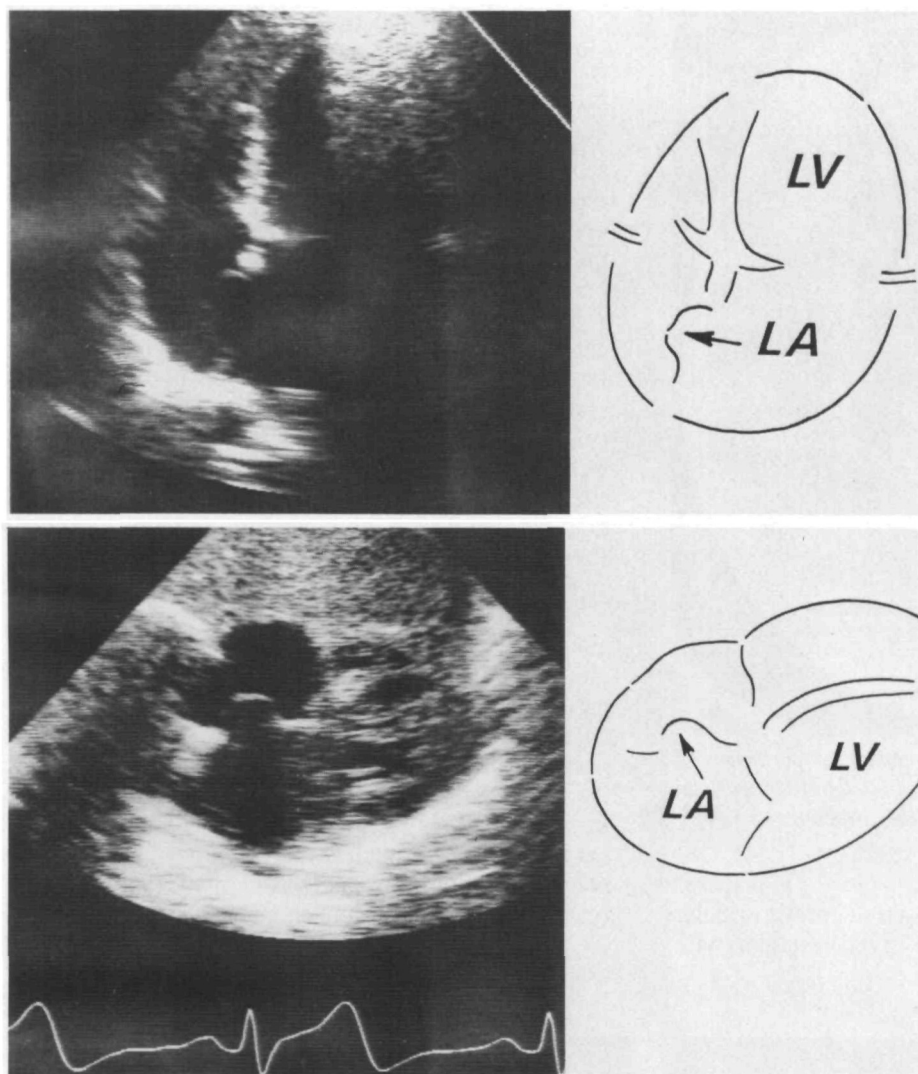


FIGURE 3. Two-dimensional echocardiogram in apical four-chamber (top) and subcostal (bottom) views showing aneurysmal systolic bulging of middle portion of interatrial septum into right atrium.

TABLE 1. Reported Cases of Atrial Septal Aneurysm Associated With Cerebral Ischemia

Authors	Age/sex	Diagnostic detection	Neurologic features	Cerebral angiography	Computed tomography	Therapy
Grogogeat et al ⁷	33/F	AGC	L hemiplegia	R ICA occlusion	—	Anticoagulant
	39/M	AGC	R hemiplegia	Normal	—	Cardiac surgery
Yiannikas et al ⁹	68/F	DSA/2D echo	R hemiplegia	—	—	—
Canny et al ¹⁰	53/F	AGC	L hemiplegia	R MCA occlusion	—	Cardiac surgery
Gallet et al ¹¹	61/F	2D echo/AGC	R hemiplegia	Normal*	Ischemic frontoparietal infarct	Anticoagulant
Hanley et al ¹²	64/F	2D echo/NS	CVA (SH)	—	—	Cardiac surgery
	56/M	2D echo	TIA (SH)	—	—	—
	68/F	2D echo	CVA	—	—	—
Belkin et al ¹³	75/F	2D echo	CVA	Normal in 1, not performed in 3	Ischemia in 3, not performed in 1	—
	69/F	2D echo	CVA			
	71/F	2D echo	CVA			
	68F	2D echo	CVA			
	59/F	2D echo	TIA	—	Normal	—
Present report	34/F	2D echo	R hemiplegia	L ICA occlusion	Ischemic frontoparietal infarct	Anticoagulant

F, female; M, male; AGC, angiocardiology; DSA, digital subtraction angiocardiology; 2D echo, two-dimensional echocardiography; NS, nuclear scan; L, left; R, right; CVA, cerebrovascular accident; SH, systemic hypertension; TIA, transient ischemic attack; ICA, internal carotid artery; MCA, middle cerebral artery.

*Venous digital subtraction angiography of cervical vessels only.

noninvasive technique is higher than that of angiography, and two-dimensional echocardiography should therefore be considered the gold standard technique for the diagnosis of atrial septal aneurysm.

The detection of atrial septal aneurysm in a patient with cerebral ischemia in the absence of atherosclerotic cerebrovascular disease is important for possible therapeutic implications. Anticoagulant treatment has been employed by us and other authors.^{7,11} Surgical repair has been preferred by some others to avoid the need for long-term anticoagulation.^{7,10,12}

In conclusion, atrial septal aneurysm should be taken into account as a rare occult cardiac source of cerebral embolism. Atrial septal aneurysm is usually asymptomatic, and clinical cardiologic examination and ECG fail to reveal its presence. Our observation therefore suggests the need to perform two-dimensional echocardiography in every patient with unexplained cerebral ischemia to detect possible occult cardiac abnormalities.

Acknowledgments

We thank Professor Giovanni Ruggiero, Chief of the Service of Neuroradiology, for computed tomography and angiography studies. We are also grateful to Giuseppe Lanzino for his assistance in the preparation of the manuscript and to Giuseppe Stefanelli for typing the manuscript.

References

- Silver MD, Dorsey JS: Aneurysms of the septum primum in adults. *Arch Pathol Lab Med* 1978;102:62-65
- Lazar AV, Pechacek LW, Mihalick MJ, De Castro CM, Hall RJ: Aneurysm of the interatrial septum occurring as an isolated anomaly. *Cathet Cardiovasc Diagn* 1983;9:167-173
- Thompson JJ, Phillips LA, Melmon KL: Pseudotumor of the right atrium. Report of a case and review of its etiology. *Ann Intern Med* 1966;64:665-667
- Hauser AM, Timmis GC, Stewart JR, Ramos RR, Gangadharan V, Westveer DC, Gordon S: Aneurysm of the atrial septum as diagnosed by echocardiography: Analysis of 11 patients. *Am J Cardiol* 1984;53:1401-1402
- Alexander MD, Bloom KR, Hart P, D'Silva F, Murgu JP: Atrial septal aneurysm: A cause for midsystolic click. *Circulation* 1981;63:1186-1188
- Wysham DG, McPherson DD, Kerber RE: Asymptomatic aneurysm of the interatrial septum. *J Am Coll Cardiol* 1984;4:1311-1314
- Grosogoeat Y, Lhermitte F, Carpentier A, Facquet J, Alhomme P, Tran TX: Anéurysme de la cloison interauriculaire révélé par une embolie cérébrale. *Arch Mal Coeur* 1973;66:169-177
- Guarino L, Baudouy M, Camous JP, Patouraux G, Varenne A, Guiran JB: Anéurysme de la cloison interauriculaire par hernie de la valvule de Vieussens et suspicion d'embolie coronaire. *Arch Mal Coeur* 1979;72:1390-1394
- Yiannikas J, Moodie DS, Sterba R, Gill CC: Intravenous digital subtraction angiography to assess aneurysms of the ventricular and atrial septum pre- and postoperatively. *Am J Cardiol* 1984;53:383-385
- Canny M, Drobinski G, Thomas D, Gautier JC, Awada A, Leclerc JP, Gong L, Chan-Woon-Ming M, Gandjbakhch I: Anéurysme de la cloison interauriculaire. Diagnostic échocardiographique. *Arch Mal Coeur* 1984;77:337-342
- Gallet B, Malergue MC, Adams C, Saudemont JP, Collot AMC, Druon MC, Hiitgen M: Atrial septal aneurysm: A potential cause of systemic embolism. *Br Heart J* 1985;53:292-297
- Hanley PC, Tajik AJ, Hynes JK, Edwards WD, Reeder GS, Hagler DJ, Seward JB: Diagnosis and classification of atrial septal aneurysm by two-dimensional echocardiography: Report of 80 consecutive cases. *J Am Coll Cardiol* 1985;6:1370-1382
- Belkin RN, Waugh RA, Kisslo J: Interatrial shunting in atrial septal aneurysm. *Am J Cardiol* 1986;57:310-312
- Cerebral Embolism Task Force: Cardiogenic brain embolism. *Arch Neurol* 1986;43:71-84
- Knopman DS, Anderson DC, Asinger RW, Greenland P, Mikell F, Good DC: Indications for echocardiography in patients with ischemic stroke. *Neurology* 1982;32:1005-1011
- Longhini C, Brunazzi MC, Musacci GF, Caneva M, Bandello A, Bolomini L, Barbiero M, Toselli T, Barbaresi F: Atrial septal aneurysm: Echopoliographic study. *Am J Cardiol* 1985;56:653-656
- Ong LS, Nanda NC, Falkoff MD, Barold SS: Interatrial septal aneurysm, systolic click and atrial tachyarrhythmia. A new syndrome? *Ultrasound Med Biol* 1982;8:691-693
- Lev M: *Autopsy Diagnosis of Congenitally Malformed Hearts*. Springfield, Ill, Charles C Thomas, 1953, pp 22-23
- Topaz O, Feigl A, Edwards JE: Aneurysm of the fossa ovalis in infants: A pathologic study. *Pediatr Cardiol* 1985;6:65-69
- Gerard R, Baille Y, Luccioni R, Gatan-Pelachon J, Dupont A: Anéurysme du septum interauriculaire et valvulopathie mitrale. *Coeur* 1979;10:579-586
- Latour H, Negre E, Chaptal PA, Bordat JC: Pseudotumeur de l'oreillette droite par hernie de la valvule de Vieussens. *Arch Mal Coeur* 1978;71:207-210
- Gondi B, Nanda NC: Two-dimensional echocardiographic features of atrial septal aneurysm. *Circulation* 1981;63:452-457
- Iliceto S, Papa A, Sorino M, Rizzon P: Combined atrial septal aneurysm and mitral valve prolapse: Detection by two-dimensional echocardiography. *Am J Cardiol* 1984;54:1151-1153
- Dewilde J, Bellorini M, Signoret P, Vahanian A, Bourroux A, Cachera JP, Acar J, Gamerman J: Anéurysme de septum interauriculaire avec shunt gauche-droite opéré: Aspect échocardiographique. *Arch Mal Coeur* 1983;74:113-118

KEY WORDS • aneurysm • cardiovascular diseases • carotid artery diseases • echocardiography

Cardioembolic stroke from atrial septal aneurysm.
G Di Pasquale, A Andreoli, P Grazi, P Dominici and G Pinelli

Stroke. 1988;19:640-643

doi: 10.1161/01.STR.19.5.640

Stroke is published by the American Heart Association, 7272 Greenville Avenue, Dallas, TX 75231

Copyright © 1988 American Heart Association, Inc. All rights reserved.

Print ISSN: 0039-2499. Online ISSN: 1524-4628

The online version of this article, along with updated information and services, is located on the
World Wide Web at:

<http://stroke.ahajournals.org/content/19/5/640>

Permissions: Requests for permissions to reproduce figures, tables, or portions of articles originally published in *Stroke* can be obtained via RightsLink, a service of the Copyright Clearance Center, not the Editorial Office. Once the online version of the published article for which permission is being requested is located, click Request Permissions in the middle column of the Web page under Services. Further information about this process is available in the [Permissions and Rights Question and Answer](#) document.

Reprints: Information about reprints can be found online at:
<http://www.lww.com/reprints>

Subscriptions: Information about subscribing to *Stroke* is online at:
<http://stroke.ahajournals.org/subscriptions/>