

[CASE REPORT]

Macrosquare-wave Jerks Subsiding after Hydrocephalus Treatment in a Thalamic Hemorrhage Patient

Kanta Tanaka¹, Daisuke Ando², Kenichi Irie^{2,3}, Masafumi Ihara³ and Masatoshi Koga²

Abstract:

A 54-year-old man suddenly developed impaired consciousness and left hemiplegia due to a right thalamic hematoma. Emergent ventricular drainage for acute hydrocephalus improved the level of consciousness, but macrosquare-wave jerks (MSWJ) consisting of a right-ward intrusive saccade and corrective saccade appeared. The MSWJ disappeared on day 2 when follow-up CT revealed improvement of hydrocephalus. However, on day 36, after ventricular drainage was clamped, the MSWJ reappeared. After ventriculoperitoneal shunt, MSWJ again subsided. In this patient, hydrocephalus may have stretched the superior colliculus, thereby decreasing activity of the fixation neurons and then omnipause neurons, and eventually resulting in the reversible MSWJ.

Key words: intracerebral hemorrhage, hydrocephalus, macrosquare-wave jerks, superior colliculus, thalamus

(Intern Med 60: 2487-2490, 2021)

(DOI: 10.2169/internalmedicine.6293-20)

Introduction

Macrosquare-wave jerks (MSWJ) are rare, but have been reported in multiple sclerosis and multiple system atrophy (1). We present the case of a patient with thalamic hemorrhage in whom MSWJ reproducibly disappeared after treatment of hydrocephalus.

Case Report

A 54-year-old, right-handed man suddenly developed impaired consciousness and left hemiplegia. Glasgow Coma Scale (GCS) score was 7 (E1V2M4). He showed right-ward conjugate eye deviation that could be overcome with oculocephalic stimulation. The patient did not show anisocoria, and pupillary light reflex was prompt on both sides. CT revealed a right thalamic hematoma measuring 3.3×2.0 cm (estimated volume, 8.3 mL) with mesencephalic and intraventricular extension. Because acute hydrocephalus was evident, emergent ventricular drainage was performed. Level of consciousness was improved the next day, with a GCS score of 13 (E3V4M6). However, the presence of horizontal sac-

cadic eye movements was noted. The eye movement consisted of conjugate saccades that took the eyes away from the fixation point toward the right and then returned them. These saccadic movements could not be voluntarily suppressed by the patient. With eyes closed, these movements were not observed through the eyelid. Skew deviation was noted with hyperdeviation of the right eye without apparent gaze palsies. The patient did not report oscillopsia. CT showed that hydrocephalus was still apparent, but hematoma had not expanded (Fig. 1A).

To elucidate details of the rhythm pattern for horizontal saccades, video of the eye movements was analyzed using motion analysis software (Kinovea, version 0.8.15; <http://www.kinovea.org>) (2). This analysis revealed that eye oscillations occurred at a frequency of 2-3 Hz and that after taking the eyes off the fixation point, return occurred with a median latency of 200 ms (range, 133-267 ms). The amplitude of horizontal saccades was estimated as >5° (Fig. 1B). The eye movements were classified as MSWJ. On day 2 after onset, the abnormal saccades disappeared and follow-up CT revealed improvement of hydrocephalus (Fig. 1C).

On day 36, after ventricular drainage was clamped, the MSWJ reappeared without any apparent disturbance of con-

¹Division of Stroke Care Unit, National Cerebral and Cardiovascular Center, Japan, ²Department of Cerebrovascular Medicine, National Cerebral and Cardiovascular Center, Japan and ³Department of Neurology, National Cerebral and Cardiovascular Center, Japan

Received: September 13, 2020; Accepted: January 14, 2021; Advance Publication by J-STAGE: March 1, 2021

Correspondence to Dr. Kanta Tanaka, tanaka19830311kanta@gmail.com

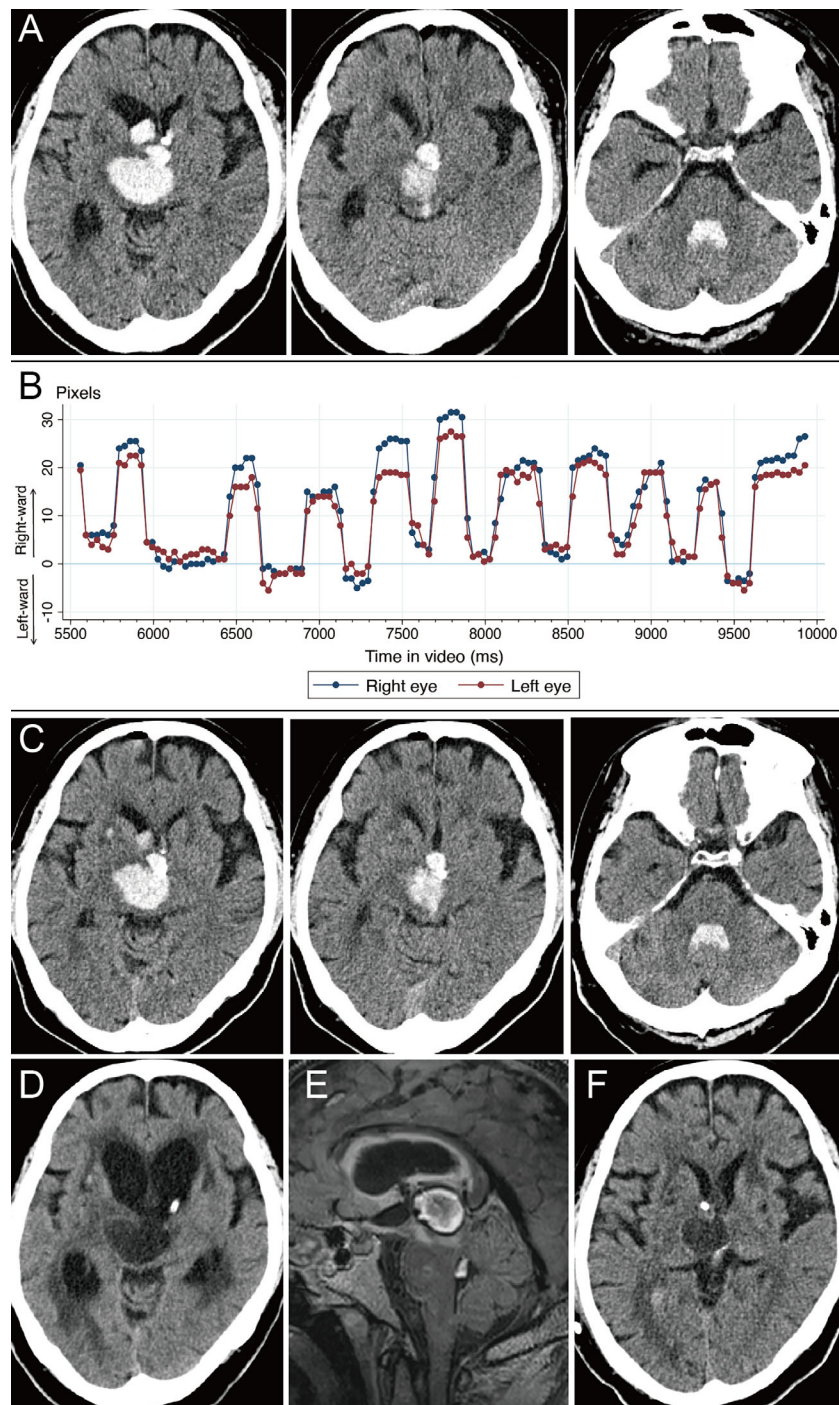


Figure 1. (A) CT on day 1 after ventricular drainage. Hydrocephalus is still evident. The fourth ventricle is filled with hematoma, but there is no hematoma extension into the cerebellar parenchyma. (B) A plot of eye movements observed on day 1, demonstrating conjugate eye oscillations consisting of a right-ward intrusive saccade and corrective saccade. To generate this plot, we analyzed video (MP4 format) at 30 frames per second using freeware motion analysis software (Kinovea). In the analysis, the center of the pupil was tracked in every frame and distances from the initial fixation point were recorded. Eye movement of 20 pixels corresponds with an amplitude of approximately 5° , according to a trigonometric calculation based on the size of the eye ball on CT. Corrective saccades seem inaccurate, which may be due to hand movements during video recording or rotatory movements of the patient's head. (C) CT on day 2 with improved hydrocephalus. (D) After clamping the drainage, hydrocephalus exacerbated. (E) Three-dimensional fluid-attenuated inversion recovery imaging on day 36 shows the presence of subacute clots in the third and fourth ventricles. (F) Cerebral CT on day 40 shows improved hydrocephalus.

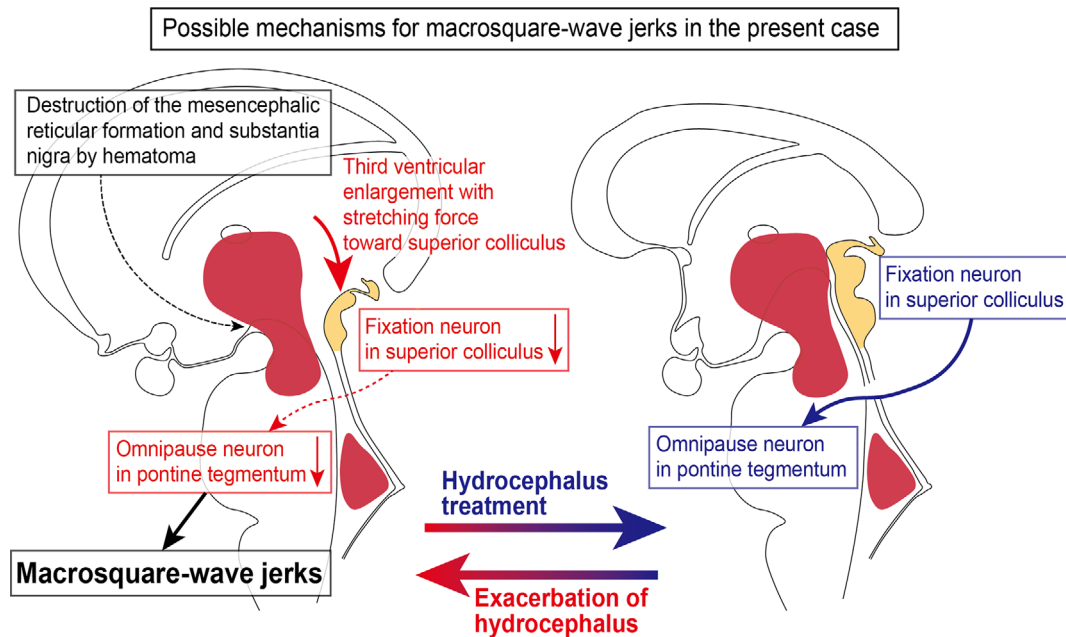


Figure 2. A schematic illustration for possible mechanisms of reversible macrosquare-wave jerks in the present case.

sciousness. CT revealed exacerbation of hydrocephalus (Fig. 1D). MRI showed late subacute clots in the third and fourth ventricles (Fig. 1E). A ventriculoperitoneal shunt was placed on day 37 and MSWJ again disappeared on day 39. Follow-up CT showed improvement of hydrocephalus (Fig. 1F). At 6 months after onset, the modified Rankin Scale score was 4 and no recurrence of hydrocephalus or MSWJ was evident.

Discussion

Square-wave jerks are on the spectrum of saccadic intrusions and consist of: 1) a conjugate saccade away from the fixation point; 2) maintenance of the eccentric eye position for approximately 200 ms; and 3) return saccade back to the initial position. Square-wave jerks with a large-amplitude saccade typically $>5^\circ$ are called MSWJ (1). The characteristic feature in our patient was that MSWJ disappeared in association with improvement of hydrocephalus, and reappeared when hydrocephalus was exacerbated. Some leftward overshoots of the eye movements shown by motion analysis might be attributable to hand movements during video recording or rotatory movements of the patient's head, but suggest the possible coexistence of macrosaccadic oscillations.

For steady fixation, fixation neurons at the rostral pole of the superior colliculus play an important role by exciting the omnipause neuron located within the pontine raphe interpositus nucleus (3). In our patient, enlargement of the third ventricle and cerebral aqueduct due to post-hemorrhagic obstruction at the fourth ventricular outlet foramina may have stretched the superior colliculus, thereby decreasing activity of the fixation neurons and then omnipause neurons, and

eventually resulting in development of the MSWJ (Fig. 2). The reversible nature in our patient in response to treatment of hydrocephalus also supports functional mechanisms rather than destructive ones. Meanwhile, the superior colliculus shows reciprocal connections with the mesencephalic reticular formation, and pharmacological inhibition of GABAergic projections from the pars reticulata of the substantia nigra leads to the generation of irrepressible saccadic intrusions (4, 5). Destructive lesions resulting from hematoma in the midbrain might have promoted the development of MSWJ in our patient. The thalamus also contributes the programming of saccades, and electrical stimulation of the internal medullary lamina elicits contralaterally directed saccades in monkeys (6). Right-ward direction of the intrusive saccades in our patient might have been related to the right-sided thalamic lesion (7). The fastigial nuclei may also have had association with the saccadic intrusions in our patient, but CT showed no hematoma extension into the cerebellar parenchyma (1). The lack of electrooculographic examination represents a key limitation. There is no reported data on whether the rhythm pattern of MSWJ shown by motion analysis software in our patient is equivalent to the pattern on electrooculographic evaluation.

The authors state that they have no Conflict of Interest (COI).

References

- Leigh RJ, Zee DS. *The Neurology of Eye Movements*. 4th ed. Oxford University Press, New York, 2006.
- Dalal KK, Joshua AM, Nayak A, Mithra P, Misri Z, Unnikrishnan B. Effectiveness of prowling with proprioceptive training on knee hyperextension among stroke subjects using videographic

- observation- a randomised controlled trial. *Gait Posture* **61**: 232-237, 2018.
3. Hikosaka O, Wurtz RH. Modification of saccadic eye movements by GABA-related substances. I. Effect of muscimol and bicuculline in monkey superior colliculus. *J Neurophysiol* **53**: 266-291, 1985.
 4. Moschovakis AK, Karabelas AB, Highstein SM. Structure-function relationships in the primate superior colliculus. II. Morphological identity of presaccadic neurons. *J Neurophysiol* **60**: 263-302, 1988.
 5. Hikosaka O, Wurtz RH. Modification of saccadic eye movements by GABA-related substances. II. Effects of muscimol in monkey substantia nigra pars reticulata. *J Neurophysiol* **53**: 292-308, 1985.
 6. Schlag-Rey M, Schlag J. Visuomotor functions of central thalamus in monkey. I. Unit activity related to spontaneous eye movements. *J Neurophysiol* **51**: 1149-1174, 1984.
 7. Rosenberg ML, Fernandez-Villa A, McKinney J. Stimulus sensitive constant micro macro square-wave jerks in a comatose patient. *Neuroophthalmology* **37**: 73-77, 2013.
- The Internal Medicine is an Open Access journal distributed under the Creative Commons Attribution-NonCommercial-NoDerivatives 4.0 International License. To view the details of this license, please visit (<https://creativecommons.org/licenses/by-nc-nd/4.0/>).

© 2021 The Japanese Society of Internal Medicine
Intern Med 60: 2487-2490, 2021