

Neurological Deficit-Simulating Transient Ischemic Attacks due to Intracranial Meningioma

Report of 3 Cases

Simcha Davidovitch^a, Natan Gadoth^b

^aNeurological Unit, Hasharon Hospital, Golda Medical Center, and

^bDepartment of Neurology, Beilinson Medical Center, Petah Tiqva, The Sackler School of Medicine, Tel Aviv University, Israel

Key Words. Meningioma · Brain edema · Intracranial pressure, increased · Ischemic attacks, transient

Abstract. In three patients with intracranial meningioma, several episodes resembling classical transient ischemic attacks caused a significant delay in the correct diagnosis. It seems that this diagnostic 'pitfall' is not rare. The mechanism of such episodes also known as 'transient tumor attacks' might be of vascular origin.

When confronted with a patient suffering from transient neurological deficit, which can be attributed to vascular insufficiency of a certain cerebral blood vessel, the possibility of a brain tumor will be only rarely considered. However, such cases have been previously described and even gained the name 'transient tumor attacks' [1]. Bearing in mind the possibility of frequent misdiagnosis in similar cases, we would like to describe three patients in whom episodes of neurological deficit resembling transient ischemic attacks (TIA) or reversible ischemic neurological deficit (RIND) were the initial manifestations of intracranial meningioma.

Case Reports

Case 1

A 42-year-old, previously healthy Muslim housewife noticed one morning that while drinking, she was unable to retain the fluid, which spilled out of the right side of her mouth. Subsequently, severe right shoulder pain and weakness of the right side of her body initiated her first admission, one week later. She was found to have flattening of the right nasolabial fold, weakness of the right upper extremity thought to be secondary to shoulder tenderness and a questionable drift of the right leg. The rest of a detailed physical and neurological examination was normal. Routine blood studies, urinalysis, electrocardiography, X-rays of chest, shoulders, skull and cervical spine, isotope brain scan and electroencephalography were

normal or negative. An orthopedic consultant diagnosed right subacromial bursitis. Her symptoms and signs cleared during the course of several days with physiotherapy. Two years later she presented with sudden left hemiparesis accompanied by generalized non-pulsating headache. She was found to have left hemiparesis and hypoaesthesia, but with no alteration of muscle tone or deep tendon reflexes. Routine blood studies, urinalysis and electroencephalography were normal. Skull X-ray showed a right parietooccipital calcification and isotope brain scan showed pathological uptake at the right parasagittal region. Cerebral CT revealed a normal ventricular system and three round calcified masses. The largest was enhanced with contrast medium, located at the right parasagittal region partially obliterating the sagittal sinus; the other two similar masses were smaller, adjacent to the periosteum (fig. 1). The patient's headaches disappeared and her left-sided weakness improved significantly. It was felt that surgery was not necessary. She was discharged and during one year follow-up was symptom-free.

Case 2

A 70-year-old Jewish female had experienced sudden right-sided weakness. She had right hemiparesis with hyperactive reflexes and a right Babinski's sign. Electroencephalography was normal; however, left frontotemporal isotope uptake was present. Her symptoms cleared in 72 h and she was thought to have a RIND. Three months later she was readmitted with right-sided weakness and paresthesias, weakness of the right lower face and dysphasia, which lasted for 15 min. Cerebral angiography was normal and the patient was discharged with the diagnosis of recurrent TIA. Her third admission occurred 4 years later when she experienced a similar brief and transient attack of right-sided weakness accompanied by dysphasia. Electroencephalography was again normal and an isotope brain scan

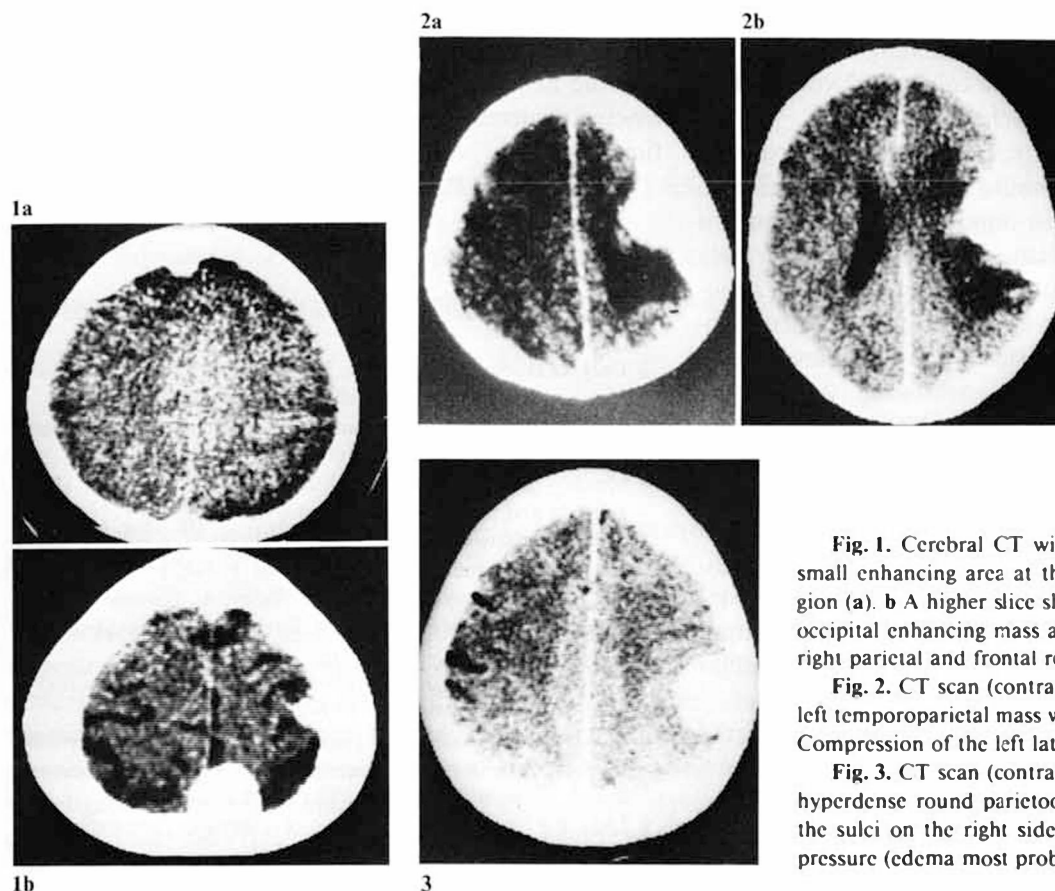


Fig. 1. Cerebral CT with contrast media showing a small enhancing area at the left parasagittal frontal region (a). b A higher slice shows a large right parasagittal occipital enhancing mass and two smaller masses at the right parietal and frontal regions.

Fig. 2. CT scan (contrast-enhanced). There is a large left temporoparietal mass with surrounding edema (a, b). Compression of the left lateral ventricle is evident (b).

Fig. 3. CT scan (contrast-enhanced). There is a large hyperdense round parietooccipital mass. Effacement of the sulci on the right side indicates an associated high pressure (edema most probably).

showed an area of positive uptake at the left frontotemporal region, unchanged from the scan obtained 5 years earlier. CT scan revealed a large enhanced space-occupying lesion at the left parietal region (fig. 2). The patient refused an operation and had 5 additional 'TIA'. The tumor, which was found to be a meningioma, was removed 5 years after her first admission. During the following 2 years she did not experience further neurological deficits.

Case 3

An elderly Jewish female had two short episodes of severe dizziness and left lower extremity weakness in January and June, 1977, when she was 68 years old. She was evaluated by her family physician who thought that she had TIA. A year later she had two similar episodes during the course of one week. At that time blood pressure was 200/100 mm Hg and she was started on antihypertensive medication, which she took for a short time only. At the age of 70 she experienced two additional episodes during which she felt perioral numbness, dizziness and left lower extremity weakness. The family history is remarkable for cerebrovascular disease in young age in her father and three brothers.

On admission her physical and neurological evaluation was normal. Blood pressure was 200/100 mm Hg and ophthalmodynamometry was normal. Routine laboratory data including CBC, urinalysis, SMA₁₂, serum cholesterol and plasma lipids, skull and chest X-rays and vestibular function tests were normal. Electrocardiography showed evidence of mild myocardial ischemia and the cervical spine X-rays showed marked spondylosis at C₅-C₇ level. Electroencephalo-

graphy was normal, but isotope brain scan demonstrated a positive uptake area 3 cm in diameter in the right parietooccipital region. A CT scan demonstrated a large enhancing round mass in the right parietal region which was felt to be a meningioma (fig. 3). It was felt that at this stage surgery could be postponed. Repeated CT scans and neurological evaluations during 4 years following her admission were unchanged. She did not experience any additional attack of transient neurological deficits. However, she had an acute myocardial infarction and an attack of transient coronary ischemia during the follow-up period.

Discussion

In case No. 1 with 3 meningiomas the obscure onset and the negative medical and neurological evaluation led to a 2-year delay in the diagnosis. Although the patient did not present with signs compatible with the definition of TIA, she had what might be called RIND. Case No. 2 with a large meningioma could have been diagnosed as having a mild thromboembolic cerebrovascular accident on her first admission, considering the clinical presentation and the positive isotope cerebral scan. However, two subsequent episodes were compatible with TIA.

Case No. 3, also with a cerebral meningioma, had numerous classical TIA during the course of 2 years before the correct diagnosis was reached.

In the last few years an increasing number of patients with clinical features resembling classical TIA have been found to suffer from brain tumors. The most frequent tumor found was a supratentorial meningioma [1]. Daly et al. [2] reported intermittent cerebral symptoms simulating TIA in 8% of their 210 patients with meningiomas. The transient clinical signs were hemiparesis, dysphasia, blindness, ataxia and paresthesia. An unusual patient reported by Fowler [3] had frequent TIA-like symptoms during 44 years prior to the diagnosis of meningioma. Recurrent neurological deficit in the form of transient global amnesia has recently been reported in association with temporal meningioma [4]. TIA-like episodes may also be caused by chronic subdural hematomas [5, 6]. Meningioma may even cause recurrent transient focal neurological signs, simulating retrobulbar neuritis [7].

Several mechanisms have been suggested for the pathophysiology of these 'transient tumor attacks', such as local pressure of the tumor, Todd's paralysis and vascular insufficiency. This could be due to vasospasm similar to migraine [1], 'steal syndrome' or alteration of blood flow due to dynamic changes in the extent of local brain edema [8]. A popular explanation is the spreading cortical depression theory introduced by Leão [9].

One may also consider the simultaneous occurrence of classical TIA and meningioma in the same individual. This might be the case in our third patient. TIA-like episodes may thus mask the presence of a serious treatable condition. Indeed, although some believe that careful clinical criteria are sufficient to diagnose TIA and that no additional neuroradiological studies are necessary to establish such a diagnosis [10], others report on a significant diagnostic error when using routine CT scanning in the evaluation of TIA. Weisberg and Nice [11] found 15% of mass lesions presenting as TIA while Kinkel and Jacobs [12] found overt thrombotic lesions in 35% of patients with TIA.

Our report confirms again the need for complete clinical and neuroradiological evaluation in patients experiencing recurrent episodes of reversible neurological deficits.

References

- 1 Ross, R.T.: Transient tumor attacks. *Archs Neurol.* 40: 633-636 (1983).
- 2 Daly, D.D.; Svien, H.J.; Yoss, R.E.: Intermittent cerebral symptoms with meningiomas. *Archs Neurol.* 5: 287-293 (1961).
- 3 Fowler, G.W.: Meningioma and intermittent aphasia of 44 years duration. *J. Neurosurg.* 33: 100-102 (1970).
- 4 Meador, K.J.; Adams, R.J.; Flanigin, H.F.: Transient global amnesia and meningioma. *Neurology* 35: 769-771 (1985).
- 5 Dell, S.O.; Batson, R.; Kasdon, D.L.; Peterson, T.H.: Aphasia in subdural hematoma. *Archs Neurol.* 40: 177-179 (1983).
- 6 Melamed, E.; Lavy, S.; Reches, A.; Sahar, A.: Chronic subdural hematoma simulating transient cerebral ischemic attacks. *J. Neurosurg.* 42: 101-103 (1975).
- 7 Sandyk, R.: Meningioma presenting with recurrent retrobulbar neuritis. *S. Afr. med. J.* 61: 857-858 (1982).
- 8 Lundberg, N.: Continuous recording and control of ventricular fluid pressure in neurosurgical practice. *Acta psychiat. neurol. scand.* 36: suppl. 149, pp. 1-193 (1960).
- 9 Leão, P.P.: Spreading depression of activity in the cerebral cortex. *J. Neurophysiol.* 7: 359-390 (1944).
- 10 Sandercock, P.; Molyneux, A.; Warlow, C.H.: Value of computed tomography in patients with stroke: Oxfordshire community stroke project. *Br. med. J.* 290: 193-197 (1985).
- 11 Weisberg, L.A.; Nice, C.H.N.: Intracranial tumors simulating the presentation of cerebrovascular syndromes, early detection with cerebral computed tomography. *Am. J. Med.* 63: 517-524 (1977).
- 12 Kinkel, W.R.; Jacobs, L.: Computerized axial transverse tomography in cerebrovascular disease. *Neurology* 26: 924-930 (1976).

Received: November 10, 1986

Accepted: June 1, 1987

Dr. S. Davidovitch, MD
Head, Neurological Unit
Hasharon Hospital
Petah Tikva (Israel)