

[CASE REPORT]

Heterozygous Cysteine-sparing *NOTCH3* Variant p.Val237Met in a Japanese Patient with Suspected Cerebral Autosomal Dominant Arteriopathy with Subcortical Infarcts and Leukoencephalopathy

Yuya Kano^{1,2}, Ikuko Mizuta³, Akihiko Ueda⁴, Hiroaki Nozaki⁵, Keita Sakurai⁶, Osamu Onodera⁵, Yukio Ando^{4,7}, Kentaro Yamada², Hiroyuki Yuasa¹ and Toshiki Mizuno³

Abstract:

A 64-year-old Japanese man with recurrent cerebral ischemic events and cognitive impairment was suspected of having cerebral autosomal dominant arteriopathy with subcortical infarcts and leukoencephalopathy (CADASIL) because of a family history and brain magnetic resonance imaging findings of cerebral white matter hyperintensities. The cysteine-sparing variation p.Val237Met was identified in *NOTCH3*. An intensive skin biopsy showed negative results (no granular osmiophilic material or positive NOTCH3 immunostaining), suggesting that the patient's definite diagnosis and pathogenicity of p.Val237Met were uncertain. We additionally reviewed previous reports of two Japanese families with p.Val237Met.

Key words: cerebral autosomal dominant arteriopathy with subcortical infarct and leukoencephalopathy (CADASIL), p.Val237Met, granular osmiophilic material (GOM), pathogenicity

(Intern Med 60: 2479-2482, 2021)

(DOI: 10.2169/internalmedicine.6096-20)

Introduction

Cerebral autosomal dominant arteriopathy with subcortical infarcts and leukoencephalopathy (CADASIL), clinically characterized by migraine, recurrent ischemic events, mood disturbance, apathy, and cognitive impairment, is the most common form of hereditary small-vessel disease caused by mutations in the *NOTCH3* gene (1, 2). CADASIL can be definitively diagnosed by genetic testing. Thus far, more than 200 mutations localized to the domain of the 34 epidermal growth factor repeats (EGFRs) encoded by exons 2-24 in *NOTCH3* have been reported (3, 4). The typical pathogenic mutations are heterozygous missense ones altering the number of cysteine amino acids in a certain EGFR (1).

If a cysteine-sparing missense variant of unknown signifi-

cance is identified, the diagnosis of CADASIL can be confirmed by detecting granular osmiophilic material (GOM) or positive NOTCH3 immunostaining in skin biopsy specimen (5). GOM, the pathological marker of CADASIL, is an abnormal protein aggregation containing the NOTCH3 extracellular domain (N3ECD), localizing around the basement membrane of vascular smooth muscle cells (6). We recently identified a cysteine-sparing *NOTCH3* variant, p.Val237Met, in a patient with suspected CADASIL. Thus far, two groups have reported Japanese patients with this mutation. However, their interpretations of its pathogenicity were contradictory, with one concluding it to be pathogenic (7, 8) while the other concluded that it does not have certain pathogenicity (9).

In this study, we evaluated the pathogenicity of *NOTCH3* p.Val237Met based on the findings in our present patient

¹Department of Neurology, Tosei General Hospital, Japan, ²Department of Neurology, Nagoya City East Medical Center, Japan, ³Department of Neurology, Graduate School of Medical Science, Kyoto Prefectural University of Medicine, Japan, ⁴Department of Neurology, Graduate School of Medical Science, Kumamoto University, Japan, ⁵Department of Neurology, Brain Research Institute, Niigata University, Japan, ⁶Department of Radiology, National Center for Geriatrics and Gerontology, Japan and ⁷Department of Amyloidosis Research, Nagasaki International University, Japan

Received: August 12, 2020; Accepted: January 14, 2021; Advance Publication by J-STAGE: March 8, 2021

Correspondence to Dr. Toshiki Mizuno, mizuno@koto.kpu-m.ac.jp

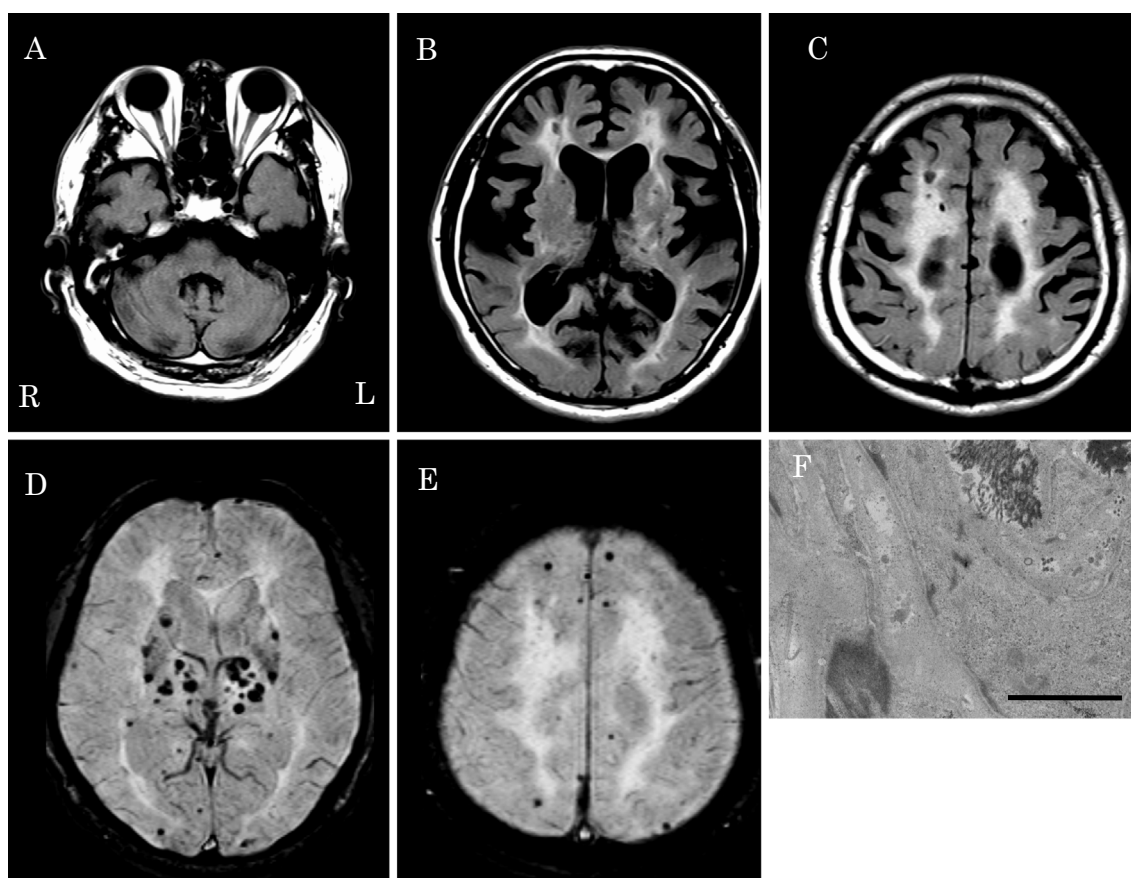


Figure. Brain MRI and electron micrograph of a dermal artery. Brain fluid-attenuated inversion-recovery imaging shows multiple hyperintense lesions in the bilateral subcortical white matter, basal ganglia, and thalami. Despite small nonspecific signal changes in the external capsules, no abnormal signal changes are detected in the subcortical white matter of the temporal poles (A, B, C). Susceptibility-weighted imaging shows many micro bleeds, mainly in the basal ganglia (D, E). Granular osmiophilic material (GOM) deposition is not detected around the basement membrane of the vascular smooth muscle cells of small arterioles (Bar=2 μ m) (F).

and those from the two previous reports.

Case Report

A 64-year-old Japanese man who experienced two episodes of lacunar infarction at 59 and 62 years old and an episode of transient ischemic attack of weakness in the left leg at 64 years old was admitted to our hospital. The patient experienced difficulty moving his right leg and was administered cilostazol (200 mg/day) for cerebral infarction. He had no vascular risk factors other than smoking and had no history of migraine. His brother and sister had suffered from stroke; however, little medical information was available regarding his deceased parents.

On admission, his blood pressure was 140/92 mmHg, and his pulse was regular. A neurological examination showed right hemiplegia, and his score on the Mini-Mental State Examination (10 of a total of 30: disorientation, memory disturbance, and executive function impairment were noticeable) indicated cognitive impairment. His laboratory parameters, including blood counts, lipid profile, and blood glucose

level, were within normal ranges. All of the following coagulation-related test results were also within normal ranges: protein S, protein C, anti-DNA antibodies, lupus anticoagulant, anti-cardiolipin β 2-glycoprotein I complex antibodies, and anti-cardiolipin antibodies.

Stenoses and plaques in the internal carotid artery were not observed on carotid ultrasound, and echocardiography revealed normal wall motion without thromboses. No arrhythmias were detected on the 24-hour Holter electrocardiogram. However, diffusion-weighted brain magnetic resonance imaging (MRI) demonstrated a hyperintense area in the left basal ganglia, indicating the presence of an acute infarct. Additionally, fluid-attenuated inversion recovery (FLAIR) imaging showed bilateral multiple hyperintense lesions in the subcortical white matter, basal ganglia, thalami, and brainstem. Slight nonspecific FLAIR signal changes were detected in the external capsules, whereas no abnormal changes were detected in the subcortical white matter of the temporal poles (Figure). Susceptibility-weighted imaging showed multiple microbleeds in the bilateral basal ganglia, subcortical white matter, and brainstem; however, no abnor-

Table. Carrier Frequencies of *NOTCH3* c.709G>A (p.Val237Met) in General Populations of Different Ethnicities.

	East Asian	South Asian	European (Non-Finnish)	Finnish	Latino	Ashkenazi Jewish	African
Number of individuals	9,973	15,307	64,265	12,559	17,711	5,163	12,471
Number of carriers (frequency)	47 (0.47%)	1 (0.0065%)	2 (0.0031%)	2 (0.016%)	2 (0.011%)	0 (0%)	0 (0%)

Values were downloaded on July 29, 2020 from gnomAD (<https://gnomad.broadinstitute.org>). All carriers were heterozygous.

malities were observed on MR angiography. These abnormalities and brain atrophy gradually progressed over the next five years.

We suspected a diagnosis of hereditary cerebral small vessel disease from the patient's clinical course, family history, and detection of severe small-vessel diseases on brain MRI. The cause of cognitive impairment appeared to be vascular. We ruled out the possibility of Alzheimer's disease, idiopathic normal pressure hydrocephalus, and chronic subdural hematoma based on the MRI features. In addition, his blood tests showed a normal thyroid function, ammonia levels, and drug resistance; thus, they were also ruled out.

Genetic testing was performed after receiving written informed consent, and approval for the genetic study was obtained from the University Ethical Committee. CADASIL was first suspected, as it is the most common hereditary small-vessel disease. Sanger sequencing of whole exons 1-33 of *NOTCH3* identified the heterozygous cysteine-sparing variation c.709G>A (p.Val237Met in EGF_R 6) in exon 5 of the *NOTCH3* gene.

Because the pathogenicity of p.Val237Met had not yet been established, we next performed a skin biopsy. Immunoreactivity for the *NOTCH3* extracellular domain was not detected in the vessels of the skin specimens (data not shown). Electron microscopy did not detect GOM in the small arterioles in the deep dermis, which is where this material preferentially localizes (Figure).

Discussion

Based on the negative findings of the skin biopsy (no GOM or *NOTCH3* immunostaining), the patient's definite diagnosis and pathogenicity of p.Val237Met remain uncertain.

The diagnostic test is limited by the sensitivity of the skin biopsy. Although the specificity of GOM is 100%, its sensitivity has ranged between 44.4% and 100% in previous reports (10). The successful detection of GOM depends on the number of vessels included in the sample as well as technical factors. Light microscopic observation of *NOTCH3* immunostaining has the advantage of evaluating a broad area, including multiple vessels. The sensitivity and specificity of *NOTCH3* immunostaining are reported to be 90.2-85.4% and 95.2-100%, respectively (11). To overcome these technical issues, an analysis of the skin biopsy specimen was performed by the expert (A.U.) in this study group who spe-

cializes in the pathological diagnosis of CADASIL (12, 13).

Another limitation is the lack of research on other causative genes of hereditary cerebral small vessel diseases. We next focused on *high-temperature requirement A serine peptidase 1 (HTRA1)*, a gene that plays a causative role in cerebral autosomal recessive arteriopathy with subcortical infarcts and leukoencephalopathy (CARASIL) (14). Heterozygous mutations in *HTRA1* have occasionally been identified among *NOTCH3*-negative patients with cerebral small-vessel disease, establishing the concept of cerebral small-vessel disease (CSVD) with a heterozygous *HTRA1* mutation (15, 16). Genetic testing of *HTRA1* in our patient revealed a negative result. Further diagnostic approaches with this patient should involve analyses of other causative genes of hereditary CSVDs, including *COL4A1*, *COL4A2*, *TREX1*, *GLA*, and *CTSA* (5), as well as CSVD-associated genes, including *ACE* and *MTHFR* (17).

The p.Val237Met variant was previously reported in two Japanese families. The first family was reported by Adachi et al. The two affected siblings developed gait disturbance in their sixth decade of life, and one of them had dementia and headache. The MRI findings included periventricular hyperintensities and multiple small infarctions in the subcortical white matter and basal ganglia (7). They were diagnosed with CADASIL because GOM was detected in the skin biopsy obtained from one of the patients. However, a typical cysteine-related mutation could not be completely excluded, as the regions they analyzed were limited to *NOTCH3* exons 3-4, 11, and 19 as well as the neighboring regions (8).

The second patient with p.Val237Met was identified by Kunii et al. through a genetic analysis of 60 adult patients with leukoencephalopathy by next-generation sequencing of all exons of 55 genes, including *NOTCH3*, associated with leukoencephalopathy (9). The reported patient was a 34-year-old man without any family history of stroke. He had no symptoms except for a history of headache from 31 years old. They noted that the MRI findings were atypical for CADASIL and concluded that the pathogenicity of p.Val237Met was uncertain, mainly due to the relatively high carrier frequency in their in-house database consisting of exome data obtained from 575 Japanese individuals (3/575, 0.52%) (9).

The p.Val237Met carrier frequency in the controls described by Kunii et al. is comparable to that in East Asian populations (47/9,973; 0.47%) reported in the Genome Aggregation Database (gnomAD, <https://gnomad.broadinstitute>).

org), a large-scale genome variation database from exome and genome sequencing data of the general population. The p.Val237Met carrier frequency in other ethnic populations is extremely rare or absent, suggesting that p.Val237Met may be a rare polymorphism accumulating in East Asians (Table).

The pathogenicity of p.Val237Met remains unclear, as we did not note GOM or NOTCH3 immunostaining on a skin biopsy in our patient with p.Val237Met. Our results will contribute to the accurate assessment of p.Val237Met in the genetic testing of CADASIL and aid in the performance of a comprehensive genomic analysis. Cumulative evidence from further analyses is needed to validate our findings.

The authors state that they have no Conflict of Interest (COI).

Financial Support

This study was supported by a grant-in-aid for Research on Intractable Disease from the Japanese Ministry of Health, Labor, and Welfare, Japan (H30-Nanchitou(Nan)-Ippan-006).

References

- Chabriat H, Joutel A, Dichgans M, Tournier-Lasserre E, Bousser MG. CADASIL. *Lancet Neurol* **8**: 643-653, 2009.
- Chabriat H, Joutel A, Tournier-Lasserre E, Bousser MG. CADASIL: yesterday, today, tomorrow. *Eur J Neurol* **27**: 1588-1595, 2020.
- Rutten JW, Haan J, Terwindt GM, van Duinen SG, Boon EM, Lesnik Oberstein SA. Interpretation of *NOTCH3* mutations in the diagnosis of CADASIL. *Expert Rev Mol Diagn* **14**: 593-603, 2014.
- Mizuno T, Mizuta I, Watanabe-Hosomi A, Mukai M, Koizumi T. Clinical and genetic aspects of CADASIL. *Front Aging Neurosci* **12**: 91, 2020.
- Mancuso M, Arnold M, Bersano A, et al. Monogenic cerebral small-vessel diseases: diagnosis and therapy. Consensus recommendations of the European Academy of Neurology. *Eur J Neurol* **27**: 909-927, 2020.
- Baudrimont M, Dubas F, Joutel A, Tournier-Lasserre E, Bousser MG. Autosomal dominant leukoencephalopathy and subcortical ischemic stroke. A clinicopathological study. *Stroke* **24**: 122-125, 1993.
- Adachi Y, Nakashima K. Cerebral autosomal dominant arteriopathy with subcortical infarcts and leukoencephalopathy (CADASIL) characteristics in Japan: variety of clinical features. *Intern Med* **39**: 681-682, 2000.
- Adachi Y, Hayashi M, Nakashima K. Examination of notch3 mutations in Japanese patients with leukoencephalopathy without hypertension. *Jpn J Stroke* **28**: 585-589, 2006 (in Japanese, Abstract in English).
- Kunii M, Doi H, Ishii Y, et al. Genetic analysis of adult leukoencephalopathy patients using a custom-designed gene panel. *Clin Genet* **94**: 232-238, 2018.
- Tikka S, Mykkänen K, Ruchoux MM, et al. Congruence between *NOTCH3* mutations and GOM in 131 CADASIL patients. *Brain* **132**: 933-939, 2009.
- Lesnik Oberstein SA, van Duinen SG, van den Boom R, et al. Evaluation of diagnostic NOTCH3 immunostaining in CADASIL. *Acta Neuropathol* **106**: 107-111, 2003.
- Ueda A, Hirano T, Takahashi K, et al. Detection of granular osmiophilic material of cerebral autosomal dominant arteriopathy with subcortical infarcts and leukoencephalopathy by light microscopy in frozen sections. *Neuropathol Appl Neurobiol* **35**: 618-622, 2009.
- Ueda A, Ueda M, Nagatoshi A, et al. Genotypic and phenotypic spectrum of CADASIL in Japan: the experience at a referral center in Kumamoto University from 1997 to 2014. *J Neurol* **262**: 1828-1836, 2015.
- Hara K, Shiga A, Fukutake T, et al. Association of *HTRA1* mutations and familial ischemic cerebral small-vessel disease. *N Engl J Med* **360**: 1729-1739, 2009.
- Verdura E, Hervé F, Scharrer E, et al. Heterozygous *HTRA1* mutations are associated with autosomal dominant cerebral small vessel disease. *Brain* **138**: 2347-2358, 2015.
- Nozaki H, Kato T, Nihonmatsu M, et al. Distinct molecular mechanisms of *HTRA1* mutants in manifesting heterozygotes with CARASIL. *Neurology* **86**: 1964-1974, 2016.
- Pandey P, Pradhan S, Modi DR, Mittal B. MTHFR and ACE gene polymorphisms and risk of vascular and degenerative dementias in the elderly. *Brain Cogn* **71**: 295-299, 2009.

The Internal Medicine is an Open Access journal distributed under the Creative Commons Attribution-NonCommercial-NoDerivatives 4.0 International License. To view the details of this license, please visit (<https://creativecommons.org/licenses/by-nc-nd/4.0/>).