

Originals

Intrauterine skull depression and intracranial hemorrhage in a premature infant

D. G. Batton, F. DiCarmino and D. K. Boal

Division of Newborn Medicine, Department of Pediatrics and the Department of Radiology, The Milton S. Hershey Medical Center, Pennsylvania State University, Hershey, Pennsylvania, USA

Abstract. The authors describe a case of a premature infant born with a parietal skull depression who suffered an intraventricular hemorrhage and an ipsilateral intracerebral injury. At 21 months of life the infant's gross motor milestones were delayed and he had moderate spastic hemiplegia. Although skull depressions at birth are usually benign, they may be associated with long-term neurologic sequelae.

Skull depressions at birth usually occur in term infants and are most often associated with a good outcome [1-8]. We report a premature infant who was born with a parietal skull depression, suffered an intraventricular hemorrhage (IVH), an intraparenchymal injury, and developed neurologic sequelae.

Case presentation

This infant was born to a 34-year-old gravida 4 para 2-0-1-2 mother at 28 weeks of gestation. The mother developed spontaneous rupture of the membranes 4 days prior to delivery and was transferred to our hospital in an advanced stage of premature labor. Vaginal examination revealed a compound presentation and prolapse of the umbilical cord. Fetal bradycardia neces-

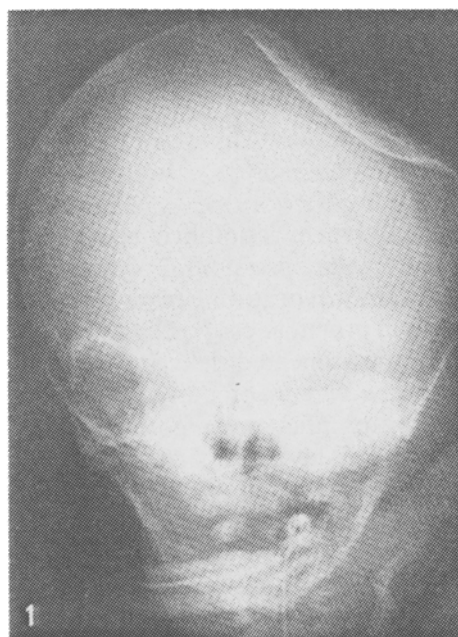


Fig. 1. Anteroposterior skull film demonstrates a large left parietal skull depression

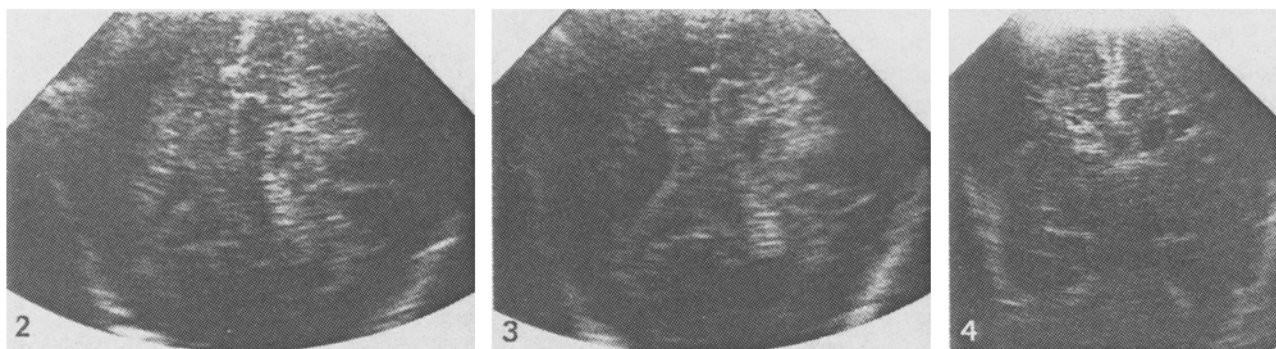


Fig. 2. Cranial sonogram on the first day of life. Coronal view demonstrates a left intraparenchymal echodense lesion (bilateral IVH is not visualized on this view)

Fig. 3. Coronal sonogram at 1 week of life demonstrates mild ventricular dilatation and persistent intraparenchymal echodense lesion

Fig. 4. Coronal sonogram at 4 months of life demonstrates a left periventricular cyst

sitated delivery by emergency cesarean section while the presenting part was held off the umbilical cord. No uterine anomalies were noted at delivery. A one minute Apgar score of 1 prompted endotracheal intubation and mechanical ventilation resulting in a five minute Apgar score of 8. Physical examination revealed a 1300-g, 28-week, AGA male with extensive bruising of the left side of the face, shoulder and neck. A left parietal skull depression measured 4 × 4.5 cm. Chest X-ray was consistent with hyaline membrane disease and skull films revealed a left parietal skull depression (Fig. 1). Cranial ultrasonography demonstrated bilateral IVH (not seen on views provided) without ventricular dilatation and a left periventricular echodensity (Figs. 2, 3). The infant was allowed to recover from his respiratory distress and on the fourth day of life underwent neurosurgical elevation of the skull depression without complication. He made an uneventful recovery and his neurological examinations throughout his 38 day hospital stay remained normal. Repeat cranial ultrasound examination at 4 months of life revealed a left periventricular cyst (Fig. 4). The infant, subsequently, developed right-sided spastic hemiplegia and Bayley developmental assessment at age 21 months revealed significant delays in gross motor milestones.

Discussion

Although occasionally there is no obvious explanation for intrauterine skull depressions [3, 4], most often the deformity has been attributed to pressure from maternal pelvic prominences [1, 2] or associated with a difficult, instrumented delivery [5-8]. Although we cannot be certain of the cause of the skull depression in the infant we report, there are two likely possibilities. The depression could have occurred as a result of fetal malpresentation and pressure from maternal pelvic structures. The extensive bruising of the left side of the infant's upper body lends support to this theory. An alternative possibility is that the skull depression resulted from the attempt to keep the presenting part off of the prolapsed umbilical cord. In this case the examiner's hand may have directly depressed this premature infant's skull, although this was not suspected at the time.

Few cases of intracranial hemorrhage associated with skull depression have been reported. Natelson and Sayers [6] reported 15 infants with skull depression including 2 infants with subdural hemorrhage and 3 infants with epidural hematomas. However, most of these infants were born at term and did not have the additional complications of prematurity. We are unaware of a previous case report of neonatal skull depression associated with IVH and a major intraparenchymal lesion in a preterm infant. Whether this association is etiologic in nature or coincidental is unknown. Certainly, both IVH and periventricular injuries are common in premature infants with respiratory distress [9, 10].

We assume the periventricular echodense lesion which underwent cystic transformation represents a periventricular infarction and is most likely responsible for the sequelae of contralateral spastic hemi-

plegia. Periventricular infarctions have been described in premature infants primarily as part of two pathologic conditions. Firstly, hemorrhagic periventricular infarction may occur in conjunction with an ipsilateral large IVH [9]. Secondly, bilateral periventricular infarctions are described in premature infants with periventricular leukomalacia and are believed to be ischemic in origin [11]. Since the infant we report did not have an ipsilateral large IVH and since the unilateral periventricular lesion occurred on the same side as the skull depression, it is possible that the depression caused the periventricular infarction. Theoretically, a skull depression could cause periventricular infarction either by compression of arterial vessels producing ischemia or by elevating cerebral venous pressure. Both of these hemodynamic alterations have been suggested as possible mechanisms for intraparenchymal hemorrhagic infarction in preterm infants [9].

Although an etiologic relationship cannot be confirmed, this case illustrates that neonatal skull depression in a premature infant can be associated with intraparenchymal injury and neurologic sequelae. Consequently, infants who are born with a skull depression should be evaluated for intracranial pathology and receive long-term developmental follow-up.

References

1. Axton JHM, Levy LF (1965) Congenital moulding depressions of the skull. *Br Med J* 1: 1644
2. Alexander EJr, Davis CHjr (1969) Intrauterine fracture of the infant's skull. *J Neurosurg* 30: 446
3. Eisenberg D, Kirchner SG, Perrin EC (1984) Neonatal skull depression unassociated with birth trauma. *AJR* 143: 1063
4. Garza-Mercado R (1982) Intrauterine depressed skull fractures of the newborn. *Neurosurgery* 10: 694
5. Loeser JD, Kilburn HL, Jolley T (1976) Management of depressed skull fracture in the newborn. *J Neurosurg* 44: 62
6. Natelson SE, Sayers MP (1973) The fate of children sustaining severe head trauma during birth. *Pediatrics* 51: 169
7. Saunders BS, Lazorit S, McArtor RD et al. (1979) Depressed skull fracture in the neonate. *Neurosurgery* 50: 512
8. Schragger GO (1970) Elevation of depressed skull fracture with a breast pump. *J Pediatr* 77: 300
9. Guzzetta F, Shackelford GD, Volpe S et al. (1986) Periventricular intraparenchymal echodensities in the premature newborn: critical determinant of neurologic outcome. *Pediatrics* 78: 995
10. Batton DG, DeWitte DB, Boal DK, et al. (1986) Incidence and severity of intraventricular hemorrhage: 1981-1984. *Am J Perinatol* 3: 353
11. Trounce JQ, Rutter N, Levene MI (1986) Periventricular leukomalacia and intraventricular haemorrhage in the preterm neonate. *Arch Dis Child* 61: 1196

Received: 16 March 1987; accepted: 8 June 1987

Dr. D.G. Batton
Department of Pediatrics
William Beaumont Hospital
3601 West Thirteen Mile Road
Royal Oak, MI 48072
USA