

Transient Global Amnesia and Stroke

Julien Bogousslavsky, Franco Regli

Service de Neurologie, Centre Hospitalier Universitaire Vaudois, Lausanne, Suisse

Key Words. Transient global amnesia · Stroke · Hemorrhage · Infarction

Abstract. Four patients who experienced isolated transient global amnesia had computed tomographic evidence for a cerebral infarct (3 cases) or hemorrhage (1 case). The medial part of the temporal lobe was involved in 2 patients (left in 1, right in 1), the left lentiform nucleus in 1 patient, and the left thalamus in 1 left-handed patient. These findings suggest that transient global amnesia may be associated with stroke in some cases, but it has no localizing value within the temporodiencephalic structures. No cerebrovascular events occurred over a 1- to 5-year follow-up, suggesting that transient global amnesia with infarction or hemorrhage is not a strong predictor of further stroke.

Transient global amnesia [1], previously called 'episode of confusion with amnesia' [2] or 'ictus amnésique' [3] refers to a sudden and isolated dysfunction of memory for recent events lasting a few hours. As emphasized by Caplan [4], this diagnosis should be reserved for 'pure amnesic attacks of an acute nature uncontaminated by other neurologic symptoms or signs and without fixed deficits'. The exact causes and mechanisms of transient global amnesia remain uncertain. Although an epileptic phenomenon has been suspected in some cases [5, 6], a vascular mechanism has been emphasized in most published series [7–16]. Transient ischemia in the territory of Heubner's artery [2], the anterior choroidal artery [9] or the posterior cerebral artery [8, 15–18] has been suspected, with reversible dysfunction of the frontotemporal structures involved in memory. Rare instances of acute transient memory dysfunction associated with focal cerebrovascular accidents [13–17, 19–21] or with other focal lesions [11, 12, 21–32] have been reported, but in most of them strict diagnostic criteria of transient global amnesia were not present. We now report on 4 patients with transient global amnesia in whom computed tomography (CT) showed a cerebral infarct or hemorrhage.

Patients and Methods

Methods

During a 6-year retrospective survey of all patients admitted to our hospital with a diagnosis of acute amnesia, we found that 4 patients with isolated transient global amnesia had a recent cerebral infarct or hemorrhage on CT. Transient global amnesia was defined according to previous guidelines [21, 33], excluding confusional states and transient amnesia associated with trauma or other acute neurologic dysfunction: anterograde amnesia of acute onset, with repetitive queries, supported by a witness, variable period of retrograde amnesia, but preserved remote memory, and resolution within 24 h with a residual amnesia of the acute episode. All patients were seen by a neurologist and a neuropsychologist. They underwent a standard battery of neuropsychological tests [34], including orientation to time and place, evocation of recent and remote events, verbal learning (Hebb's recurring digits, Rey auditory learning), visual learning (Corsi's block-tapping), Wisconsin card-sorting test, Stroop test, Luria's conflicting tasks, sequential rhythms and geometrical figures, spontaneous speech, naming, repetition of phonemes, words and sentences, auditory comprehension, writing, reading, oral and written calculation, limb (symbolic, imitation) praxias, drawing of a cube, Poppelreuter's test and orientation on a map. Follow-up was obtained by phone calls to the patients, their family and their physician. It must be mentioned that every patient adhering to our criteria for transient global amnesia did not undergo a brain CT scan; the 4 patients reported below were thus selected from a group of 42 patients who had a CT within a few days after the episode of transient global amnesia.

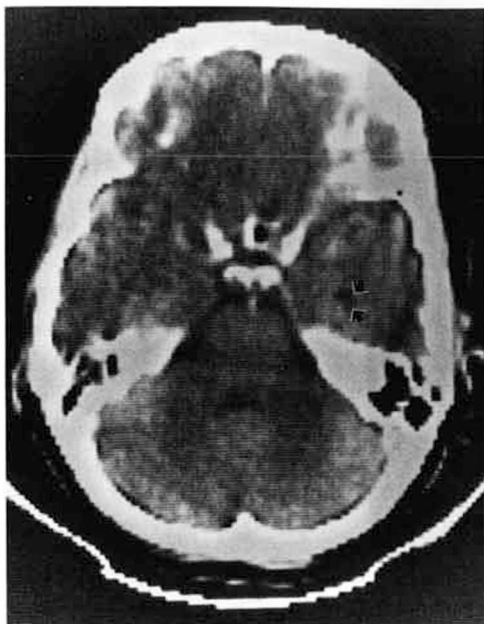


Fig. 1. CT scan of patient 1. Small infarct in the medial part of the right temporal lobe (arrow).

Case Reports

Case 1. A 61-year-old, right-handed, hypertensive housewife who had no history of neurologic disease suddenly looked 'bizarre' while eating breakfast with her husband. She suddenly said that she wanted to fix breakfast, although she had just been doing it a few minutes before, and she asked many times where was her sister who had been visiting her the preceding evening. She also checked the dishwasher several times, although it was empty. According to the husband, she did not mention any particular neurologic symptom, but was unable to remember what she had just been doing. She was admitted to hospital 6 h after onset. Neurologic and general examinations were normal, and the patient was well-oriented to time and place. She had no memory of any event between the preceding evening and her arrival at hospital. Standard neuropsychological testing done the same afternoon and the following day was normal. A brain CT scan done 3 days after admission showed a small round hypodense area within the medial part of the right temporal lobe suggesting a lacune (fig. 1). An electroencephalogram (EEG) showed scarce delta waves over the right frontotemporal region. Doppler ultrasounds of the extracranial arteries were normal. Electrocardiogram (ECG) showed a first-degree atrioventricular block. The patient was discharged on aspirin, 1 g/day, and has not experienced any further neurologic disturbance for the following 3 years.

Case 2. A 56-year-old right-handed mason was in good health until he suddenly started to ask repetitive questions to his colleagues at work. There was no history of recent trauma. According to his colleagues, he knew where he was, he had no speech disturbance, and he recognized them, but he did not remember what he had been doing the same day, asking repetitively 'what am I doing here?'. He looked anxious and walked from person to person asking the same question. He did not complain of any neurologic symptom. On admission 4 h later, the patient had recovered. He was oriented to time and place and the neurologic and general examinations were

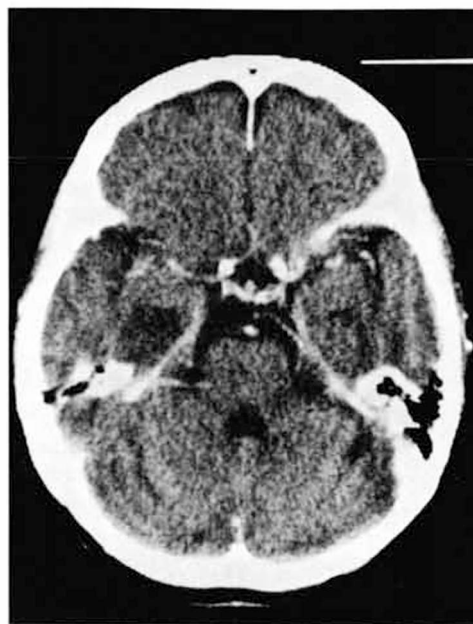


Fig. 2. CT scan of patient 2. Infarct in the medial left temporal lobe.

normal. He had no memory of the amnesic episode but remembered the time when he had left home the same morning. Standard neuropsychological testing the following day was normal. A brain CT scan done 2 days after admission showed a hypodense area in the left medial temporal lobe suggesting recent infarction (fig. 2). A EEG showed intermittent slow waves over the left hemisphere. Doppler ultrasounds of the extracranial arteries and ECG were normal. The patient was discharged on aspirin, 1 g/day, and has not experienced any further neurologic episode for the following 5 years.

Case 3. A 61-year-old, left-handed, diabetic housewife was relaxing in an armchair when she suddenly stood up and seemed 'confused', according to her daughter. She started to make repetitive queries about a meal she had to prepare and went many times to the television set, putting it on and off. Although her husband was in the next room and she had just seen him, she asked repetitively where he was. She did not complain of any other disturbance, except for a slight occipital headache. According to her family, she recovered within 6 h but could not remember the amnesic episode. She refused to go to the hospital, but she went to her physician 3 days later, who convinced her to have a neurologic check-up. She was admitted 4 days after the acute episode. Neurologic and general examinations and standard neuropsychological testing were normal. A brain CT scan showed a round hypodense area within the medial part of the left thalamus, suggesting infarction (fig. 3). An EEG showed episodic theta and delta waves over the left hemisphere. Doppler ultrasounds of the extracranial vessels showed no stenosis. ECG was normal. The patient was discharged on aspirin, 1 g/day. She did not experience further neurologic symptoms until she died during sleep 2 years later.

Case 4. A 71-year-old, right-handed, hypertensive, retired administrative officer was in good neurologic health until he came back from a shopping mall in the morning and asked several times

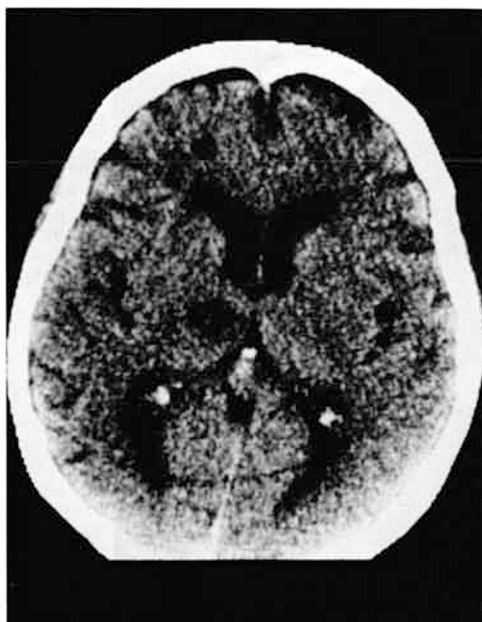

Fig. 3. CT scan of patient 3. Left medial thalamic infarct.

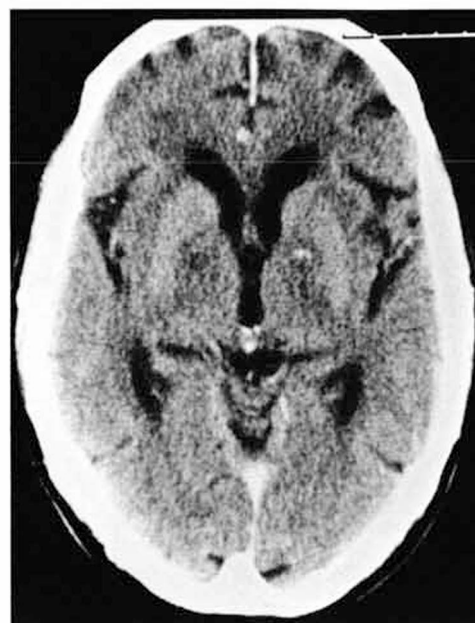

Fig. 4. CT scan of patient 4. Small hemorrhage in the left lentiform nucleus with surrounding edema.

his family what he had been doing that morning. He also looked several times in a closet for his tennis racket and wanted to call up a friend many times, to play a game, although he was told that his friend was at work. He did not complain of headaches or any other neurologic symptom. On admission 10 h later, the patient had recovered. He could not remember what he had been doing since breakfast time the same day, except the moment when his family took him to the hospital. On admission, neurologic and general examinations were normal. Standard neuropsychological testing done the day after admission was normal. A brain CT scan 36 h after the amnesic episode showed a hyperdense area in the left lentiform nucleus surrounded by a hypodense area, suggesting hemorrhage (fig. 4). An EEG was unremarkable. CT was checked 2 months later and showed no visible lesion. During the following year, the patient has had no recurrence and is in good health.

Comments

Although none of our 4 patients was seen by a neurologist during the acute amnesic episode, the description obtained from their family was precise enough to cast no doubt on the diagnosis of transient global amnesia. They all adhered to our strict diagnostic criteria. All had evidence for a cerebrovascular lesion on CT, but none had abnormal neurologic or neuropsychological findings. Though repeat CT was done in only 1 patient (No. 4) to ascertain the acuteness of the cerebrovascular lesion, the

CT aspects in the 3 other patients suggested recent infarction and none had history of prior transient ischemic attack or stroke. Yet, the exact temporal relation between the stroke and transient global amnesia could not be established in these 3 patients. Associated symptoms during the ictus were reported by only 1 patient, who complained of a moderate occipital headache and was found to have a thalamic infarct.

Vascular risk factors were reported in 52% of 210 patients with transient global amnesia [11, 12, 14, 15], but it must be emphasized that well-documented isolated transient global amnesia in the setting of cerebral infarction or hemorrhage has been reported rarely. In two CT series [13, 14] reporting uni- or bilateral temporal or thalamic infarction in 6 of 46 patients with transient global amnesia, clinical details were missing or scarce. Other isolated cases with temporal or deep hemispheric infarct [15, 21] or cerebral [20], subdural [35] or subarachnoid [12] hemorrhage have been reported, but in some, clinical data were lacking or poor, or acute confusion with amnesia seemed more likely than true transient global amnesia. However, Kushner and Hauser [16] reported 2 well-studied patients without prior stroke but with recent left (1 case) or right (1 case) thalamic infarction among 13 patients with transient global amnesia who underwent CT examination suggesting that transient global amnesia may be due to an acute vascular

lesion more often than previously claimed. Others have suggested a focal ischemic dysfunction in patients with transient global amnesia and mitral valve prolapse [11, 36], bicuspid [37] or replaced [11, 37] aortic valve, bradydysrhythmia [38], atrial fibrillation [5, 39], migraine [40–43], giant-cell arteritis [44], polycythemia [11], Sneddon's syndrome [45], and after angiography [46, 49], but with no CT confirmation. CT findings in our 4 patients suggest that transient global amnesia may be the sole neurologic manifestation of cerebral infarction or hemorrhage. However, as the timing of the cerebrovascular insult could not be proven in 3 of them, it remains unclear whether transient global amnesia was the result of acute ischemia or a delayed phenomenon in a previously asymptomatic stroke.

In our patients, the medial temporal lobe was involved in two instances, and the thalamus and lentiform nucleus in one instance each, suggesting that no precise location of lesion can be held responsible for transient global amnesia. The lateralization of the lesion did not seem to matter either, because 2 right-handed patients had a left-sided lesion, 1 right-handed patient had a right-sided lesion and 1 left-handed patient had a left-sided lesion. The absence of value of the lateralization of the lesion and of a constant localization within the temporal lobe, frontal lobe and diencephalon is also suggested by previous CT findings in vascular cases [13–16, 20, 21] and in 13 patients with tumor [11, 12, 21–32]. In 1 autopsied case [39] with carotid disease, atrial fibrillation and mitral annulus calcification, the brain showed diffuse ischemic changes. Why some patients with a temporal or diencephalic stroke have transient global amnesia without associated permanent neurologic disturbances remains unknown.

Over a follow-up from 1 to 5 years, none of our patients suffered further cerebrovascular events, although 1 died from an unknown cause during sleep. Transient global amnesia has been reported in patients with transient ischemic attacks, usually of the vertebrobasilar type [14, 16, 18, 50], and it has been suggested that more than 1% and less than 9% of the patients per year may suffer from a stroke [11, 12, 51, 52]. Our cases suggest that transient global amnesia as the isolated manifestation of stroke may not necessarily herald further cerebrovascular events.

Acknowledgements

We wish to thank A. Uske, MD, Department of Radiology, who provided the CT scans.

References

- 1 Fisher CM, Adams RD: Transient global amnesia. *Trans Am Neurol Assoc* 1958;83:143–146.
- 2 Bender MB: Syndrome of isolated episode of confusion with amnesia. *J Hillside Hosp* 1956;5:212–215.
- 3 Guyotat J, Courjon J: Les ictus amnésiques. *J Méd Lyon* 1956; 37:697–701.
- 4 Caplan R: Transient global amnesia and migraine. *Neurology* 1983;33:1107.
- 5 Fisher CM, Adams RD: Transient global amnesia. *Acta Neurol Scand* 1964;40(suppl 9):7–83.
- 6 Fisher CM: Transient global amnesia. Precipitating activities and other observations. *Arch Neurol* 1982;39:602–608.
- 7 Godlewski S: Les épisodes amnésiques (transient global amnesia). Etude clinique basée sur 33 observations inédites. *Sem Hôp Paris* 1968;44:553–577.
- 8 Heathfield KWG, Croft PB, Swash M: The syndrome of transient global amnesia. *Brain* 1973;96:729–736.
- 9 Fogelholm R, Kivalo L, Bergström L: The transient global amnesia syndrome. *Eur Neurol* 1975;13:72–84.
- 10 Rowan AJ, Protass LM: Transient global amnesia: clinical and EEG findings in 10 cases. *Neurology* 1979;29:869–872.
- 11 Shuping JR, Rollinson RD, Toole JF: Transient global amnesia. *Ann Neurol* 1980;7:281–285.
- 12 Jensen TS, Olivarius BDF: Transient global amnesia – its clinical and pathophysiological basis and prognosis. *Acta Neurol Scand* 1981;63:220–230.
- 13 Ladurner G, Skvarc A, Sager WD: Computer tomography in transient global amnesia. *Eur Neurol* 1982;21:34–40.
- 14 Cattaino G, Querin F, Pomes A, et al: Transient global amnesia. *Acta Neurol Scand* 1984;70:385–390.
- 15 Mumenthaler M, Treig T: Amnestische Episoden. Analyse von 111 eigenen Beobachtungen. *Schweiz Med Wochenschr* 1984; 114:1163–1170.
- 16 Kushner MJ, Hauser WA: Transient global amnesia. A case control study. *Ann Neurol* 1985;18:684–691.
- 17 Matthew NT, Meyer JS: Pathogenesis and natural history of transient global amnesia. *Stroke* 1974;5:303–311.
- 18 Jensen TS, Olivarius BDF: Transient global amnesia as a manifestation of transient cerebral ischemia. *Acta Neurol Scand* 1980;61:115–124.
- 19 Ahmed I: Transient global amnesia. Report of a case secondary to bilateral middle cerebral artery involvement. *J Kansas Med Soc* 1978;79:67–672.
- 20 Landi G, Giusti MC, Guidotti M: Transient global amnesia due to left temporal haemorrhage. *J Neurol Neurosurg Psychiatry* 1982;45:1062–1063.
- 21 Matias-Guiu J, Colomer R, Segura A, et al: Cranial CT scan in transient global amnesia. *Acta Neurol Scand* 1986;73:298–301.
- 22 Aimard G, Trilet M, Perrondon C, et al: Ictus amnésique d'un glioblastome intéressant le trigone. *Rev Neurol* 1971;124:392–396.
- 23 Hartley TC, Heilman KM, Garcia-Bengochea F: A case of transient global amnesia due to a pituitary tumor. *Neurology* 1974; 24:998–1000.
- 24 Boudin G, Pépin B, Mikol J, et al: Gliome du système limbique postérieur, révélé par une amnésie globale transitoire. Observation anatomo-clinique d'un cas. *Rev Neurol* 1975;31:157–163.
- 25 Ziegler DK, Kaufman A, Marshall HE: Abrupt memory loss

- associated with thalamic tumor. *Arch Neurol* 1977;34:545-548.
- 26 Lisak RP, Zimmerman RA: Transient global amnesia due to a dominant hemisphere tumor. *Arch Neurol* 1977;34:317-318.
 - 27 Shuping JR, Toole JF, Alexaner E Jr: Transient global amnesia due to glioma in the dominant hemisphere. *Neurology* 1980;30:88-90.
 - 28 Ross R: Transient tumor attacks. *Arch Neurol* 1983;40:633-636.
 - 29 Findler G, Feinsod M, Lijovetsky G, et al: Transient global amnesia associated with a single metastasis in the non-dominant lobe. *J Neurosurg* 1983;58:303-305.
 - 30 Riva C, Leiva C, Gobernado JM, et al: Amnesia global transitoria asociada a un meningioma del lobulo frontal. *Med Clin (Barc)* 1985;84:81.
 - 31 Meador KJ, Adams RJ, Flanigin HF: Transient global amnesia and meningioma. *Neurology* 1985;35:769-771.
 - 32 Collins MP, Freeman JW: Meningioma and transient global amnesia. Another report. *Neurology* 1986;36:594.
 - 33 Caplan LR: Transient global amnesia. Criteria and classification. *Neurology* 1986;36:441.
 - 34 Batterie d'examens neuropsychologiques. Lausanne, Centre Hospitalier Universitaire Vaudois, 1985.
 - 35 Chatham PE, Brillman J.: Transient global amnesia associated with bilateral subdural hematomas. *Neurosurgery* 1985;17:971-973.
 - 36 Jackson AC, Boughner DR, Botton CF, et al: Transient global amnesia associated with mitral valve prolapse. *Neurology* 1985;35 (suppl 1):215.
 - 37 Steinmetz EF, Vroom FQ: Transient global amnesia. *Neurology* 1972;22:1193-1200.
 - 38 Greenlee JE, Crampton RS, Miller JQ: Transient global amnesia associated with cardiac arrhythmia and digitalis intoxication. *Stroke* 1975;6:513-516.
 - 39 Kadota E, Irino T, Nishide M, et al: Pathological findings in an autopsied case of transient global amnesia. *No To Shinkei* 1981;33:399-406.
 - 40 Gilbert JJ, Benson DF: Transient global amnesia: Report of two cases with definite etiologies. *J Nerv Ment Dis* 1972;154:461-464.
 - 41 Olivarius BDF, Jensen TS: Transient global amnesia in migraine. *Headache* 1979;19:335-338.
 - 42 Caplan L, Chedru F, Lhermitte F, et al: Transient global amnesia and migraine. *Neurology* 1981;31:1167-1170.
 - 43 Crowell GF, Stump DA, Biller J, et al: The transient global amnesia-migraine connection. *Arch Neurol* 1984;41:75-79.
 - 44 Bolwig TG: Transient global amnesia. *Acta Neurol Scand* 1968;44:101-106.
 - 45 Rimpl E, Rimpl H.: Recurrent transient global amnesia in a case with cerebrovascular lesions and livedo reticularis (Sneddon syndrome). *J Neurol* 1979;221:127-131.
 - 46 Hauge T.: Catheter vertebral angiography. *Acta Radiol* 1954;109 (suppl):1-219.
 - 47 Shuttleworth EO, Wise GR: Transient global amnesia due to arterial embolism. *Arch Neurol* 1973;29:340-342.
 - 48 Cochran JW, Morrell F, Huckman MS, et al: Transient global amnesia after cerebral angiography. *Arch Neurol* 1982;39:593-594.
 - 49 Wales LR, Nov AA: Transient global amnesia: Complication of cerebral angiography. *AJNR* 1981;2:275-277.
 - 50 Longridge NS, Hachinski V, Barber HO: Brain stem dysfunction in transient global amnesia. *Stroke* 1979;10:473-474.
 - 51 Hinge HH, Jensen TS, Kjaer M, et al: The prognosis of transient global amnesia. Results of a multicenter study. *Arch Neurol* 1986;43:673-676.
 - 52 Miller JW, Petersen RC, Metter EJ, et al: Transient global amnesia: Clinical characteristics and prognosis. *Neurology* 1987;37:733-737.

Received: March 2, 1987

Accepted: August 24, 1987

J. Bogousslavsky, MD
 Service de Neurologie
 Centre Hospitalier Universitaire Vaudois
 CH-1011 Lausanne (Switzerland)