

Coronavirus Disease-19 (COVID-19) Related Acute Stroke Causing Transient Global Amnesia

Ramnath Santosh Ramanathan, MD,* and Ari Wachsman, MD†

Key Words: TGA (transient global amnesia)—Coronavirus disease-2019 (COVID-19)—Severe acute respiratory syndrome coronavirus 2 (SARS-CoV-2)—Stroke
© 2021 Elsevier Inc. All rights reserved.

Introduction

Transient global amnesia (TGA) presents as an acute anterograde amnesia that generally resolves within 24 h.¹ Werner et al. had noted increasing TGA since severe acute respiratory syndrome coronavirus 2 (SARS-CoV-2) outbreak in their hospital in Germany and reported 16 patients with TGA between February 1st and May 15th 2020 compared to their 10-year average of 9.7.² In our series we noted 2 patients who presented with TGA secondary to acute hippocampal stroke in COVID-19 positive patients.

There is evidence that SARS-CoV-2 causes more thrombotic vascular events like stroke than other coronavirus infections. The reported incidence of stroke in SARS-CoV-2 ranges from 1% to 6%.³

Case 1

48-year female with medical history of hypertension admitted with amnesia and confusion, found to be COVID-19 positive on admission. The patient was found on her couch confused and perseverative. Patient's amnesic symptoms improved within 24 hrs. of admission but patient continued to be amnesic to the events around her admission. Vitals were stable except BP at 155/102 mmHg. Patient had normal neurological examination. MRI brain (Fig. 1) done showed small acute bilateral medial temporal infarcts. EEG did not show any seizure activity. D-dimer was reported normal.

From the *Attending Neurohospitalist, Vascular Neurology, Aultman Hospital, NEOMED, 2600 6th St SW, Canton, OH 44710, United States; and †Metro Health System, Cleveland, United States.

Received January 22, 2021; revision received February 20, 2021; accepted February 28, 2021.

Address correspondence to Ramnath Santosh Ramanathan, MD, Attending Neurohospitalist, Vascular Neurology, Aultman Hospital, Assistant Professor NEOMED, 2600 6th St SW, Canton, OH 44710, United States. E-mail: dr.santosh7@gmail.com.

1052-3057/\$ - see front matter

© 2021 Elsevier Inc. All rights reserved.

<https://doi.org/10.1016/j.jstrokecerebrovasdis.2021.105738>

Case 2

71-year female with medical history of hypertension was admitted with amnesia, found to be COVID-19 positive. COVID-19 testing was done due to recent exposure. Patient was amnesic to the events that occurred leading to her admission, and kept repeating herself. Patient's symptoms resolved in about 8 hours following admission but patient continued to have amnesia to the events around her hospitalization. Vitals were stable on admission except for high BP of 173/100 mmHg on admission. Patient had normal neurological examination. Electroencephalogram (EEG) did not show any seizure activity or epileptiform discharges. MRI brain (Fig. 2) showed acute small right medial temporal infarct. MR angiogram head/neck did not show any acute large vessel occlusion. D-dimer was slightly on higher side at 315.

Discussion

The estimated incidence of TGA is around 5.2–10 per 100,000 per year.⁴ The etiology of TGA is not clear but multiple theories have been postulated which includes a possible vascular etiology, epilepsy, migraine like episode with cortical spreading depression or underlying psychogenic disorder.⁵ Involvement of mediobasal temporal lobe and/or hippocampus leads to the clinical symptoms of TGA. The hallmark of TGA is prominent anterograde amnesia, characterized by an inability to form new memories. Patients generally perseverate, and repetitively ask the same questions, as well as are disoriented in time. The neurological examination is generally normal and patient needs to be observed till atleast the amnesia resolves. In our 2 cases, patients had TGA symptoms, with tiny stroke in the medial temporal lobe, and were COVID-19 positive. In COVID-19 the mechanism of stroke has been secondary to viral endothelial injury in form of endothelitis and endotheliopathy, hypercoagulable state from systemic inflammation, and cytokine storm.⁶ Axonal transport of SARS-CoV-2 to the olfactory bulb via cribriform plate may result in loss of smell experienced with COVID-19

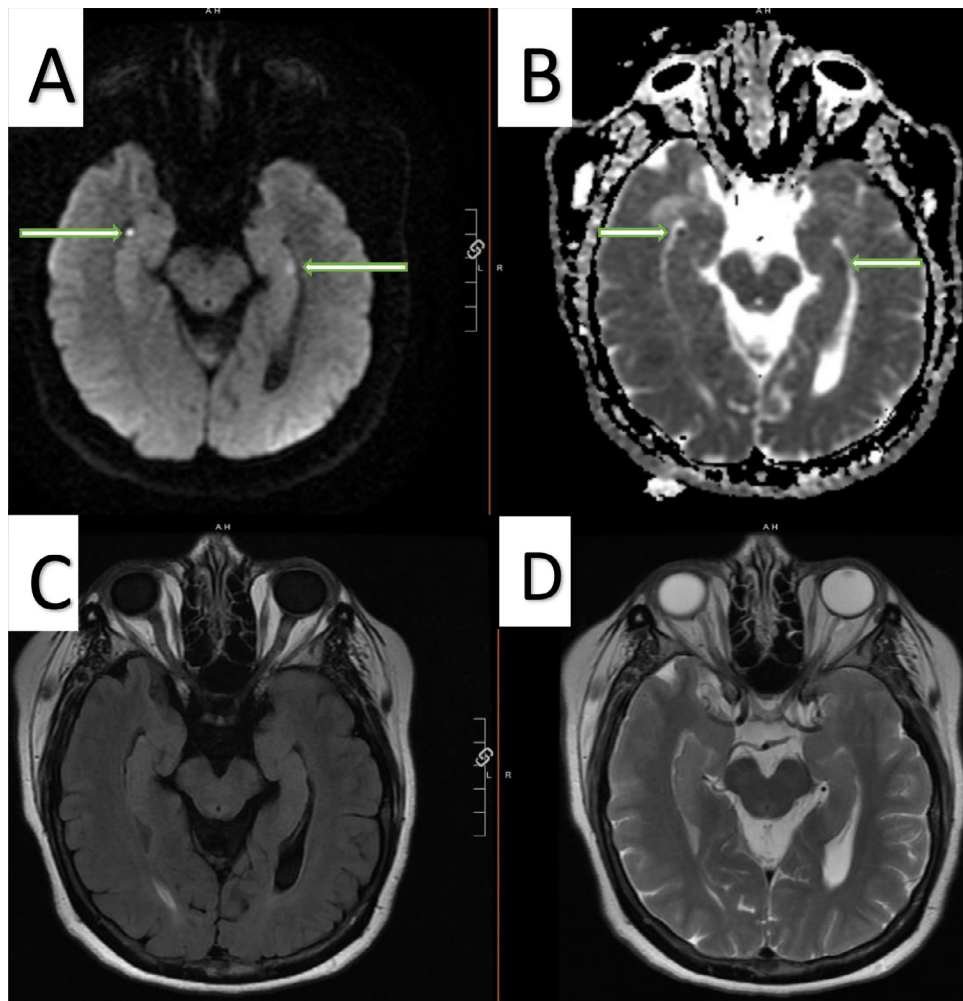


Fig. 1. MRI Brain without contrast (A) diffusion weighted images (DWI) showing restricted diffusion in the bilateral medial temporal lobes (arrows) along with corresponding (B) apparent diffusion coefficient (ADC) images- (arrows), (C) fluid attenuated inversion recovery (FLAIR) and (D) T2 sequence.

infections. COVID-19 associated coagulopathy could be related to inflammatory cytokine storm. Viral spike glycoprotein binds to angiotensin converting enzyme 2 (ACE2) resulting in ACE2 downregulation, which in turn overactivate classical renin angiotensin system (RAS) and underactivate the alternative RAS signal in the brain, ultimately resulting in cascade of inflammation and coagulopathy leading to stroke in COVID-19 infection.⁷ Various neurological manifestation has been reported in COVID-19 patients, including stroke, encephalopathy, encephalitis, headache, dizziness, loss of smell and taste, seizures, refractory status epilepticus, acute disseminated encephalomyelitis (ADEM), myelitis, leukoencephalopathy, neuroleptic malignant syndrome, Kawasaki syndrome, Guillain-Barré syndrome, myopathy, as well as critical illness neuromyopathy.⁸ But there has not been much literature about TGA in COVID-19 patients. Werner et al's report which mentions about possible increase in TGA in their hospital during COVID-19 pandemic but these patients did not show any COVID-19 symptoms. It is likely possible that high stress level in the community

during these unprecedented pandemics of COVID-19 might trigger TGA. Hussein et al reported TGA as neurological prodrome to respiratory failure in a COVID-19 patient.⁹ In that case Hussein et al described a 53-year-old patient who was admitted with TGA symptoms and a week later was admitted to the hospital with acute respiratory and systemic symptoms of COVID-19. No structural damage in MRI brain was reported in that case. And in that case author was not clear if association of TGA prodrome was secondary to stress of developing infection or was just coincidental. Nishizawa et al reported a case of TGA with bilateral hippocampal lesions during the COVID 19 crisis but again in their case patient was not found to be COVID-19 positive and TGA was attributed to the stress of the current ongoing pandemic.¹⁰ But in our cases TGA occurred in patients who were positive for COVID-19, had cough for about a week, and developed TGA symptoms along with structural damage suggesting acute strokes in MRI brain. Ours is the first report of 2 patients of TGA in COVID-19 positive patients with stroke. One of our patients had small acute bilateral

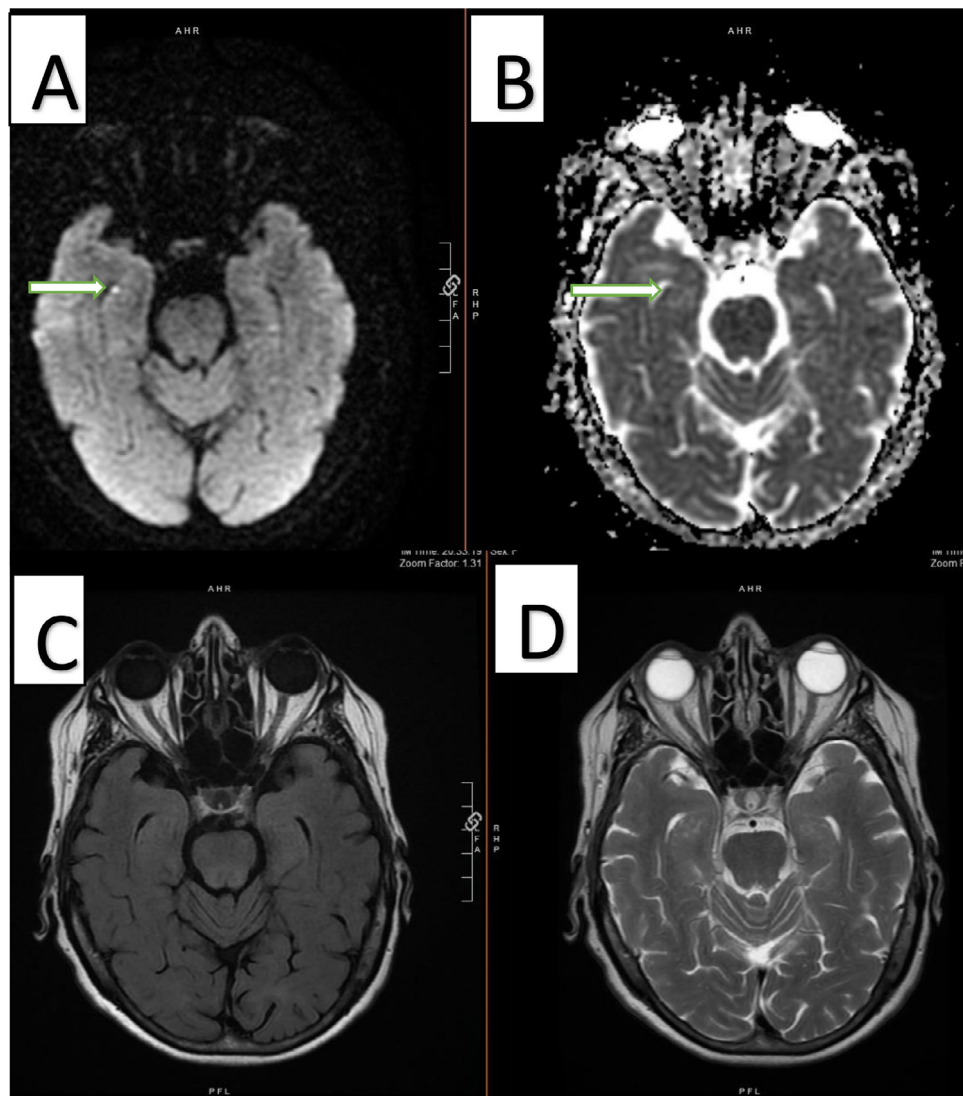


Fig. 2. MRI Brain without contrast (A) DWI showing restriction in the right medial temporal lobe along with corresponding ADC (B) images (arrows), (C) FLAIR and (D) T2 sequence.

medial temporal lobe strokes while the other had right medial temporal lobe acute infarct. We hypothesize that COVID-19 resulted in thrombotic vascular events in the medial temporal regions leading to TGA rather than TGA being caused by the stress of the ongoing pandemic as reported in other couple cases. TGA needs to be added to the ever-growing repertoire of varied neurological manifestations of COVID-19.

Conclusion

TGA could be the initial manifestation of COVID-19 in certain cases and more reporting is needed to see pathogenesis and characteristic neuroimaging findings in these patients.

Declaration of Competing Interest

None.

References

1. Quinette P, Guillery-Girard B, Dayan J, et al. What does transient global amnesia really mean? Review of the literature and thorough study of 142 cases. *Brain* 2006;129:1640.
2. Werner R, Keller M, Woehrle JC. Increased incidence of transient global amnesia during the Covid-19 crisis? *Neurol Res Pract* 2020;2:26.
3. Yaghi S, Ishida K, Torres J, et al. SARS-CoV-2 and stroke in a New York healthcare system. *Stroke* 2020;51:2002-2011.
4. Miller JW, Petersen RC, Metter EJ, et al. Transient global amnesia: clinical characteristics and prognosis. *Neurology* 1987;37:733.
5. Szabo K. Transient global amnesia. *Front Neurol Neurosci* 2014;34:143-149.
6. Ellul MA, Benjamin L, Singh B, et al. Neurological associations of COVID-19. *Lancet Neurol* 2020;19:767-783.
7. Divani AA, Andalib S, Napoli MD, et al. Coronavirus disease 2019 and stroke: clinical manifestations and

- pathophysiological insights. *J Stroke Cerebrovasc Dis* 2020;29:104941.
8. Divani AA, Andalib S, Biller J, et al. Central nervous system manifestations associated with COVID-19. *Curr Neurol Neurosci Rep* 2020;20:60.
 9. Hussein HM. Transient global amnesia as a possible first manifestation of COVID-19. *Neurohospitalist* 2021;11:84-86.
 10. Nishizawa T, Kawakami A, Taguchi T, et al. Transient global amnesia with bilateral hippocampal lesions during the COVID-19 global outbreak. *J Gen Fam Med* 2020;00:1-2.