

Amnesia Following Thalamic Hemorrhage

Another Stroke Syndrome

Graeme J. Hankey, MBBS, and Edward G. Stewart-Wynne, MBChB, FCP(SA), FRACP

The clinical manifestations of thalamic hemorrhage frequently comprise hemiparesis, hemianesthesia, and oculomotor abnormalities. Since the advent of computed tomography, an amnesic syndrome following thalamic hemorrhage has been recognized, but the thalamic structures involved and the mechanism of amnesia have remained uncertain. We report a patient with sudden memory dysfunction following hemorrhage into the anterior nucleus of the left thalamus that was shown neuropathologically to disrupt the mamillothalamic fasciculus, one of the principal components of the limbic system. It is considered that the amnesic syndrome following thalamic (anterior nucleus) hemorrhage is due to interruption of the mamillothalamic fasciculus. (*Stroke* 1988;19:776-778)

Since the introduction of computed tomography (CT), several new clinical syndromes have been identified in association with intracranial hemorrhage.¹ The clinical spectrum of subcortical lobar, ganglionic, brainstem, and cerebellar hemorrhages has widened, but the clinical-CT correlation of thalamic hemorrhages has received little attention.²⁻⁶ A recent study of 50 patients with thalamic hemorrhages⁶ reflects previous experience^{2-5,7} and emphasizes the frequent occurrence of hemiparesis, hemianesthesia, and oculomotor findings (upward gaze palsy with miotic, poorly reactive pupils) as the result of lateral or inferomedial pressure/extension, respectively.

An amnesic syndrome following thalamic hemorrhage has been recently described in four cases,^{8,9} but only clinical-CT correlation was available. Although amnesia has been associated with thalamic tumor¹⁰ and unilateral infarction of the dorsomedial nucleus of the thalamus,¹¹⁻¹³ the neuroanatomic explanation for amnesia following thalamic hemorrhage remains uncertain.

We describe a patient with the abrupt onset of memory loss following hemorrhage into the anterior nucleus of the thalamus. Neuropathologic examination revealed disruption of the mamillothalamic fasciculus. It is considered that memory dysfunction in this case resulted from interruption of the mamillothalamic fasciculus in the anterior thalamic nucleus.

Case Report

A 56-year-old man had the sudden onset of memory disturbance. During the preceding 2 weeks he had been attending a physical fitness program, which included a 9-minute treadmill test. His blood pressure before the test was 130/80 mm Hg and his heart rate reached 130 beats/min without symptoms. The day after this workout he developed a vague headache and impaired

memory. He smoked 20 cigarettes per day and was in good health.

Examination revealed a mildly febrile (temperature 37.5° C) man whose heart rate was 56 beats/min and regular with blood pressure of 140/90 mm Hg. Routine bedside mental function testing showed errors in orientation, in immediate and 5-minute recall, and in calculation. Results of standard psychometric tests indicated above-average intellectual ability. On the Weschler Adult Intelligence Test his verbal IQ was 111, performance IQ 108, and full-scale IQ 110. No obvious verbal performance discrepancy was present, but administration of the Weschler Memory Scale yielded a memory quotient below normal and impaired ability for new verbal learning. The Benton Visual Retention Test score was also below normal. His neurologic examination was otherwise normal. No neck stiffness was present.

Investigations revealed a normal blood count, urea and electrolytes, plasma glucose, electrocardiogram, electroencephalogram, and skull x-rays. The erythrocyte sedimentation rate was 24 mm/hr.

Unenhanced cranial CT scan revealed an area of high density, consistent with hemorrhage, in the anteromedial aspect of the left thalamus, with extension into the frontal horn of the left lateral ventricle and the third ventricle (Figure 1). CT scan with contrast showed no contrast enhancement. Bilateral selective internal and left vertebral angiograms were normal.

The patient was managed conservatively, and his memory disturbance gradually improved over the subsequent 6 days. A repeat cranial CT scan on Day 7 showed significant resolution of the high-density hemorrhage in the thalamus, third ventricle, and frontal horn of the left lateral ventricle.

On Day 14, he developed a fever (temperature 39.2° C) due to an *Escherichia coli* urinary tract infection. His conscious state became depressed, and a cranial CT scan revealed acute hydrocephalus. An intraventricular drain was inserted through a right frontoparietal burr hole. Ventricular fluid examination showed changes of florid ventriculitis, and abundant *E. coli* organisms were cultured. He died the following day without regaining consciousness.

From the Department of Neurology, Royal Perth Hospital, Perth, Australia.

Address for correspondence: Dr. Edward G. Stewart-Wynne, Neurologist, Department of Neurology, Royal Perth Hospital, GPO Box X2213, Perth, Western Australia 6001, Australia.

Received August 25, 1987; accepted December 1, 1987.

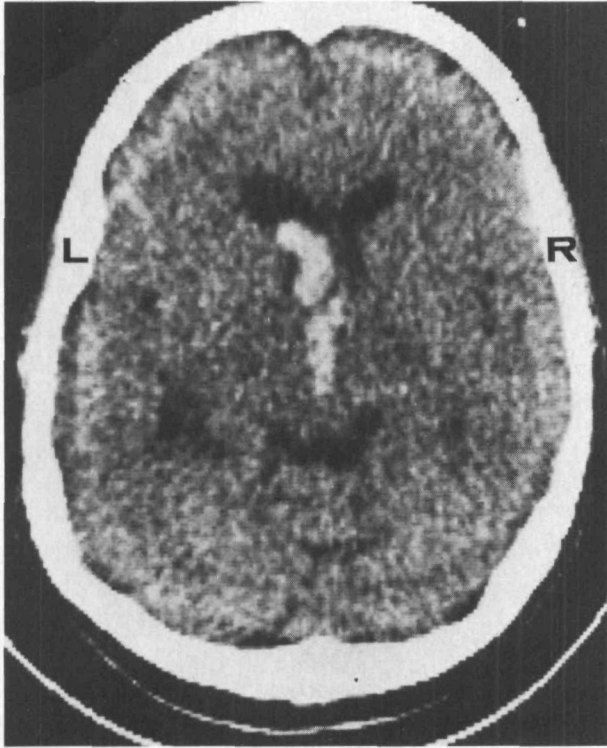


FIGURE 1. Unenhanced cranial computed tomogram (CT scan) showing high-attenuation areas, consistent with hemorrhage, in third ventricle and frontal horn of left lateral ventricle.

Postmortem examination was limited to the intracranial contents. Examination of the brain revealed exudates on the inner surface of the dura mater. The leptomeninges were thickened and covered with a thick layer of purulent exudate. The cortical veins overlying the cerebral hemispheres and the sagittal sinus were

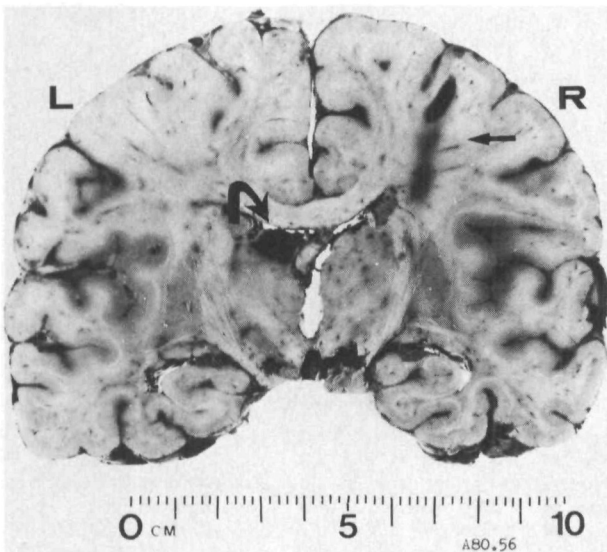


FIGURE 2. Coronal section of brain, immediately anterior to mamillary bodies, showing circumscribed 1-cm-diameter hematoma (curved arrow) in anteromedial and superior aspect of left thalamus and lateral wall of left lateral ventricle. Site of intraventricular drain inserted through right frontoparietal burr hole is shown (straight arrow).

thrombosed. The blood vessels at the base of the brain were of normal architectural pattern with minimal atherosclerosis. Uncal grooving was present bilaterally.

One-centimeter-thick coronal slices of the brain showed a markedly edematous cerebral cortex. At the coronal level of the mamillary bodies, a circumscribed hematoma measuring 1 cm in diameter horizontally and vertically and 2 cm in diameter anteroposteriorly was present in the center of the lateral wall of the left lateral ventricle and in the anterior nucleus of the thalamus, at the termination of the mamillothalamic fasciculus (Figures 2 and 3). The ependymal surface overlying the hematoma had been breached, and yellow-brown blood clot was seen within both anterior horns of the lateral ventricles. There was no evidence of a vascular malformation in the vicinity of the hematoma.

Histologic examination of the hemorrhagic area revealed that the ependymal surface overlying the anteromedial thalamus was disrupted, allowing the hemorrhage to communicate with the lateral ventricle. Necrosis with foamy histiocytes and reactive astrocytes was present around the hemorrhage, suggesting that this lesion was at

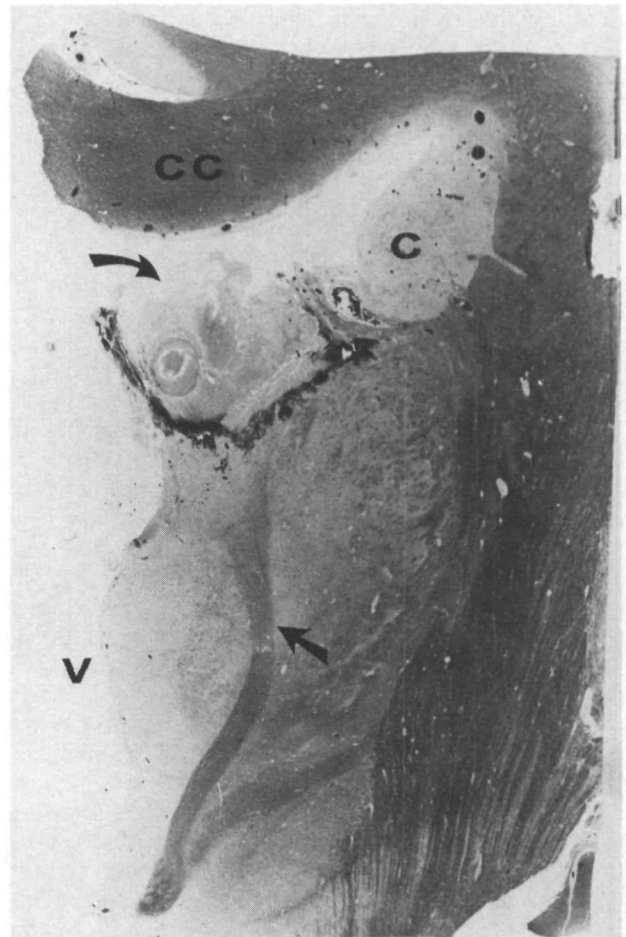


FIGURE 3. Microscopic appearance of coronal section of left thalamus, mamillary body, internal capsule, caudate nucleus (C), corpus callosum (CC), and third ventricle (V). Hemorrhage (curved arrow) extends from anterior nucleus of left thalamus, at termination of mamillothalamic tract (straight arrow), into left lateral ventricle (curved arrow).

least 1–2 weeks old. Very little hemosiderin was present, however. Acute purulent meningitis and subpial ventricular cerebritis was present. A polymorphonuclear neutrophil exudate was present, consistent with an infective process of 2–5 days' duration.

Microscopic examination of the intraparenchymal blood vessels throughout the brain was normal.

Discussion

Thalamic hemorrhage represents 10–15% of intraparenchymal cerebral hemorrhages.¹⁴ The spectrum of clinical presentation reflects the location, size, and pattern of extension of the hematoma. Lateral extension into the internal capsule frequently results in hemiparesis and hemianesthesia. If the lateral geniculate body is involved, a transient homonymous hemianopia occurs.¹⁴ If the dominant hemisphere is affected, aphasia may be seen,¹⁵ and mutism, amorphosynthesis, and contralateral neglect have been reported following nondominant thalamic hemorrhage.¹⁶ Inferomedial extension into the subthalamus and dorsal midbrain affects oculomotor function. The most characteristic defect is one of upward gaze with miotic, unreactive pupils. Other oculomotor signs include convergence paralysis, nystagmus retractorius on attempted upward gaze, skew deviation with downward and medial displacement of the contralateral eye, ipsilateral ptosis and miosis, forced deviation of the eyes downward, and transient opsoclonus.^{14,16} Medial extension into either the atrium of the lateral ventricle or the third ventricle has been recognized on CT to occur in one half to two thirds of thalamic hemorrhages,^{2,3,6} resulting in a high frequency (approximately 25%) of hydrocephalus.^{2,3}

Although a thalamic hemorrhage lying medially with extension into the subthalamus can often be distinguished clinically from one located laterally, the clinical presentation of anteromedial thalamic hemorrhage with intraventricular extension is not so clearly documented. The relatively sudden onset of memory disturbance in this case after an intensive period of physical exertion and headache was consistent with a vascular event, which was confirmed by cranial CT scan and autopsy examination. The patient's subsequent clinical course was complicated by a urinary tract infection from which he became septicemic. It is speculated that the intraventricular blood may have acted as a nidus for the infection to localize to the ventricular system.

Two thalamic structures have been implicated in memory functions: the anterior nucleus and mamillothalamic tract^{17,18} and the mediodorsal nucleus and internal medullary lamina.¹⁹ The mamillothalamic fasciculus (bundle of Vicq D'Azyr) establishes reciprocal connections between the mamillary bodies and the anterior thalamic nuclei, which in turn projects into the cingulum. It is one of the principal fiber bundles of the limbic system, which has a significant role in memory. The pathologic data from this case clearly illustrates hemorrhage into the anterior nucleus of the thalamus, involving the mamillothalamic fasciculus, with intraventricular extension.

The purpose of our report is to increase awareness of

another hemorrhagic stroke syndrome: amnesia following thalamic (anterior nucleus) hemorrhage with intraventricular extension, which can be suspected clinically and confirmed by unenhanced CT scan. The probable role of the anterior nucleus of the thalamus and its connections with the mamillary bodies via the mamillothalamic fasciculus in memory function is also highlighted.

Acknowledgments

We wish to thank Dr. C.G. Harper, neuropathologist, for performing the neuropathological examination of the brain and Dr. E.P. Richardson for his helpful comments. The illustrations were provided by Mr. R. Timm and the Department of Medical Illustration, Royal Perth Hospital. Secretarial assistance was given by Mrs. Carolyn Beasley and Maree Charteris.

References

1. Weisberg LA: Computed tomography in intracranial haemorrhage. *Arch Neurol* 1979;363:422–426
2. Walshe TM, Davis KR, Fisher CM: Thalamic haemorrhage: A computed tomographic-clinical correlation. *Neurology (Minneapolis)* 1977;27:217–222
3. Barraquer-Bordas L, Illa I, Escartin A, Rusalleda J, Marti-Vilalta JL: Thalamic haemorrhage: A study of 23 patients with diagnosis by CT. *Stroke* 1981;12:524–527
4. Piepgras U, Rieger P: Thalamic bleeding. *Neuroradiology* 1981;22:85–91
5. Hirose G, Kosogawa H, Sacki M, Kitagawa Y, Oda R, Kanda S, Matsuura T: The syndrome of posterior thalamic haemorrhage. *Neurology* 1985;35:998–1002
6. Weisberg LA: Thalamic haemorrhage: Clinical-CT correlations. *Neurology* 1986;36:1382–1386
7. Fisher CM: The pathologic and clinical aspects of thalamic haemorrhage. *Trans Am Neurol Assoc* 1959;84:56–59
8. Choi D, Sudarsky L, Schachter S, Biber M, Burke P: Medial thalamic haemorrhage with amnesia. *Arch Neurol* 1983;40:611–613
9. Tsoi MM, Huang CY, Lee AOM, Yu YL: Amnesia following right thalamic haemorrhage, in Eadie MJ, Lander CM (eds): *Clinical and Experimental Neurology*. Sydney, Australia, Williams and Wilkins & Associates Pty Ltd, 1987, vol 23, pp 201–207
10. Ziegler DK, Kaufman A, Marshall HE: Abrupt memory loss associated with thalamic tumour. *Arch Neurol* 1977;34:545–548
11. Speedie LJ, Heilman KM: Amnesic disturbances following infarction of the left dorsomedial nucleus of the thalamus. *Neuropsychologia* 1982;20:597–604
12. Speedie LJ, Heilman KM: Anterograde memory deficits for visuo-spatial material after infarction of the right thalamus. *Arch Neurol* 1983;40:183–186
13. Squire LR, Moore RY: Dorsal thalamic lesion in a noted case of human memory dysfunction. *Ann Neurol* 1979;6:503–506
14. Kase CS, Mohr JP: Supratentorial intracerebral haemorrhage, in Barnett HJM, Mohr JP, Stein BM, Yatsu FM (eds): *Stroke—Pathophysiology, Diagnosis and Management*. New York, Churchill Livingstone, 1986, vol 1, ch 28, pp 534–539
15. Ciemens VA: Localised thalamic haemorrhage. A cause of aphasia. *Neurology* 1980;20:776–782
16. Adams RD, Victor M: *Principles of Neurology*, ed 3. New York, McGraw-Hill Book Co, 1985
17. Castaigne P, Lhermitte F, Buge A, Escourolle R, Hauw JJ, Lyon-Caen O: Paramedian thalamic and midbrain infarcts: Clinical and neuropathological study. *Ann Neurol* 1981;10:127–148
18. Schott B, Mauguier F, Laurent B, Sercler O, Fisher C: L'amnesia thalamique. *Rev Neurol (Paris)* 1980;136:117–130
19. Victor M, Adams RD, Collins GH: *The Wernicke-Korsakoff Syndrome*, (vol 7, *Contemporary Neurology Series*). Philadelphia, FA Davis Co, 1971

KEY WORDS • cerebral hemorrhage • cerebrovascular disorders • thalamus • amnesia