





SHORT COMMUNICATION

Delayed recurrent enhancing white matter lesions complicating coiling of intracranial aneurysm

Eleni Bakola¹ | Aristeidis H. Katsanos^{1,2}  | Lina Palaiodimou¹ | Aikaterini Theodorou¹ | Maria-Ioanna Stefanou¹  | Maria Chondrogianni¹ | Elisabeth Andreadou³ | Marianna Papadopoulou^{1,4} | Vasileios Konstantakos¹  | Konstantinos Voumvourakis¹ | Stefanos Lachanis⁵ | Georgios Tsivgoulis^{1,6} 

¹Second Department of Neurology, School of Medicine, "Attikon" University Hospital, National and Kapodistrian University of Athens, Athens, Greece

²Division of Neurology, McMaster University/Population Health Research Institute, Hamilton, ON, Canada

³First Department of Neurology, Aeginition Hospital, National and Kapodistrian University of Athens, Athens, Greece

⁴Department of Physiotherapy, University of West Attica, Athens, Greece

⁵Iatropolis Magnetic Resonance Diagnostic Centre, Athens, Greece

⁶Department of Neurology, The University of Tennessee Health Science Center, Memphis, TN, USA

Correspondence

Georgios Tsivgoulis, Second Department of Neurology, University of Athens, School of Medicine, Rimini 1, Chaidari, Athens 12462, Greece.

Email: tsivgoulisgiorg@yahoo.gr

Abstract

Background and purpose: In recent years, the use of coiling has gained increased popularity for the treatment of intracranial aneurysms, and stroke physicians are confronted with rare pathologies associated with this relatively new and evolving treatment method, such as embolization of pieces of the polymeric filaments from the coils and a subsequent inflammatory response. In particular, white matter enhancing lesions are a rare complication after aneurysm endovascular therapy (EVT), suggesting a foreign body reaction to shedding of hydrophilic coating from the endovascular devices into the blood stream. The description of such a case aims to raise the clinicians' awareness of the symptomatic delayed and recurring inflammatory changes that may occur after endovascular aneurysmal treatment with the use of coiling devices.

Case description: A 64-year-old woman underwent coiling of a ruptured right posterior communicating artery aneurysm. She was asymptomatic after EVT. One year later, she presented with headache, acoustic hallucinations, paresthesias and left arm weakness. Brain magnetic resonance imaging (MRI) revealed multiple enhancing white matter lesions in the right hemisphere. She was treated with pulse intravenous methylprednisolone, followed by oral prednisolone; all clinical symptoms resolved and imaging findings improved substantially. Two years after tapering the steroids, follow-up symptoms recurred and repeat brain MRI revealed new enhancing white matter lesions.

Discussion and conclusions: There is an increasing number of similar reports of enhancing white matter lesions after coiling of intracranial aneurysms, with the incidence estimated to be between 0.5% and 2.3% in different cohort studies. Close monitoring for the appearance of new neurologic symptoms that could suggest delayed brain reactivity should be recommended.

KEYWORDS

coiling, enhancing white matter lesions, immune reaction, intracranial aneurysm, vasogenic edema

INTRODUCTION

In recent years, the standard of care for treatment of cerebral aneurysms has significantly shifted towards endovascular therapy (EVT) rather than open surgical approaches, and coiling has gained increased popularity [1]. Clinicians may be confronted with rare pathologies associated with this relatively new and ever-changing treatment modality, such as embolization of pieces of the polymeric filaments from coils, potentially causing delayed inflammatory response [2].

We present the case of a 64-year-old woman who developed symptomatic delayed and recurring vasogenic edema after coiling of a ruptured right posterior communicating artery aneurysm.

CASE REPORT

A 64-year-old woman presented in the emergency department with subacute-onset tension-type headache, acoustic hallucinations, paresthesias and weakness of the left arm. Medical history included non-traumatic subarachnoid hemorrhage 1 year previously, due to aneurysm rupture of the right posterior communicating artery, which was successfully treated by EVT, leaving no residual symptoms. The endovascular procedure was reported to be uneventful, with no complications. Also, platinum coils were used during the procedure (Figure 1a).

At the emergency department, brain computed tomography was conducted and revealed right temporoparietal hypodense lesions, which were mostly confined to the white matter (Figure 1b). An electroencephalogram was also performed, showing only focal slow-wave activity in the right temporoparietal area due to the underlying cerebral lesions, with no epileptiform discharges. Brain magnetic resonance imaging (MRI) confirmed temporoparietal white matter lesions in the right cerebral hemisphere, without restricted diffusion, indicating vasogenic edema (Figure 1c-d). Furthermore, susceptibility-weighted imaging (SWI) showed low-signal spots within the lesions, suggesting the presence of paramagnetic material, while post-gadolinium T1-weighted sequences demonstrated slight gadolinium enhancement of the lesions (Figure 1e,f).

For the differential diagnosis of vasogenic edema, blood and cerebral spinal fluid (CSF) laboratory examinations were performed, and these tested negative for electrolytic, infectious, neoplastic and autoimmune disorders. More specific immunological testing, such as anti-myelin oligodendrocyte glycoprotein serum antibody, oligoclonal bands and immunoglobulin G index in the CSF were also negative for any demyelinating disorders of the central nervous system, including acute disseminated encephalomyelitis. Furthermore, peroxisomal panel, arylsulfatase-A, very-long-chain fatty acids and paraneoplastic panel were normal. Primary central nervous system lymphoma was excluded, predominately on the basis of the

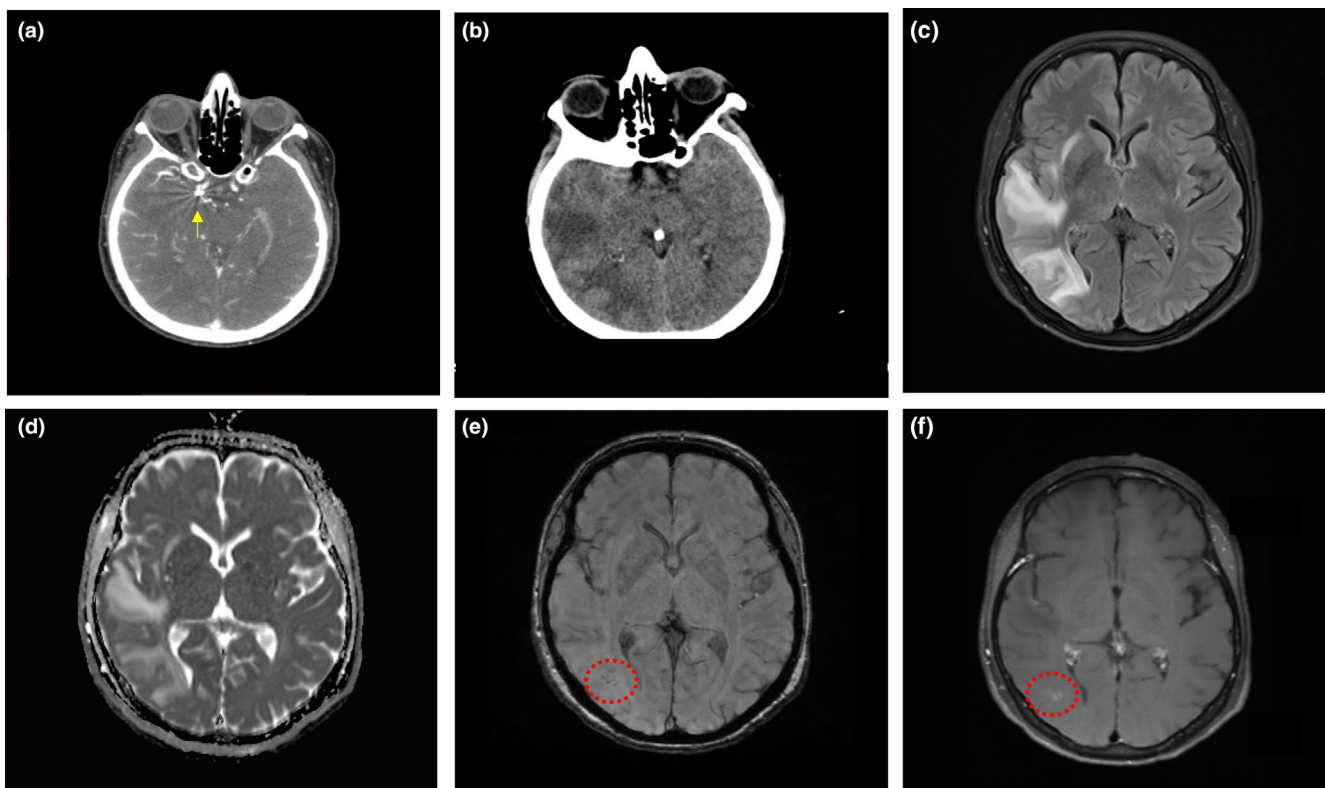


FIGURE 1 (a) Baseline computed tomography (CT) angiography showing coils in the right posterior communicating artery (arrow). (b) CT of brain demonstrating cerebral vasogenic edema. (c) Axial fluid-attenuated inversion recovery sequence showing diffuse white matter hyperintensities in the right parietal lobe without diffusion restriction on apparent diffusion coefficient maps (d). (e) Axial susceptibility-weighted imaging showing low-signal spots (dotted circle) within the lesions, suggesting the presence of paramagnetic material. (f) Axial T1-weighted image showing slight gadolinium enhancement of the lesions (dotted circle)

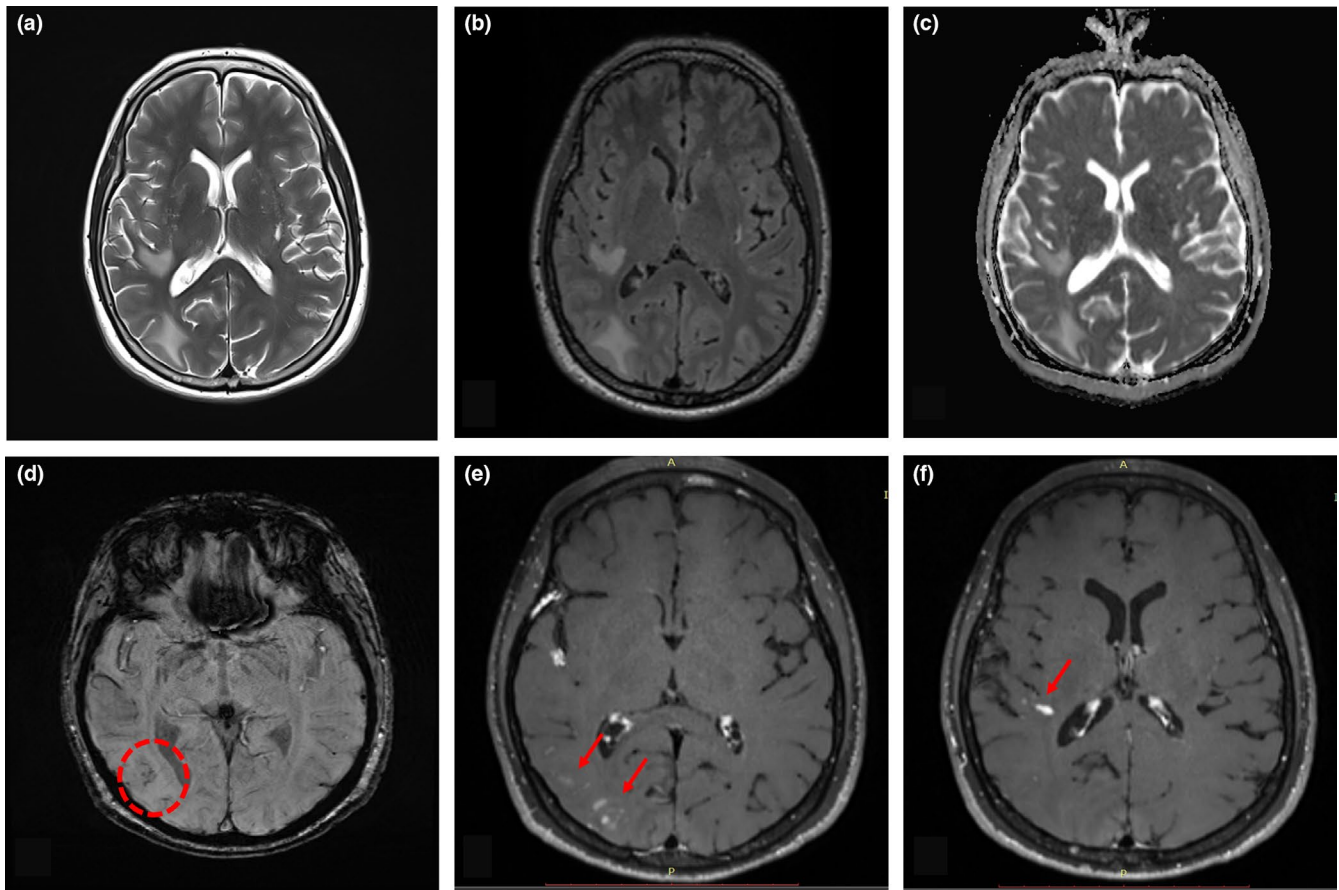


FIGURE 2 (a) Axial T2-weighted and (b) fluid-attenuated inversion recovery sequences showing reappearance of white matter hyperintensities in the right hemisphere without diffusion restriction on apparent diffusion coefficient maps (c) following corticosteroid tapering, 2 years after the patient's initial presentation. (d) Axial susceptibility-weighted imaging showing low-signal spots (dotted circle) within the lesions. (e) and (f) Axial T1-weighted images showing gadolinium enhancement of the new white matter lesions (arrows)

neuroimaging findings, since lymphoma appears as a homogeneously enhanced lesion with restricted diffusion on MRI. Additionally, cytology in CSF analysis was negative. Posterior reversible encephalopathy syndrome was also included in the differential diagnosis, but was considered highly unlikely due to atypical radiological features of the patient, since the white matter lesions were restricted in one hemisphere and no predisposing factors were present. Cerebral amyloid angiopathy-related inflammation (CAA-RI) was another debatable diagnosis for our case. However, both the white matter lesions and, more importantly, the low SWI signal spots, which could represent microbleeds in the case of CAA-RI, were restricted unilaterally, in contrast to the expected multifocal involvement in CAA-RI. The additional finding of the apolipoprotein E $\epsilon 3/\epsilon 3$ genotype in our patient also argued against CAA-RI diagnosis. Finally, the patient did not consent to undergo a brain biopsy, which would have offered more conclusive results for confirmation of the diagnosis of encephalopathy associated with immune reaction against coiling.

Based on the medical history and neuroimaging findings, the diagnosis of encephalopathy associated with immune reaction to coiling was finally speculated as an exclusion diagnosis and the patient was treated with steroid pulse therapy. An immediate treatment response with total improvement was noted and follow-up MRI at 30 days

confirmed a significant reduction of white matter lesions. However, 2 years after slowly tapering the steroids, the patient experienced a clinical relapse (headache, dysarthria, left upper arm tingling and weakness), and brain MRI demonstrated exacerbation of the vasogenic edema, coupled with new enhancing lesions and low-signal spots within the recurrent white matter lesions on SWI (Figure 2).

DISCUSSION

White matter enhancing lesions are a rare complication after aneurysm endovascular therapy suggesting a foreign body reaction due to shedding of hydrophilic coating from endovascular devices into the blood stream [2]. Over the last few years, there has been an increasing number of similar reports of enhancing white matter lesions following coiling of intracranial aneurysms (Table S1).

The incidence of immune-mediated leukoencephalopathy in patients treated with EVT for intracranial aneurysms was estimated to be between 0.5% and 2.3% in various cohort studies [3–5]. Interestingly, the vast majority of the cases were women, aged 41–65 years. This reaction was mostly observed several weeks after the EVT procedure with a maximum interval of 12 months, which was also noted in our

patient. Out of the 45 patients described in the literature so far, only four had undergone brain biopsy, which was characteristic in three cases, demonstrating granulomatous reaction surrounding foreign body materials [6,7]. The presumed pathophysiological mechanisms include granulation reaction caused by foreign body emboli from the hydrophilic coating of procedural devices, contrast-induced encephalopathy and nickel or bioactive polyglycolic/poly(lactic acid) coil sensitivity [4].

All published cases share common neuroimaging findings: T2-fluid-attenuated inversion recovery white matter hyperintensities, mostly at the distribution of the parenting vessel used for endovascular coiling, with patchy gadolinium enhancement. Scattered lesions with low SWI signal in the regions with white matter hyperintensities were also reported, as was the case in our patient [3,4,7]. Those lesions could represent microembolic paramagnetic materials from the coiling. Regarding treatment management, steroid pulse therapy, followed by oral prednisone resulted in significant clinical and neuroimaging improvement for the majority of patients. However, steroid dependency and clinical and radiological deterioration after steroid cessation are possible complications and highlight the need for prolonged immunosuppressive therapy [3,7,8].

In summary, clinicians should be aware of delayed brain reactivity following coiling of cerebral aneurysms, consider this complication as part of the differential diagnosis of vasogenic edema confined to one vascular territory, and monitor closely for the appearance of new neurologic symptoms. Finally, corticosteroid tapering may be associated with relapse of clinical symptoms and enhancing brain lesions.

ACKNOWLEDGMENTS

None.

CONFLICT OF INTEREST

None declared.

AUTHOR CONTRIBUTIONS

Eleni Bakola: Data curation (equal); Formal analysis (equal); Methodology (equal); Visualization (equal); Writing – original draft (equal). **Aristeidis H Katsanos:** Data curation (equal); Writing – review and editing (equal). **Lina Palaiodimou:** Visualization (equal); Writing – original draft (equal). **Aikaterini Theodorou:** Data curation (equal); Writing – review and editing (equal). **Maria Ioanna Stefanou:** Data curation (equal); Writing – review and editing (equal). **Maria Chondrogianni:** Investigation (equal); Writing – review and editing (equal). **Elisabeth Andreadou:** Investigation (equal); Writing – review and editing (equal). **Marianna Papadopoulou:** Investigation (equal); Writing – review and editing (equal). **Vasileios Konstantakos:** Investigation (equal); Writing – review and editing (equal). **Konstantinos I. Voumvourakis:** Supervision (equal); Writing – review and editing (equal). **Stefanos Lachanis:** Data curation (equal); Formal analysis (equal); Investigation (equal); Software (equal); Visualization (equal); Writing – review and editing (equal). **Georgios Tsvigoulis:** Conceptualization (equal); Data curation (equal); Formal analysis (equal); Investigation (equal); Methodology (equal); Supervision (equal); Visualization (equal); Writing – original draft (equal).

DATA AVAILABILITY STATEMENT

The data that support the findings of this study are available in the text.

ORCID

Aristeidis H. Katsanos  <https://orcid.org/0000-0002-6359-0023>
Maria-Ioanna Stefanou  <https://orcid.org/0000-0002-2305-6627>
Vasileios Konstantakos  <https://orcid.org/0000-0002-0332-7506>
Georgios Tsvigoulis  <https://orcid.org/0000-0002-0640-3797>

REFERENCES

1. Wang AS, Campos JK, Colby GP, Coon AL, Lin LM. Cerebral aneurysm treatment trends in National Inpatient Sample 2007–2016: endovascular therapies favored over surgery. *J Neurointerv Surg.* 2020;12(10):957-963. <https://doi.org/10.1136/neurintsurg-2019-015702>
2. Cruz JP, Marotta T, O'Kelly C, et al. Enhancing brain lesions after endovascular treatment of aneurysms. *AJNR Am J Neuroradiol.* 2014;35(10):1954-1958. <https://doi.org/10.3174/ajnr.A3976>
3. Shotar E, Law-Ye B, Baronnet-Chauvet F, et al. Non-ischemic cerebral enhancing lesions secondary to endovascular aneurysm therapy: nickel allergy or foreign body reaction? Case series and review of the literature. *Neuroradiology.* 2016;58(9):877-885. <https://doi.org/10.1007/s00234-016-1699-5>
4. Ikemura A, Ishibashi T, Otani K, et al. Delayed leukoencephalopathy: a rare complication after coiling of cerebral aneurysms. *AJNR Am J Neuroradiol.* 2020;41(2):286-292. <https://doi.org/10.3174/ajnr.A6386>
5. Nakagawa I, Park HS, Kotsugi M, et al. Delayed intracranial parenchymal changes after aneurysmal coil embolization procedures for unruptured intracranial aneurysms. *Oper Neurosurg (Hagerstown).* 2020;19(1):76-83. <https://doi.org/10.1093/ons/onz299>
6. Fealey ME, Edwards WD, Giannini C, Piepgras DG, Cloft H, Rihal CS. Complications of endovascular polymers associated with vascular introducer sheaths and metallic coils in 3 patients, with literature review. *Am J Surg Pathol.* 2008;32(9):1310-1316. <https://doi.org/10.1097/PAS.0b013e318165582a>
7. Shapiro M, Ollenschleger MD, Baccin C, et al. Foreign body emboli following cerebrovascular interventions: clinical, radiographic, and histopathologic features. *AJNR Am J Neuroradiol.* 2015;36(11):2121-2126. <https://doi.org/10.3174/ajnr.A4415>
8. Grewal SS, López Del Valle EM, Gupta V, Ramon N, Freeman WD, Tawk RG. Neurological changes with abnormal brain reactivity following coiling of cerebral aneurysm. Possible reactivity to endovascular devices and material? *J Vasc Interv Neurol.* 2015;8(3):28-36.

SUPPORTING INFORMATION

Additional supporting information may be found online in the Supporting Information section.

How to cite this article: Bakola E, Katsanos AH, Palaiodimou L, et al. Delayed recurrent enhancing white matter lesions complicating coiling of intracranial aneurysm. *Eur J Neurol.* 2021;00:1–4. <https://doi.org/10.1111/ene.14844>