

ing the red nucleus, within the mesencephalic tegmentum, the left inferior colliculus and the mammillary bodies." These findings were compatible with Wernicke's encephalopathy. Wallis *et al.*,⁶ described a case of Wernicke's encephalopathy with hypothermia being "akinetic and mute," only slightly reacting to nociceptive stimulation, forty hours after the start of thiamine therapy their patient was eating by himself and answering simple questions.

The anatomical lesions of Wernicke's encephalopathy involve the mammillary bodies symmetrically, and in various degrees the paraventricular regions of the thalamus and the hypothalamus, the periaqueductal region of the midbrain, the reticular formation of the midbrain, the inferior colliculi, the floor of the fourth ventricle and the superior vermis. The type and topography of these lesions may correspond well to the "tiny lesions of the posterior diencephalon and adjacent midbrain" held responsible for akinetic mutism."⁴

MW MANN

JD DEGOS

Department of Neurology,
CHU H. Mondor,
F-94010 Créteil, France

References

- 1 Cairns H, Oldfield RC, Pennybacker JB, Whitteridge D. Akinetic mutism with an epidermoid cyst of the 3rd ventricle. *Brain* 1941;64:273-90.
- 2 Fischbeck KH, Simon RP. Neurological manifestations of accidental hypothermia. *Ann Neurol* 1981;10:384-7.
- 3 Nielsen JM. Wernicke's encephalopathy. Correlation of sites of lesions with symptomatology. *J Nerv Ment Dis* 1953;118:429-34.
- 4 Plum F, Posner J. *Diagnosis of Stupor and Coma*. 3rd Ed. Philadelphia: FA Davis Company, 1982.
- 5 Victor M, Adams RD, Collins GH. *The Wernicke-Korsakoff-Syndrome*. Oxford: Blackwell Scientific Publications, 1971.
- 6 Wallis WE, Willoughby E, Baker P. Coma in the Wernicke-Korsakoff-syndrome. *Lancet* 1978;ii:400-1.
- 7 Wernicke C. *Lehrbuch der Gehirnkrankheiten fuer Aerzte und Studierende*. Berlin: Theodor-Fischer-Verlag, 1881;2:220-42.

Accepted 2 November 1987

Hemichorea and its denial in a case of caudate infarction diagnosed by magnetic resonance imaging

Sir: The possible cognitive functions of the basal ganglia have recently received consid-

erable attention,¹ but few case reports of cognitive deficits due to lesions localised to the basal ganglia have appeared in the literature. We report a case of denial of hemichorea in a patient with a discrete lesion in the head of the left caudate nucleus, which was diagnosed by magnetic resonance imaging (MRI).

A 51 year old right-handed man was admitted to Kawasaki Seitetsu Chiba Hospital (Chiba, Japan) on 22 September 1986, because of the sudden onset of right-sided involuntary movements 2 days previously. According to family members, the movements were not seen when the patient was asleep.

On admission, the patient was fully conscious and oriented, garrulous and seemingly happy. His wife said he had a forthright personality. Visual acuity and the visual fields on confrontation were normal; the pupils were equal and reacted normally to light. Extraocular movements were also normal. Other cranial nerve functions, limb muscle power, and muscle stretch reflexes were intact. There was some decrease of the tone of right-sided muscles and the plantar responses were flexor. Nearly continual distal choreic movements of the right arm and leg were observed without proximal ballistic movements. There was a slight decrease in pinprick sensation and vibration on the right leg but position and light touch sensations were normal. These sensory abnormalities disappeared rapidly within 3 days.

The patient was found to be totally unconcerned about the chorea. Although the involuntary movements made the playing of games, such as chess, impossible, he invited other patients to play and tried to undertake activities which were manifestly impossible. Moreover, when asked about his right limbs, he responded that they were fine or had recovered, despite the fact that violent involuntary movements were ongoing. In this respect, he showed clear signs of denial of the hemichorea.

Neither hemineglect (as determined by horizontal line bisection, copying pictures and Albert's line-crossing test) nor constructional apraxia (copying figures such as a diamond shape, a Greek cross and a cube) were found. There was no extinction on double simultaneous tactile and visual stimulation. Facial recognition, identification of overlapping figures (Poppelreuter), colour naming, limb and facial praxis to command, left-right discrimination, finger naming and simple verbal calculations were intact. His Wechsler Adult Intelligence Scale was at a normal level (Verbal IQ = 103, Performance IQ = 92 and Full Scale IQ = 110).

Computed tomography (CT) performed on 6 October 1986 (on the 17th day from onset) showed a small low density area in the head of the left caudate nucleus (approximately 4 cm rostral to the orbito-meatal line). The low density area did not extend to the posterior portion of the internal capsule or to the globus pallidus, and no other abnormalities were seen. Enhancement after contrast infusion in the region of the left caudate nucleus indicated recent infarction. Magnetic resonance imaging (Picker International Ltd., VISTR-MR) was performed with a 0.5 Tesla superconducting magnet using the inversion recovery technique (on 20 December, the 92nd day from onset). The width of the slice was 10 mm and the patient's head was positioned supine. Horizontal (fig a) and left lateral sagittal (fig b) images showed a small low intensity area in the head of the left caudate nucleus. There were no other abnormalities.

The course of the disease has been favourable. The patient was treated with haloperidol (0.75 mg, thrice daily) for three days, starting on 1 October, the 12th day from onset. The severity of the involuntary movements decreased and the haloperidol therapy was then stopped. The hemichorea gradually improved and had disappeared within six months. In contrast, the patient's denial of the hemichorea continued for three weeks from onset, but disappeared during the period when hemichorea was still observed.

The present case showed sudden onset of right-sided chorea and some decrease of muscular tone, but no symptoms of the pyramidal tract, such as motor paresis. Mild sensory abnormalities were observed in the right leg but rapidly disappeared and the patient was diagnosed as acute hemichorea. MRI clearly revealed a lesion localised to the head of the caudate nucleus contralateral to the involuntary movements.

Particularly noteworthy about this case was the denial of the hemichorea during the early stages of the disease. This finding is analogous to the denial of hemiplegia (anosognosia) first reported by Babinski² and indicates that anosognosia can also be found in cases of involuntary movements. Weinstein³ has previously described a case with diffuse brain tumour in which there was denial of involuntary movements, and Goldblatt *et al.*⁴ have also reported the denial of chorea in the acute stage in a case of hemichorea in which infarcts were confined to two locations in the caudate nucleus and the putamen.

Anosognosia is normally considered to be a deficit of higher cortical functions, and thought to be a right parietal sign.⁵ How-

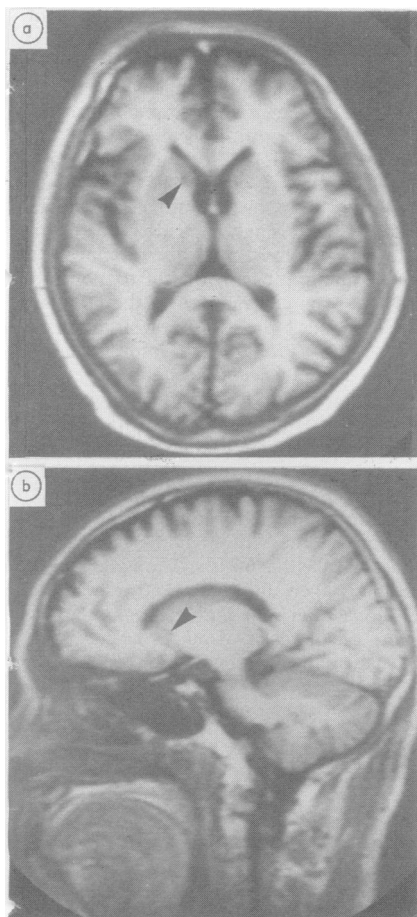


Fig MRI (92 days after symptom onset) (inversion recovery technique). (a) Horizontal view [time of repetition (TR) 2080 ms, time of inversion (TI) 500 ms], (b) Left lateral sagittal view (10 mm from midline) (TR 2080 ms, TI 500 ms), showing a small low intensity area at the head of the left caudate nucleus (arrows).

ever, on the basis of experimental results in the cat, in which sensory neglect was brought about by lesions of the ventral half of the frontal lobe (including a portion of the caudate nucleus and putamen),⁶ Goldblatt *et al*⁴ have previously suggested that denial might be caused by damage to the basal ganglia. Among conditions conducive to the emergence of denial symptoms, the patient's personality prior to the disease has been emphasised,⁷ and great care must be taken in considering the denial as indicative of a localised lesion. Nevertheless, recent

research on the cognitive functions of patients with Parkinson's disease have indicated that the basal ganglia may have an important role in cognition¹ and, from this perspective as well, the present case is of considerable interest.

MITSURU KAWAMURA
NOBUYOSHI TAKAHASHI
KEIZO HIRAYAMA
Department of Neurology,
Brain Research Institute,
School of Medicine,
Chiba University,
1-8-1 Inohana,
Chiba 280,
Japan

References

- 1 Marsden CD. Function of the basal ganglia as revealed by cognitive and motor disorders in Parkinson's disease. *Can J Neurol Sci* 1984;11:129-35.
- 2 Babinski J. Contribution à l'étude des troubles mentaux dans l'hémiplégie organique cérébrale (anosognosie). *Rev Neurol (Paris)* 1914;22:845-8.
- 3 Weinstein EA, Kahn RL. *Denial of Illness*, 1st ed. Springfield, Charles C Thomas, 1955: 10 and 131.
- 4 Goldblatt D, Markesbery W, Reeves AG. Recurrent hemichorea following striatal lesions. *Arch Neurol* 1974;31:51-4.
- 5 Hécaen H, Albert ML. *Human Neuropsychology*, 1st ed. New York: J Wiley and Sons, 1978:303-7.
- 6 Reeves AG, Hagamen WD. Behavioral and EEG asymmetry following unilateral lesions of the forebrain and midbrain in cats. *Electroencephalogr Clin Neurophysiol* 1971;30:83-6.
- 7 Weinstein EA, Kahn RL. *Denial of Illness*, 1st ed. Springfield, Charles C Thomas, 1955:71-84.

Accepted 2 November 1987

Essential tremor cured by infarction adjacent to the thalamus

Sir: The thalamic nucleus ventralis is thought to be important in the pathophysiology of essential tremor,¹ and stereotactic Vim (ventralis intermedius) thalamotomy² and chemothalamectomy³ have been used with some success in the treatment of essential tremor. We have seen a case in which tremor ceased unilaterally following an infarct of the internal capsule in close relation to the thalamus.

The patient presented at the age of 59 years with a one year history of tremor of

both hands. It was exacerbated by anxiety but not relieved by alcohol. His elder brother also had a tremor. He had no other complaints. There was no relevant past history. He was a smoker. On examination at that time, the only abnormality to be found was a postural tremor of the outstretched hands. There were no features of Parkinsonism. Idiopathic essential tremor was diagnosed, and he responded well to propranolol.

Six months later he presented again, with right sided weakness of acute onset. He was found to have a mild right hemiparesis with brisk tendon reflexes and upgoing plantar response. A CT scan showed a small infarct in the posterior limb of the internal capsule on the left, as it passed between the thalamus and the putamen (Fig). At review 6 months later the weakness had resolved completely. While the tremor persisted on the left, it had completely resolved on the right. Again, no features of Parkinsonism were found.

Using Marsden's classification,^{1,4} this patient's tremor is likely to be Type II, or benign pathologic essential tremor. This is postural, affects mainly the arms, and has a frequency range of 5-7 Hz. There is often a family history, and the pathogenesis is thought to involve a central oscillator. The site of the oscillator is unknown, but is likely to be associated with the cerebello-rubro-thalamo-cortical pathways.¹ Surgical treatment presumably either destroys the oscillator or interrupts the circuit elsewhere.

In the present case, the lesion occurred

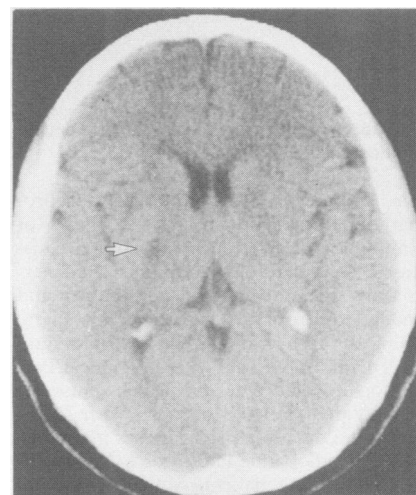


Fig CT scan showing infarction (arrowed) in the left internal capsule adjacent to the thalamus