

What Causes Anterograde Amnesia?

Jiwei Jiang Xiaoting Wang Yutong Chen Xiuli Shang

Department of Neurology, The First Affiliated Hospital of China Medical University, Shenyang City, China

What Causes Anterograde Amnesia?

Case Report

A 49-year-old woman with poorly controlled hypertension was admitted to our hospital for sudden memory deficit. Her daughter noticed that she repeatedly asked about the time for lunch on the day before admission and her inability to recall storylines on television programs. However, the patient recognized her daughter and other family members. She did not experience fatigue, fever, or diarrhea before the onset of amnesia. Her memory impairment was persistent. Headaches, convulsions, or limb movement disorders were absent. She had no history of smoking, drinking, trauma, drug abuse, or exposure to toxins. The findings of the neurological examination were unremarkable, except for the reduction in memory and calculation abilities, which manifested as the inability to recall incidents that occurred minutes ago, along with reiterations of the same questions. Her Mini-Mental State Examination score was 21, with deficits in the immediate memory (0/3), recall (0/3), and calculation (2/5) categories. The result of the Montreal Objective Cognitive Assessment was normal, with the exception of recall and calculation.

The patient's blood pressure at admission was 170/105 mm Hg. Serum total cholesterol and low-density lipopro-

tein levels were elevated, while other laboratory tests for blood cell counts, glucose, ion concentration, human immunodeficiency virus and syphilis antibodies, vitamin B1, vitamin B12, and folate, and liver, renal, and thyroid functions were normal. Cerebrospinal fluid assessment yielded normal results. The inflammatory, infectious, and immune biomarkers in cerebrospinal fluid were unremarkable. Brain magnetic resonance imaging (MRI) demonstrated symmetrical restricted diffusion signals in the bilateral fornix columns on axial diffusion-weighted imaging, with corresponding hypointensities on the apparent diffusion coefficient map (shown in Fig. 1), without abnormal signals in the established memory-related regions or other regions of the fornix (shown in Fig. 2). The findings of Holter electrocardiography, transthoracic echocardiography, and magnetic resonance angiography were normal. Treatment consisted of aspirin (100 mg/day), atorvastatin (20 mg/night), and butylphthalide administration to improve cerebral circulation and extended-release nifedipine tablets (30 mg/day) to control blood pressure, which resulted in the amelioration of the neurological symptoms.

What is your diagnosis?

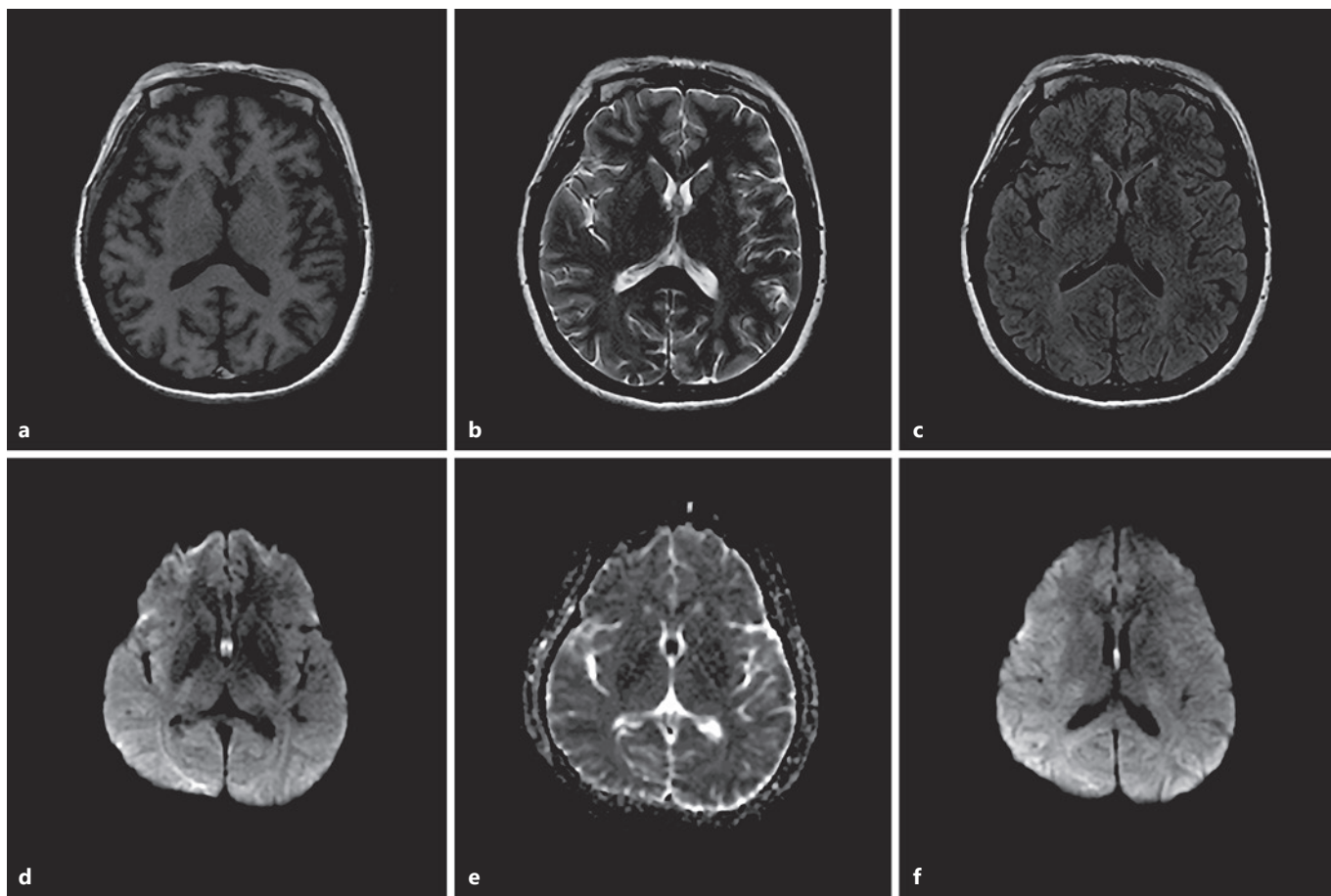


Fig. 1. Brain MRI of the fornix. Brain axial T1-weighted imaging (**a**) shows hypointensities in the bilateral fornix columns, with hyperintensities on T2-weighted (**b**) and fluid-attenuated inversion recovery imaging (**c**). Axial diffusion-weighted imaging (**d**, **f**) demonstrates symmetrical restricted diffusion signals in the bilateral fornix columns, with corresponding hypointensities on the apparent diffusion coefficient map (**e**), indicating acute infarction. MRI, magnetic resonance imaging.

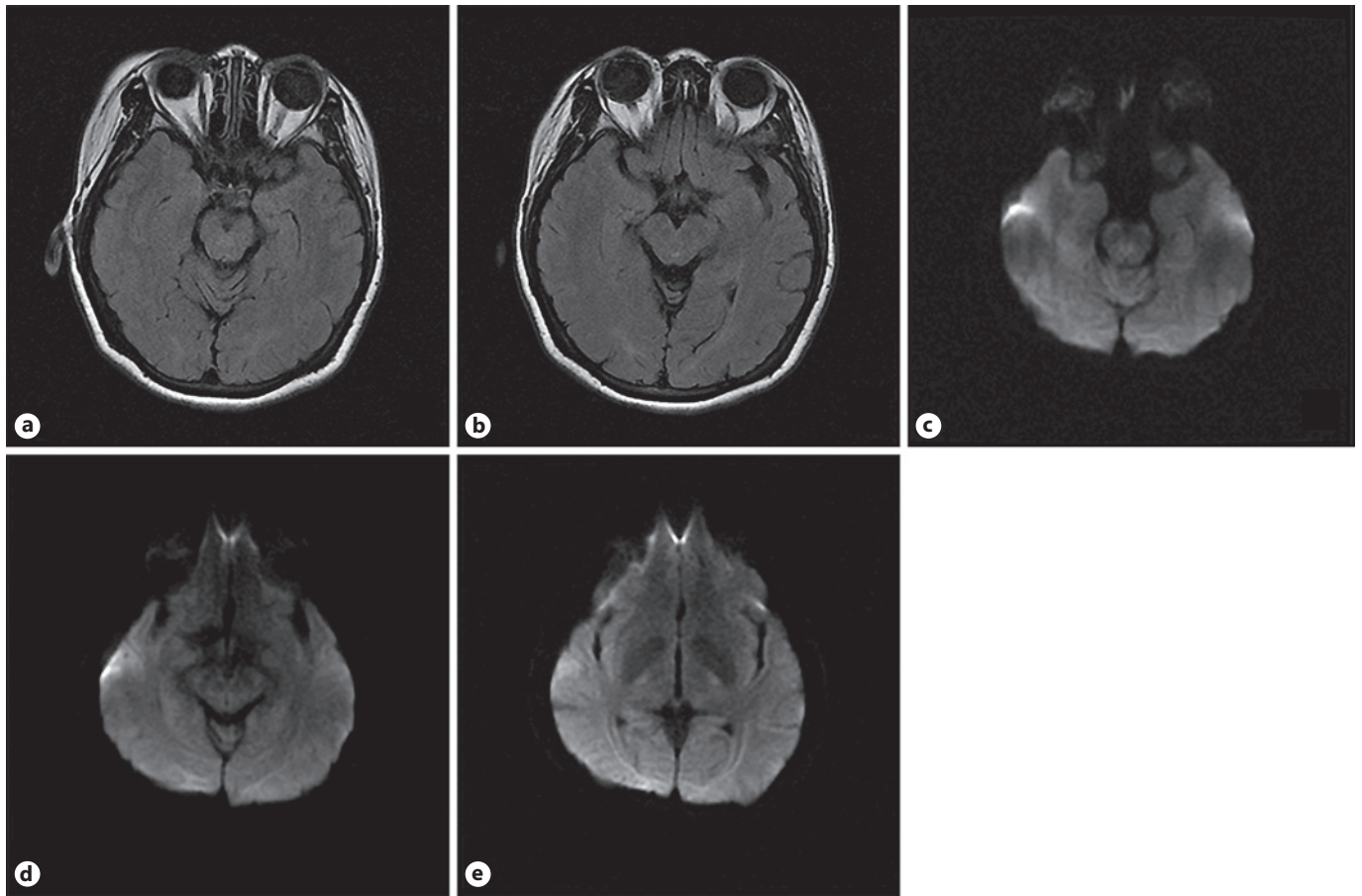


Fig. 2. Brain MRI of the other structures. **a, b** Brain fluid-attenuated inversion recovery imaging shows no abnormalities in the temporal lobe, hippocampus, amygdala, thalamus, or basal forebrain. **c–e** Axial diffusion-weighted imaging depicts the integrity of the fornix, medial temporal lobe memory structures, and diencephalic memory structures. MRI, magnetic resonance imaging.

Diagnosis

The patient was diagnosed with acute bilateral fornix-column infarctions based on the symmetrical restricted diffusion in the bilateral fornix columns on brain MRI. Acute amnesia is uncommon in patients with acute cerebral infarction and is initially misdiagnosed in approximately half the patients with this condition [1]. If it does occur, the causative lesions are usually located in the mesiotemporal lobe and hippocampus, thalamus, basal forebrain, or retrosplenial cortex [1–4]. Recently, several studies have demonstrated that fornix infarction can cause memory deficits; however, these lesions often involved the surrounding structures, such as the corpus callosum, hippocampus, or cingulate gyrus [5, 6]. It is difficult to eliminate the contribution of these well-known memory-related regions to amnesia in such cases. Moreover, the involvement of the fornix in this pathological process is often overlooked in routine clinical studies, even though it can be visualized clearly on MRI. This oversight results in avoidable invasive examinations, such as lumbar puncture. Herein, we reported a novel case of a 49-year-old woman who developed isolated primary bilateral fornix-column infarctions with sudden anterograde amnesia and elucidated the clinical characteristics and possible mechanisms underlying fornix infarction that may be easily missed in clinical practice.

The fornix consists of 4 parts, that is, the fimbria hippocampi, crura of the fornix, body of the fornix, and fornix-column. Previous studies showed that lesions were often observed in the bilateral fornix columns or anterior fornices, including the fornix columns. The definitive vascular supply of the fornix is currently unclear. Recent studies have highlighted the role of the subcallosal artery (SCA), the largest unpaired perforator arising from the posterior or posterosuperior part of the anterior communicating artery, in the vascular supply to the bilateral fornix columns [5, 7]. Usually, it is difficult to detect such small vessel stenoses using conventional magnetic resonance angiography, like in our case. Nevertheless, the SCA exhibits a high degree of anatomical variation [8]. An anatomic autopsy study showed that SCAs supplying the anterior fornix were significantly broader and longer than those that did not supply the fornix [9]. Sometimes, the SCA does not originate from the anterior communicating artery but arises directly from the anterior cerebral artery [7] or posterior circulation (especially the lateral posterior choroidal artery) and anastomoses with the anterior cerebral and anterior choroidal branches, thus providing additional vascular supply to the fornix [6]. Therefore, we

speculate that small vessel disease with frequent anatomical vascular variations is the probable etiology of primary fornix infarction, which typically manifests bilaterally and occurs in the fornix columns.

Patients with isolated bilateral fornix infarctions exhibit various clinical manifestations, including anterograde and retrograde amnesia, disorientation, and confabulation, but we observed that anterograde amnesia was the initial symptom in all reported patients. Moreover, the memory deficits in anterograde amnesia often manifested as impaired learning or recall of new episodic information, based on the description of these reports. Several different neural networks in the human brain are related to memory, and the involvement of the basal forebrain and Papez circuit is the most acceptable explanation for these manifestations [10]. On one hand, injury to the fornix-column that includes the precommissural fibers, which contain cholinergic fibers (a part of the basal forebrain) connecting the septal nuclei to the hippocampus, causes “basal forebrain” amnesia [11]. Moreover, previous studies have provided evidence of the marked association between basal forebrain activity and episodic memory recall [12, 13]. On the other hand, the fornix is a crucial part of the Papez circuit, connecting the hippocampus to the mammillary body, which is thought to contribute to efficient encoding and normal recall of new episodic information [14, 15]. Furthermore, previous research has found that damage to different parts of the Papez circuit can cause different types of memory deficits [10]: damage to the neocortical association areas leads to the loss of long-term memory and inability to store new memories, whereas damage to the fornix and hippocampus results in the global inability to form new declarative memories. Therefore, we speculate that anterograde amnesia presenting with greater impairment in learning and recall of episodic information could direct physicians toward the possibility of fornix infarction.

In conclusion, anterograde amnesia caused by primary isolated bilateral fornix infarctions is rare and can be easily missed in clinical practice, resulting in some unnecessarily expensive and/or invasive examinations. The involvement of small basal forebrain structures, such as the cholinergic nuclei, or damage to the integrity of the Papez circuit may probably be the pathophysiological mechanisms underlying this type of amnesia. Small vessel disease with frequent anatomical vascular variations is probably the principal etiology of this condition. Clinicians should consider fornix infarctions in patients with

acute amnesia, especially in those exhibiting vascular risk factors. Prospective research is needed to elucidate the mechanisms underlying fornix-related amnesia for their differential diagnosis in clinical practice.

Acknowledgement

We would like to thank the patient and her family for their participation and help. We would like to thank Editage (www.editage.cn) for English language editing.

Statement of Ethics

This study was conducted in line with the principles of the Declaration of Helsinki. Approval was granted by the First Affiliated Hospital of China Medical University Medical Science Research Ethics Committee (committee reference number: [2019]325). Written informed consent was obtained from the patient for the submission and publication of this case report and all accompanying images.

Conflict of Interest Statement

The authors have no conflicts of interest to declare.

References

- 1 Michel P, Beaud V, Eskandari A, Maeder P, Demonet JF, Eskioglou E. Ischemic amnesia: causes and outcome. *Stroke*. 2017 Aug;48(8):2270–3.
- 2 Osimani A, Vakil E, Blinder G, Sobel R, Abarbanel JM. Basal forebrain amnesia: a case study. *Cogn Behav Neurol*. 2006 Jun;19(2):65–70.
- 3 Pergola G, Danet L, Barbeau EJ, Eustache P, Planton M, Raposo N, et al. Thalamic amnesia after infarct: the role of the mammillothalamic tract and mediodorsal nucleus. *Neurology*. 2016 May 17;86(20):1928.
- 4 Fournier DI, Eddy MC, DeAngeli NE, Huszár R, Bucci DJ. Retrosplenial cortex damage produces retrograde and anterograde context amnesia using strong fear conditioning procedures. *Behav Brain Res*. 2019 Sep 2;369:111920.
- 5 Meila D, Saliou G, Krings T. Subcallosal artery stroke: infarction of the fornix and the genu of the corpus callosum. The importance of the anterior communicating artery complex. Case series and review of the literature. *Neuroradiology*. 2015 Jan;57(1):41–7.
- 6 Kurokawa T, Baba Y, Fujino K, Kuroiwa Y, Tomita Y, Nakane M, et al. Vertebral artery dissection leading to fornix infarction: a case report. *J Stroke Cerebrovasc Dis*. 2015 Jul;24(7):e169–72.
- 7 Salvalaggio A, Cagnin A, Nardetto L, Manara R, Briani C. Acute amnesic syndrome in isolated bilateral fornix stroke. *Eur J Neurol*. 2018 May;25(5):787–9.
- 8 Matsushige T, Chen B, Dammann P, Johst S, Quick HH, Ladd ME, et al. Microanatomy of the subcallosal artery: an in vivo 7 T magnetic resonance angiography study. *Eur Radiol*. 2016 Sep;26(9):2908–14.
- 9 Louis C, Aimé K, Pascal F, Havet Eric, Johann P. Microsurgical anatomy of the subcallosal artery. *Surg Radiol Anat*. 2019 Sep;41(9):1037–44.
- 10 Thomas AG, Koumellis P, Dineen RA. The fornix in health and disease: an imaging review. *Radiographics*. 2011 Jul–Aug;31(4):1107–21.
- 11 Duvernoy HM, Cattin F, Risold P-Y. *Structures, functions, and connections the human hippocampus: functional anatomy, vascularization and serial sections with MRI*. 4th ed. Berlin: Springer; 2013. p. 5–38.
- 12 Fujii T, Okuda J, Tsukiura T, Ohtake H, Miura R, Fukatsu R, et al. The role of the basal forebrain in episodic memory retrieval: a positron emission tomography study. *Neuroimage*. 2002 Mar;15(3):501–8.
- 13 Fujii T. The basal forebrain and episodic memory. In: Dere E, Easton A, Nadel L, Huston JP, editors. *Handbook of episodic memory*. The Netherlands: Elsevier Science; 2008. p. 343–58.
- 14 Ferguson MA, Lim C, Cooke D, Darby RR, Wu O, Rost NS, et al. A human memory circuit derived from brain lesions causing amnesia. *Nat Commun*. 2019 Aug 2;10(1):3497.
- 15 Hodgetts CJ, Postans M, Warne N, Varnava A, Lawrence AD, Graham KS. Distinct contributions of the fornix and inferior longitudinal fasciculus to episodic and semantic autobiographical memory. *Cortex*. 2017 Sep;94:1–14.

Funding Sources

This study was supported by the National Natural Science Foundation of China (81871104). Funding for data collection, analysis, and interpretation and writing the manuscript was provided by Xiuli Shang.

Author Contributions

Jiwei Jiang: conceptualization and design of the study, interpretation of data, drafting, and revising the manuscript; Xiaoting Wang: critical revision of the manuscript for important intellectual content; Yutong Chen: ethics submission; Xiuli Shang: conceptualization and design of the study, critical revision of the manuscript for important intellectual content, and funding support. All authors have read and approved the manuscript.

Keywords

Amnesia · Cerebral infarction · Fornix · Magnetic resonance imaging