

## Phenobarbital-Induced Buccolingual Dyskinesia in Oral Apraxia

GianPietro Sechi, Maria Rita Piras, Giulio Rosati, Marco Zuddas, Renato Ortu, Salvatore Tanca, Virgilio Agnetti

Department of Neurology, University of Sassari, Italy

**Key Words.** Phenobarbital · Buccolingual dyskinesia · Oral apraxia

**Abstract.** A young woman with oral apraxia and a well-defined brain lesion on CT scan developed buccolingual dyskinesia lasting 40 days after low phenobarbital (PB) doses. Disruption of the corticostriatal glutamatergic pathway from areas 6 and 4 may have been important both in causing oral apraxia and in lowering the threshold for PB-induced buccolingual dyskinesia.

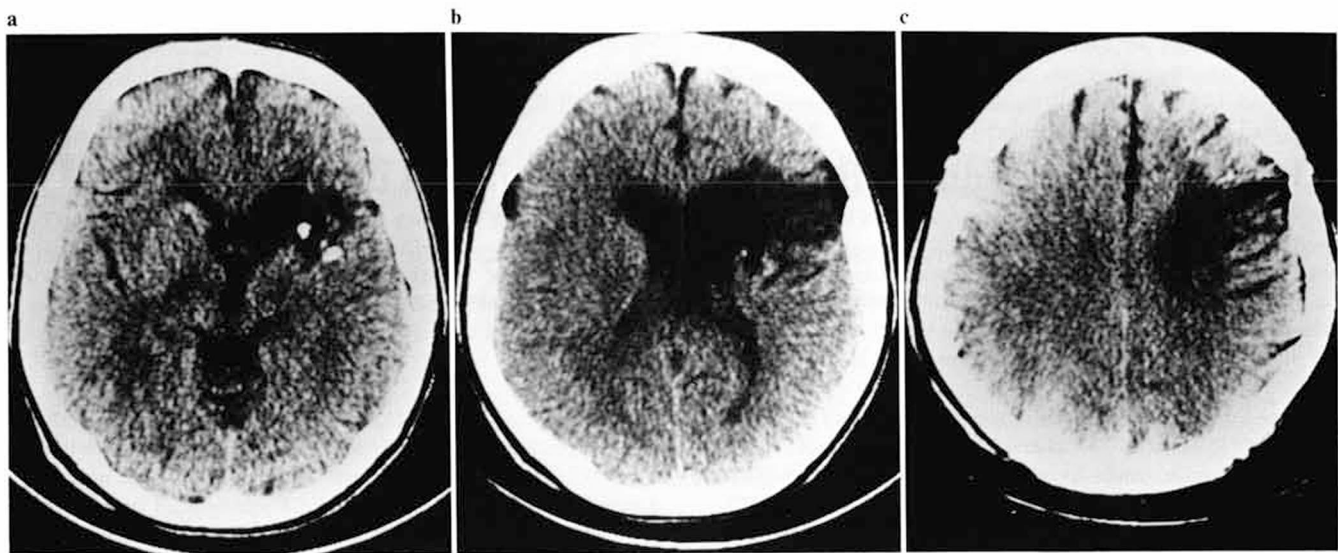
### Introduction

Orofacial dyskinesia has been described after administration of several drugs, including the anticonvulsants phenytoin, primidone, carbamazepine and phenobarbital at toxic levels [1-4]. The occurrence of buccolingual dyskinesia in a neurologically impaired child, soon after the intake of low phenobarbital (PB) doses has recently been reported [5]. We studied a similar case in which, in addition, oral apraxia and a well defined brain lesion on CT scan were documented. Such an association has not been reported previously.

### Case Report

A 25-year-old woman with a third-grade education was admitted to this neurological ward in December 1985 for epileptic generalized seizures. She was right-handed, but ambilaterality was present in a sister. Neurological examination showed a normally alert and cooperative patient. Mild left hemiparesis and nonfluent aphasia were present, likely due to tubercular meningoencephalitis contracted when she was 7 years old. The optic fundi showed no abnormality and no other neurological abnormalities were recorded. Laboratory findings including urea, glucose, electrolytes, EEG, chest X-ray, liver and thyroid function tests were within normal limits. A CT scan performed without contrast in January 1985 showed a low-density area in the right frontal region involving both cortical and subcortical areas (fig. 1). The lesion was evident in the low- and

high-ventricular slices as well as in the supraventricular ones. More precisely, the following subcortical structures seemed involved in the low-ventricular slices: putamen and head of the caudate nucleus (small calcifications were found in both) and part of the anterior limb of the internal capsule with extension into paraventricular white matter deep into area 44. The lesion extended superiorly into the paraventricular white matter corona radiata deep in the precentral gyrus area representing the lower part of the face at high-ventricular slices. Areas 44, 6 and, possibly, part of area 4, were involved at the cortical level. Neuropsychological examination was carried out in December 1985. Mental status examination showed a fully alert patient. IQ performance scale was 52. Raven's progressive matrices were 36.11% (13/36). The patient's speech was not fluent; the expression was low with articulation difficulties. Agrammatism was present. The patient series speech, counting and reciting the months were performed with difficulty. The result of the repetition tasks was poor. There were 90% errors for letters, syllables and 100% errors for words. The phonemic paraphasia impaired any attempt to repeat phrases or sentences. She was aware of errors which she attempted to correct, and often exhibited catastrophic depressive reactions. Verbal comprehension, assessed with the token test was relatively good (25/36). The patient had difficulty in reading aloud single letters and syllables, but more so with single words, owing to frequent paralexia. She could not carry out written commands. Spontaneous writing, performed with the right hand, was poor. On dictation of words, most of her recordings were incorrect due to numerous omissions. Copy was performed better (20% errors). Movements of the face and buccorespiratory apparatus were performed with difficulty on verbal command (2/20) and imitation (2/20). The patient was started with PB 100 mg daily after the neuropsychological examination was performed. Six hours after the first dose, she suddenly developed continuous perioral muscle spasms



**Fig. 1.** CT scan without contrast. A low-density area in the right frontal region involving both cortical and subcortical regions is evidenced in the low-ventricular (a), high-ventricular (b) and supraventricular (c) slices.

and dystonic lingual movements. After 12 days of PB therapy (blood level = 16  $\mu\text{g/ml}$ ), she could not chew, or swallow because of continuous oromandibular dystonic spasms with involuntary jaw opening, protrusion of the tongue and blowing movements of the cheeks. The movements stopped in sleep and were not associated with EEG epileptiform activity. When the PB dose was reduced to 50 mg daily for 2 weeks there was a moderate improvement of dystonic movements and the drug was discontinued. The oromandibular movements abated 40 days later. After 45 days, PB 50 mg daily was restarted with recurrence of buccolingual dyskinesias after 1 day (blood level = 6  $\mu\text{g/ml}$ ). Sodium valproate was substituted for PB. The dyskinesia abated 10 days later.

## Discussion

Our case confirms that PB may induce orofacial dyskinesia at low therapeutic dosages in the presence of a preexistent cerebral injury [5]. In addition, it poses the question whether oral apraxia may lower the threshold for PB-induced buccolingual dyskinesia. Apraxia, which is defined as a defect in motor performance and behavior without concomitant relevant paresis, ataxia, incoordination or dystonic dyskinesia [6], may be due to lesions in some parts of the cerebral cortex (both left and right hemisphere), corpus callosum with its radiation, basal ganglia and/or thalamus [7–9]. In particular it appears that the cerebral cortex alone cannot execute a coordinated skilled movement [9], and that the integrity of subcortical circuits and structures (e.g. corticostriate and thalamostriate pathways) may be crucial for perfor-

mance [10, 11]. In our case, several cortical and subcortical connections and structures are disrupted. However, as documented by the limited lesion on CT scan, the corticostriate glutamatergic pathway from areas 6 and 4, which is excitatory to the small 'spiny' neurons in the caudate and putamen [12] seems mainly involved. In our opinion, the disruption of this pathway might play a role both in the pathophysiology of oral apraxia and in lowering the threshold for PB-induced buccolingual dyskinesia. The loss of cortical control on the striatum reduces the inhibitory GABA-ergic tone of the striatopallidal neuronal chain [12], which in turn leads to a disinhibition of the pallidum [12]. Interestingly, a frequently obtained effect of stimulation of the pallidum in freely moving cats (Hess technique) is licking [10]. In this predisposing condition small PB doses might induce dystonic movements through a further selective depression of the depolarization elicited by glutamate in the striatum [13] and/or affecting the function of other neurotransmitter likely involved in the pathophysiology of cranial dystonia such as GABA and acetylcholine [14–16]. Our patient developed PB-induced buccolingual dyskinesias only, while Wiznitzer and Younkin's [5] patient also had cervical dystonia and blepharospasm. This is likely due to the limited brain lesion observed on CT scan in the former case (where a corticosubcortical somatotopic organization involving oral structures seems affected), with respect to the diffuse cortical and subcortical lesions observed in the later. In both cases,

the PB-induced buccolingual dyskinesias persisted for 40 days although negligible drug levels were found in the blood. This may be due either to a pharmacokinetic phenomenon, by accumulation and persistence of PB in the brain [17, 18] or to a pharmacodynamic one by the effects of PB on specific biochemical processes in the brain (e.g. reduction of the synthesis and central release of acetylcholine) [13].

## References

- 1 Shuttleworth, E.; Wise, G.; Paulson, G.: Choreoatetosis and diphenylhydantoin intoxication. *J. Am. med. Ass.* 230: 1170-1171 (1974).
- 2 Chadwich, D.; Reynolds, E.H.; Marsden, C.D.: Anticonvulsant-induced dyskinesias: a comparison with dyskinesias induced by neuroleptics. *J. Neurol. Neurosurg. Psychiat.* 39: 1210-1218 (1976).
- 3 Lightman, S.L.: Phenobarbital dyskinesia. *Post-grad. med. J.* 54: 114-115 (1978).
- 4 Joyce, R.P.; Gunderson, C.H.: Carbamazepine-induced orofacial dyskinesia. *Neurology* 30: 1333-1334 (1980).
- 5 Wiznitzer, M.; Younkin, D.: Phenobarbital-induced dyskinesia in a neurologically-impaired child. *Neurology, Cleveland* 34: 1600-1601 (1984).
- 6 De Jong, R.N.: *The neurological examination*; 3rd ed. (Harper & Row, New York 1967).
- 7 Agostoni, E.; Colleti, A.; Orlando, G.; Tredici, G.: Apraxia in deep cerebral lesions. *J. Neurol. Neurosurg. Psychiat.* 46: 804-808 (1983).
- 8 Dee, H.L.; Benton, A.L.; Van Allen, M.W.: Apraxia in relation to hemispheric locus of lesion and aphasia. *Trans. Am. neurol. Ass.* 95: 147-150 (1970).
- 9 Heilman, K.M.: Apraxia; in Heilman, Valenstein, *Clinical neuropsychology*, pp. 159-185 (Oxford University Press, New York 1979).
- 10 Hassler, R.: Striatal control of locomotion, intentional actions and of integrating and perceptive activity. *J. neurol. Sci.* 36: 187-224 (1978).
- 11 Marsden, C.D.: The mysterious motor function of the basal ganglia: the Robert Wartemberg lecture. *Neurology, N.Y.* 32: 514-539 (1982).
- 12 Kitai, S.T.: Electrophysiology of the corpus striatum and brainstem integrating system; in Brooks, *Handbook of physiology*, sect. I, vol. II. Motor control (American Physiological Society Bethesda 1981).
- 13 Okamoto, M.: Barbiturates and alcohol: comparative overviews on neurophysiology and neurochemistry; in Lipton, Di Mascio, Killam. *Psychopharmacology: a generation of progress*, pp. 1575-1590 (Raven Press, New York 1978)
- 14 Casey, D.E.: Pharmacology of blepharospasm-oromandibular dystonia syndrome. *Neurology* 30: 690-695 (1980).
- 15 Jankovic, J.; Ford, J.: Belpharospasm and orofacial-cervical dystonia: clinical and pharmacological findings in 100 patients. *Ann. Neurol.* 13: 402-411 (1983).
- 16 Sechi, G.P.; Demontis, G.; Rosati, G.: Relationship between Meige syndrome and alpha-methyl dopa-induced parkinsonism. *Neurology* 35: 1668-1669 (1985).
- 17 Goldberg, M.A.: Phenobarbital: binding; in Glaser, Penry, Woodbury, *Antiepileptic drugs: mechanism of action*, pp. 501-504 (Raven Press, New York 1980).
- 18 Monaco, F.; Sechi, G.P.; Piredda, S.; et al.: The penetration of phenobarbital in generalized and focal penicillin-induced epileptic brain of the cat. *Epilepsia* 24: 686-691 (1983).

Received: June 20, 1987

Accepted: August 24, 1987

Dr. GianPietro Sechi  
 Clinica Neurologica  
 Viale S. Pietro, 10  
 I-07100 Sassari (Italy)