

Difficulty in articulation following left progressive blurred vision

An-Ting Lee^{1,2} , Wei-Dar Chen^{2,3}
and Chien-Hsiung Lai^{2,3,4,5}

European Journal of Ophthalmology
1–4

© The Author(s) 2021

Article reuse guidelines:

sagepub.com/journals-permissions

DOI: 10.1177/11206721211008037

journals.sagepub.com/home/ejo



Abstract

Purpose: To report a case of Paracentral acute middle maculopathy (PAMM) caused by severe internal carotid artery (ICA) stenosis and discuss the correlation between PAMM and ICA stenosis.

Case description: A 67-year-old male patient presented with left acute blurred vision for 1 week. The best-corrected visual acuity of the left eye was 0.01. Funduscopy examination showed multiple grayish patches around the left macula. Optical coherence tomography (OCT) demonstrated train-track hyperreflective lesions over the inner nuclear layer of the left eye. Afterwards, he experienced sudden slurred speech with fair comprehension. Magnetic resonance imaging and angiography of the brain demonstrated left lacunar infarction with severe left ICA stenosis. After anticoagulant therapy, his dysarthria and left visual acuity were improved significantly.

Conclusions: To our knowledge, PAMM in coincidence with lacunar infarction induced by ICA stenosis is firstly described in the literature. PAMM could be a critical warning of ICA stenosis, and this case can alert ophthalmologists to survey ICA stenosis in patients with PAMM.

Keywords

Arterial occlusive disease, retina, age-related macular degeneration, anatomy/biochemistry/physiology, retinal degenerations associated with systemic disease

Date received: 11 January 2021; accepted: 26 February 2021

Introduction

Paracentral acute middle maculopathy (PAMM), first described by Sarraf et al.¹ is defined as one variant of the acute macular neuroretinopathies (AMNs). There are two types of AMNs based on the location of the ischemic retinal lesions. The lesions between the junction of the outer plexiform layer (OPL) and the inner nuclear layer (INL) are known as type I of AMNs and referred to as PAMM. Type 2 AMNs show lesions between the junction of the OPL and the outer nuclear layer (ONL).² The pathogenesis of PAMM is considered to be the ischemia of the superficial capillary plexus (MCP) or deep capillary plexus (DCP).³ However, the etiology of PAMM has not been well elucidated. In a few published reports, some cases were idiopathic, but diabetes mellitus, hypertension, hypotension, hyperlipidemia, sickle cell disease, hemophilia, viral illness, human immunodeficiency virus infection,

migraine, prolonged hypoxia, hypothyroidism, glaucoma, pregnancy, factor V Leiden deficiency, post-cardiac catheterization, transient orbital compression, and intraocular surgeries could be possible risk factors for PAMM.^{4–7} In

¹Department of Medical Education, Chang Gung Memorial Hospital, Chiayi

²College of Medicine, Chang Gung University, Taoyuan

³Department of Ophthalmology, Chang Gung Memorial Hospital, Chiayi

⁴Department of Nursing, Chang Gung University of Science and Technology, Chiayi

⁵School of Traditional Chinese Medicine, College of Medicine, Chang Gung University, Taoyuan

Corresponding author:

Chien-Hsiung Lai, Department of Ophthalmology, Chang Gung Memorial Hospital, 6 Sec West, Chia-Pu Road, Putzu City, Chiayi.
Emails: oph4557@cgmh.org.tw; oph4557@gmail.com

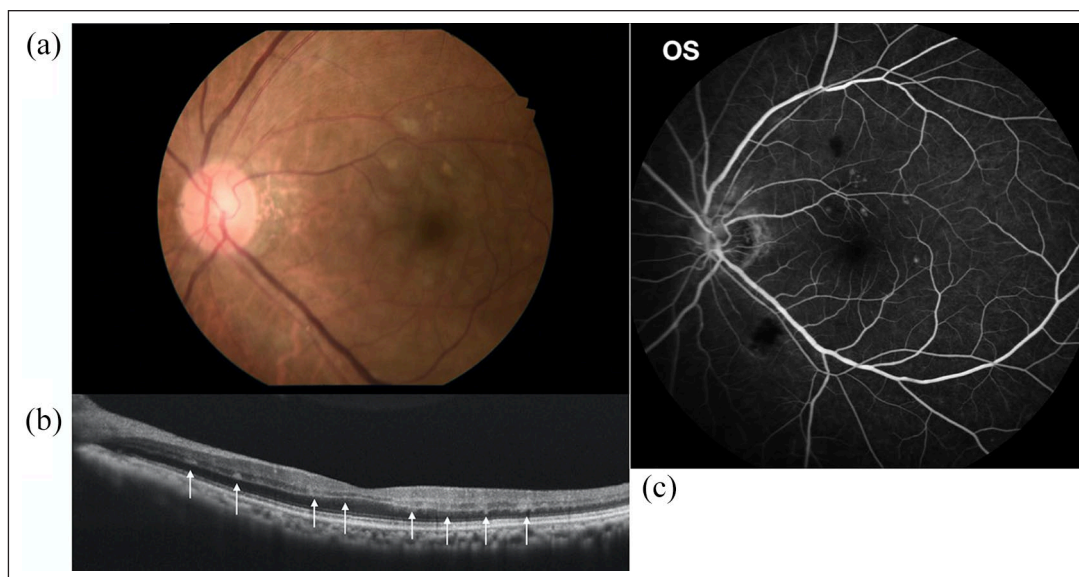


Figure 1. (a) Color fundus showed multiple grayish lobules over left paramacula, (b) optical coherence tomography demonstrated multiple train-track hyperreflective lesions (white arrows) over the inner nuclear layer of retina in the left eye, and (c) fluorescein angiography (FA) illustrated scattered microaneurysms over left paramacula.

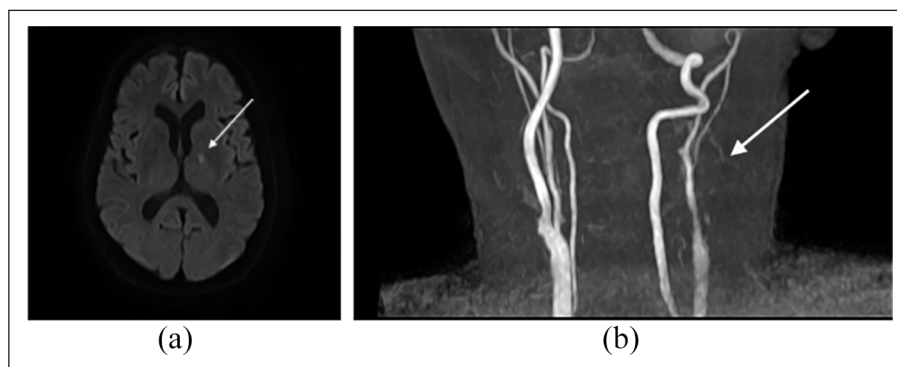


Figure 2. (a) Diffusion-weighted imaging revealed a spot with high signal (white arrow) in the left posterior limb of the internal capsule and (b) time-of-flight magnetic resonance angiography demonstrated high-grade stenosis (white arrow) in left internal carotid artery.

this report, we share a unique case simultaneously diagnosed with PAMM and lacunar infarction because of severe internal carotid artery (ICA) stenosis. To date, no case report has presented the correlation between PAMM and ICA stenosis. Hence, through this case presentation, we wish to remind ophthalmologists to survey ICA stenosis under the diagnosis of PAMM.

Case description

This 67-year-old male patient with a history of hypertension, renal insufficiency, gout, who had a stroke in 2013 experienced left acute blurred vision for 1 week. He denied undergoing any ocular trauma or surgery recently. The

best-corrected visual acuity (BCVA) of the right and left eyes was 0.15 and 0.01, respectively. The poor vision of the right eye was due to an old traumatic optic neuropathy. The intraocular pressures of the right and left eyes were 11 and 6 mmHg, respectively. The pupils were isochoric, but a left relative afferent pupillary defect (RAPD) was present. The extraocular motion was full and free in both eyes. The anterior segments were unremarkable except for moderate nucleus sclerosis in both eyes. Funduscopy examination showed multiple grayish patches around the macula with scattered cotton-wool spots in the left eye (Figure 1(a)). Optical coherence tomography (OCT) demonstrated train-track hyperreflective lesions over the INL of the left eye (Figure 1(b)). Fluorescein angiography

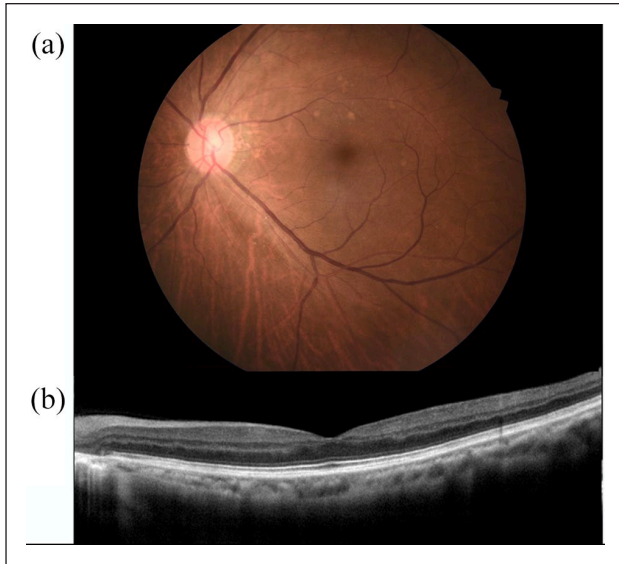


Figure 3. (a) After 3 months, the funduscopy examination revealed the multiple grayish lobules over left paramacula disappeared with several cotton wool spots and (b) optical coherence tomography illustrated that there were few residue hyperreflective lesions over the inner nuclear layer of the left eye.

(FA) revealed several microaneurysms around the left macula (Figure 1(c)).

However, an episode of acute dysarthria was noted immediately after the patient visited the ophthalmology clinic. He presented with sudden slurred speech, but his consciousness and comprehension were fair. He denied any focal weakness, numbness, or gait disturbance. Magnetic resonance imaging of the brain showed an oval lesion with a high diffusion-weighted imaging value (Figure 2(a)) and a low apparent diffusion coefficient value over the left posterior limb of the internal capsule. Magnetic resonance angiography demonstrated severe stenosis of the left ICA (Figure 2(b)). Moreover, transcranial Doppler ultrasound imaging also revealed severe left ICA stenosis with scarce blood flow. These findings of multimodal images were compatible with the diagnosis of left lacunar infarction with left ICA stenosis. Subsequently, the patient was treated with aspirin 100 mg per day and he was hydrated.

One week later, his dysarthria had lessened drastically, and the uncorrected visual acuity (UCVA) of his left eye had returned to 0.4. After a 3-month follow-up, the UCVA of the left eye was 0.6, and the left RAPD was absent. Previous grayish patches around the left macula were totally faded out with some cotton wool spots (Figure 3(a)), and OCT displayed no hyperreflective lesions over the INL of the left eye (Figure 3(b)).

Conclusions

This is the first reported case of PAMM accompanied by lacunar infarction caused by severe ICA occlusion. PAMM is characterized by the presence of hyperreflective band-like lesions between the junction of the OPL and INL on OCT imaging. With the advent of optical coherence tomography angiography, attenuated and lower capillary density of the ICP and DCP were observed in cases with PAMM.^{3,8} Ischemia of the ICP and DCP is viewed as the primary pathogenesis of PAMM, but the etiology of PAMM remains unknown. Some cases were idiopathic, and other cases may complicate systemic or retinal vascular diseases such as hypertension, diabetes mellitus, hyperlipidemia, retinal vein, and artery occlusion. In this case, the left eye diagnosed with PAMM was attributed to severe ICA stenosis and accompanied by the occurrence of lacunar infarction.

Lacunar infarction is a common type of cerebral small vessel disease. The location of infarction is usually noncortical, and the vessels of occlusion are usually the penetrating branches of the large cerebral artery. Microatheroma and lipohyalinosis are considered the principal mechanisms of lacunar infarction. Patients with lacunar infarction tend to have a lower extent of carotid artery stenosis. However, almost 15% of symptomatic patients with severe carotid stenosis were reported to have a risk of lacunar infarction.⁹ In this case, severe stenosis of the ICA was regarded as the etiology of simultaneous small vessel disease of the eye and the brain. A reasonable inference is that terminal circulation such as the ICP, DCP, or lacunar vessels would be temporarily sacrificed once the ICA stenosis decreases the blood perfusion of main branches such as the ophthalmic artery or cardinal cerebral arteries.

There is currently no effective treatment for PAMM, but most cases have a satisfactory prognosis after a 3- to 6-month follow-up.^{3,10} In this case, the patient received anticoagulant therapy including aspirin and hydration for lacunar infarction and ICA stenosis. Unexpectedly, the patient had a remarkable improvement in visual acuity and dysarthria in just 1 week. Consequently, anticoagulant therapy may be preferable to increase terminal blood flow for PAMM.

To our knowledge, this is the first time simultaneous PAMM and lacunar infarction was described in the literature, and as such PAMM could be a critical warning for ICA stenosis. In summary, not only for retinal artery occlusion, the occurrence of PAMM should also include a work-up to survey a possible ICA stenosis. ICA stenosis could be a risk factor for PAMM, and it is necessary to further illustrate the correlation between PAMM and ICA stenosis through larger clinical investigations.

Declaration of conflicting interests

The author(s) declared no potential conflicts of interest with respect to the research, authorship, and/or publication of this article.

Funding

The author(s) received no financial support for the research, authorship, and/or publication of this article.

Ethical approval

The approval of institutional review board number was 202000822B0.

ORCID iD

An-Ting Lee  <https://orcid.org/0000-0002-5236-563X>

References

1. Sarraf D, Rahimy E, Fawzi AA, et al. Paracentral acute middle maculopathy: a new variant of acute macular neuroretinopathy associated with retinal capillary ischemia. *JAMA Ophthalmol* 2013; 131(10): 1275–1287.
2. Nemiroff J, Sarraf D, Davila JP, et al. Optical coherence tomography angiography of acute macular neuroretinopathy reveals deep capillary ischemia. *Retin Cases Brief Rep* 2018; 12(Suppl. 1): S12–S15.
3. Rahimy E, Kuehlewein L, Sadda SR, et al. Paracentral acute middle maculopathy: what we knew then and what we know now. *Retina* 2015; 35(10): 1921–1930.
4. Chen X, Desai SJ and Baomal CR. Paracentral acute middle maculopathy in pregnancy. *Retin Cases Brief Rep* 2020; 14(3): 221–223.
5. Nakamura M, Katagiri S, Hayashi T, et al. Paracentral acute middle maculopathy after endovascular coil embolization. *Retin Cases Brief Rep*. Epub ahead of print 13 July 2018. DOI: 10.1097/ICB.0000000000000784.
6. Creese K, Ong D, Sandhu SS, et al. Paracentral acute middle maculopathy as a finding in patients with severe vision loss following phacoemulsification cataract surgery. *Clin Exp Ophthalmol* 2017; 45(6): 598–605.
7. Chen Y and Hu Y. The optical imaging of idiopathic paracentral acute middle maculopathy in a Chinese young man and review of the literature. *Photodiagnosis Photodyn Ther* 2017; 19: 383–387.
8. Sridhar J, Shahlaee A, Rahimy E, et al. Optical coherence tomography angiography and en face optical coherence tomography features of paracentral acute middle maculopathy. *Am J Ophthalmol* 2015; 160(6): 1259–1268.e1252.
9. Barnett HJ, Gunton RW, Eliasziw M, et al. Causes and severity of ischemic stroke in patients with internal carotid artery stenosis. *JAMA* 2000; 283(11): 1429–1436.
10. Shah A, Rishi P, Chendilnathan C, et al. OCT angiography features of paracentral acute middle maculopathy. *Indian J Ophthalmol* 2019; 67(3): 417–419.