


Combined contralateral C7 to C7 and L5 to S1 cross nerve transfer for treating limb hemiplegia after stroke

Fangjing Yang, Liwen Chen, Haipeng Wang, Jionghao Zhang, Yundong Shen, Yanqun Qiu, Zhiwei Qu, Jie Li & Wendong Xu

To cite this article: Fangjing Yang, Liwen Chen, Haipeng Wang, Jionghao Zhang, Yundong Shen, Yanqun Qiu, Zhiwei Qu, Jie Li & Wendong Xu (2021): Combined contralateral C7 to C7 and L5 to S1 cross nerve transfer for treating limb hemiplegia after stroke, British Journal of Neurosurgery, DOI: [10.1080/02688697.2021.1910764](https://doi.org/10.1080/02688697.2021.1910764)

To link to this article: <https://doi.org/10.1080/02688697.2021.1910764>

 Published online: 10 Apr 2021.

 Submit your article to this journal [↗](#)

 Article views: 29

 View related articles [↗](#)

 View Crossmark data [↗](#)

Combined contralateral C7 to C7 and L5 to S1 cross nerve transfer for treating limb hemiplegia after stroke

Fangjing Yang^{a*}, Liwen Chen^{b,c*}, Haipeng Wang^{c,d}, Jionghao Zhang^{c,d}, Yundong Shen^{a,b,c}, Yanqun Qiu^{a,b,c}, Zhiwei Qu^{c,d}, Jie Li^{b,c} and Wendong Xu^{a,b,c,e,f}

^aDepartment of Hand Surgery, Huashan Hospital, Fudan University, Shanghai, China; ^bDepartment of Hand and Upper Extremity Surgery, Jing'an District Center Hospital, Shanghai, China; ^cShanghai Clinical Medical Center for Limb Function Reconstruction, Shanghai, China; ^dDepartment of Orthopedics, Jing'an District Center Hospital, Shanghai, China; ^eNational Clinical Research Center for Aging and Medicine, Huashan Hospital, Fudan University, Shanghai, China; ^fShanghai Key Laboratory of Peripheral Nerve and Microsurgery, China, Shanghai

ABSTRACT

Background: Contralateral C7 to C7 cross nerve transfer has been proved to be safe and effective for patients with spastic arm paralysis due to stroke and traumatic brain injury. For the lower limb, contralateral L5 to S1 cross nerve transfer serves as a novel surgical approach. In many cases, patients with hemiplegia have both upper and lower limb dysfunction and hope to restore all limb functions within one operation. To cope with this demand, we performed combined contralateral C7 to C7 and L5 to S1 cross nerve transfer in two cases successfully.

Case description: Two patients were enrolled in this study. The first patient is a 36-year-old woman who had spasticity and hemiplegia in both upper and lower limbs on the left side after a right cerebral hemorrhage 14 years prior. The second patient is a 64-year-old man who suffered from permanent muscle weakness in his right limbs, especially the leg, after a left cerebral hemorrhage 7 years prior. Both patients underwent the combined nerve transfer to improve upper and lower limb motor functions simultaneously. During the 10-month follow-up after surgery, the limb functions of both patients improved significantly.

Conclusions: This study demonstrates the safety and benefits of combined contralateral C7 to C7 and L5 to S1 cross nerve transfer for hemiplegic patients after stroke. This novel combined surgical approach could provide an optimal choice for patients suffering from both upper and lower limb dysfunction, to reduce hospital stay while reducing financial burden.

ARTICLE HISTORY

Received 11 September 2020
Revised 20 March 2021
Accepted 25 March 2021

KEYWORDS

Motor dysfunction; nerve transfer; spastic hemiplegia; stroke

Introduction

Motor impairment is the most common disability after stroke,^{1–3} and approximately one-third of patients exhibit persistent disability.⁴ Although significant progress has been made over the past 20 years in improving neurological outcomes,^{5–8} recovery of limb function is limited. Nerve transfer serves as a novel strategy for the treatment of CNS pathology,⁹ among which the contralateral C7 to C7 cross nerve transfer has been verified to reduce spasticity and improve the function of the affected arm.^{10–12} In the meantime, the contralateral L5 to S1 cross nerve transfer has been reported to give significant functional improvements to affected legs for hemiplegic patients after stroke.¹³ Patients with hemiplegia caused by stroke have both arm and leg dysfunction simultaneously^{14,15} and hoping to improve all limb functions with one operation, we performed combined contralateral C7 to C7 and L5 to S1 cross nerve transfer. We present the first reports of this combined operation for the treatment of limb dysfunction in two patients with stroke and followed up the recovery of limb function for 10 months.

Case reports

Two patients were enrolled in this study and consented to participate in postoperative surveys for outcome assessment. Written

informed consent was gained from each participant, and the study was approved by the regional ethics committee.

Patient presentation

Case 1. A 36-year-old woman was examined in the limb function reconstruction center of our hospital. With a history of a right cerebral hemorrhage 14 years prior (Table 1). After 10 months of regular rehabilitation, there was no obvious further improvement of limb function, indicating a recovery plateau. She had severe spasticity in her left upper limb, especially in the wrist, metacarpophalangeal and interphalangeal joints, with a mean modified Ashworth score (MAS) of 2/5 and Fugl–Meyer upper-extremity scale of 28/66 (Table 2). The Medical Research Council (MRC) Grade of muscle strength for shoulder adduction/abduction and elbow flexion/extension were M4, while that of the wrist extension/palmar flexion was M1. The spasticity in the left lower limb was relatively mild, with a mean MAS score of 1/5 and the Berg Balance Scale (BBS) of 54/56 (Table 2). The patient could walk independently without crutches, but the left foot inversion was quite obvious when walking.

Case 2. A 64-year-old man was paralyzed on the right side after a left cerebral hemorrhage 7 years prior (Table 1). He underwent a regular rehabilitation program but achieved no

Table 1. Population and clinical data.

Patient number	Current age (years)	Sex	Time of injury (years)	Cause	Main symptom	Donor nerve (side)	Recipient nerve (side)
1	36	F	14	Right cerebral hemorrhage	Spasticity	C7 nerve (Right) 50% L5 (Right)	C7 nerve (Left) 50% S1 (Left)
2	64	M	7	Left cerebral hemorrhage	Muscle weakness	C7 nerve (Left) 50% L5 (Left)	C7 nerve (Right) 50% S1 (Right)

Table 2. Details of functional results.

Patient number	Time points	H-S grading*	Barthel Index	Berg	Fugl-Meyer Upper-Extremity Scale
1	Preoperation	IIb	95	54	28/66
	4 months postoperatively	III	100	56	48/66
	10 months postoperatively	III	100	56	52/66
2	Preoperation	III	50	17	51/66
	4 months postoperatively	III	60	30	58/66
	10 months postoperatively	IV	75	35	62/66

*H-S Grading: a simplified and standardized method for rapidly assessing upper limb function in spastic patients at the chronic stage.¹⁶

significant improvement after a year. He had spasticity in the right arm, mainly in the shoulder and elbow joints, with a mean MAS of 2/5. The range of motion (ROM) of upper limb joints was basically normal, except for the shoulder abduction was slightly limited, with active ROM from 0° to 110°. The MRC grades of the right upper limb muscles were M5 and the Fugl-Meyer upper-extremity scale was 51/66 (Table 2). Unlike the upper limb, the right lower limb experienced weakness and severe spasticity, with only MRC grade 2 strength or less and a mean MAS score of 3/5. He was confined to the wheelchair and could only be ambulated with a crutch or the help of others.

Surgical description

The operation was performed under general anesthesia and consisted of two stages, with the contralateral L5 to S1 cross nerve transfer conducted first. Similar to the previous study,¹⁷ a longitudinal midline incision was made at approximately the L5 level. Standard L5 and S1 laminectomy were performed and the ligamentum flavum was excised. The spinal dura was incised longitudinally and the L5 and S1 sacral roots were identified by anatomic localization and intraoperative electrophysiology. The anterior roots of the L5 nerve of the healthy side and S1 nerve of the paralyzed side were carefully separated respectively by microsurgical techniques. Then, 50% of the anterior root of the L5 nerve was transected as far as possible, while 50% of the anterior root of the S1 nerve was transected subdurally as close to the spinal cord as possible. The tension-free anastomosis was performed with a 9-0 prolene suture (1754G, Ethicon Inc, Johnson, Shanghai, China) by means of micro-surgical epineurium suturing (Figure 1). The posterior roots were carefully protected and remained intact during the operation. The dura was closed and no CSF leakage was observed. The instrumented fusion was performed to avoid instability at the lumbosacral junction, and the incision was closed in multiple layers. Immediately after surgery, a CT scan was obtained, demonstrating the good position of the bilateral pedicle screws (Figure 2).

After the contralateral L5 to S1 cross nerve transfer, contralateral C7 to C7 cross nerve transfer was performed in the supine position. The procedure has been described previously^{11,12} and is shown schematically in Figure 1. In brief, an incision was made above the sternum to expose bilateral brachial plexus nerves. Then the donor C7 nerve on the healthy side was mobilized, severed as distally as possible while proximal to the point at which it combines with other nerves, and pass through the pre-spinal route; it was then anastomosed directly with the C7 nerve on the

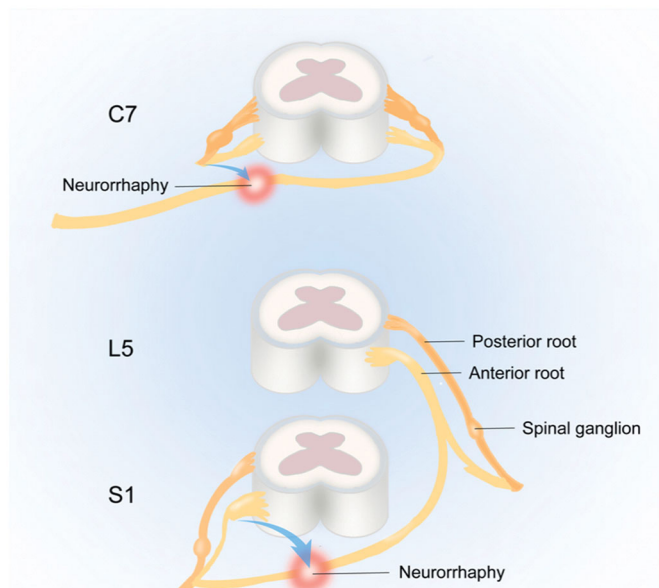


Figure 1. Schematic of the combined contralateral C7 and L5-S1 cross nerve transfer.

paralyzed side, which had been sectioned and mobilized as proximally as possible.

After surgery, the patient underwent flat bed rest for 7 days and the paralyzed upper extremity was immobilized with a hard cervical collar for 4 weeks.

Postoperative and extended recovery

Both cases were operated on within 7 h and intraoperative real-time monitoring showed that blood pressure, heart rate, breathing, body temperature, and other vital indicators were normal. There were no early complications such as wound infection and bleeding except mild soreness and discomfort on the unaffected side, which disappeared after 3 months, and no long-term complications were found during the follow-up of 10 months. The patient underwent regular rehabilitation in our hospital 1 month postoperatively, including early isometric muscle contraction training and gait training in the late stage. Patients were followed up in the outpatient clinic every 3 months. Follow-up indicators included limb muscle strength, range of motion, paresthesia, MAS, Fugl-Meyer upper-extremity scale, the activity of daily living (ADL) measured by the Barthel Index, Berg Balance Scale (BBS), and H-S Grading.¹⁶

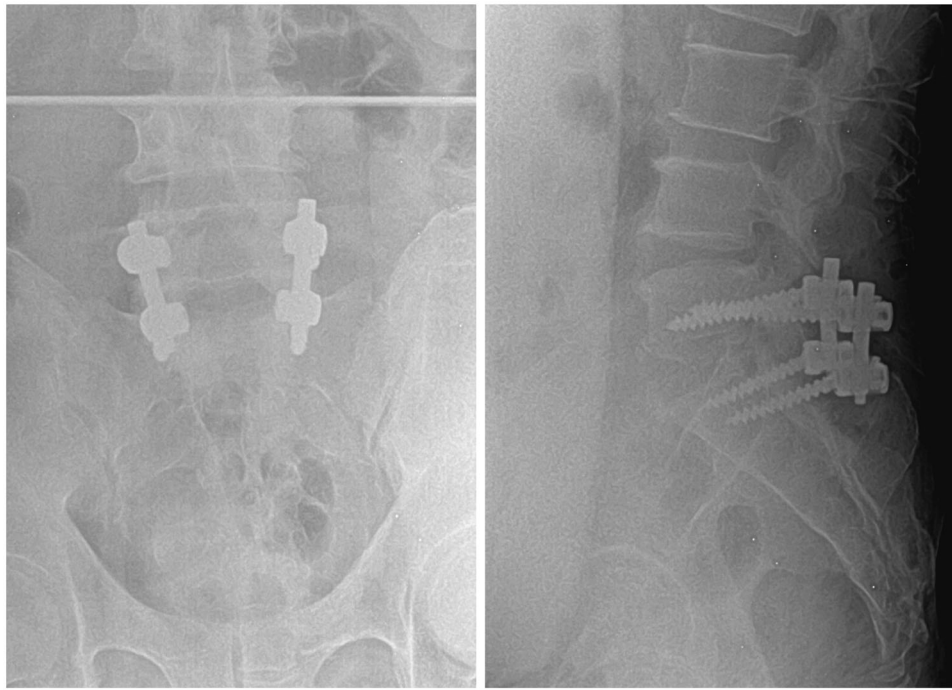


Figure 2. Case 2. Postoperative coronal CT (Left) and sagittal CT (Right) showing the internal fixation in the good position.

Both patients reported mild soreness and discomfort on the unaffected side, which disappeared after 3 months. Most of the motor functions of the unaffected limbs were not impaired after the operation, only the muscle strength decreased slightly but spontaneously recovered to the preoperative levels within 10 months.

The first patient showed a mild decrease in spasticity on the first day after the operation. At 4 months postoperatively, the MAS score of the upper limb reduced to 1/5. At 10 months after surgery, the muscle strength of the upper limbs increased, and the recovery of wrist extension/palmar flexion and finger flexion and extension was the most significant, reaching MRC grade 3. The spasticity of the lower limb was also reduced, the patients could trot independently at 10 months postoperatively, and the condition of left foot inversion during walking was also improved. Other detailed follow-up assessments are found in Table 2.

At 7 months after surgery, the active ROM of shoulder abduction of the second patient increased from 0° to 130°.

The motor function of the lower limb improved greatly, with muscle strength of hip extension, knee flexion and ankle plantar-flexion recovered to MRC grade 4 and the mean MAS score reduced to 1/5. This patient who was confined to bed and could only move with the help of others or a wheelchair before surgery could walk in small steps without armrests at 10 months after surgery. Other detailed follow-up assessments are found in Table 2.

At 7 months after surgery, the active ROM of shoulder abduction of the second patient increased from 0° to 130°.

The motor function of the lower limb improved greatly, with muscle strength of hip extension, knee flexion and ankle plantar-flexion recovered to MRC grade 4 and the mean MAS score reduced to 1/5. This patient who was confined to bed and could only move with the help of others or a wheelchair before surgery could walk in small steps without armrests at 10 months after surgery. Other detailed follow-up assessments are found in Table 2.

Discussion

How to recover limb dysfunction left after stroke has always been a significant issue, with little satisfactory countermeasure yet. Contralateral nerve cross transfer, a novel surgical strategy for the treatment of hemiplegia patients, has attracted attention for its effectiveness and relatively wide range of indications.^{5,18,19}

The two cases presented in this article have initially shown the safety and effectiveness of this combined surgery. Previous studies showed that following the spasticity release in the initial phase after the contralateral C7 to C7 cross nerve transfer, improvements in muscle power and motor function were most evident beginning at approximately 10 months postoperatively,¹² which might be related to the time course of the regeneration of nerve fibers to grow into the affected limb through the anastomosis site. Similarly, for patients who underwent the contralateral L5 to S1 cross nerve transfer, coordinated movement of the lower extremity muscles was first noticed approximately 16 months after surgery, following the initial phase of spasticity release.¹⁷ During the long recovery process, regular rehabilitation is essential to restore postoperative limb functions. For patients who are willing to perform these two operations, the combined surgery could restore the functions of the upper and lower limbs synchronously, thereby maximizing the time required for nerve regeneration. Also, simultaneous upper and lower limb rehabilitation training greatly reduces the time patients need to spend in rehabilitation clinics.

Compared with contralateral C7 to C7 or L5 to S1 cross nerve transfer alone, this combined surgery has greater potential in improving the gait and balance function of patients as stable and efficient locomotion requires the precise coordination of movement across the limbs and body.²⁰ Studies showed that reflexes between limbs are mediated by fast-conducting pathways that involve excitatory and inhibitory circuits controlling each limb,²¹ and there are strong interactions of locomotor output between cervical and lumbar central pattern generators (CPGs),^{22,23} which suggest that the movement of the upper limb could enhance

neuromuscular recruitment of the lower limb and vice versa. Based on the theory of interlimb neural coupling,²⁴ various rehabilitation strategies aimed at utilizing cervical-lumbar connectivity of patients after stroke have been adopted, and have effectively improved the walking ability.^{25,26} In case 1, the patient's upper and lower limb functions were improved simultaneously, which might be crucial for improving her balance for locomotion, allowing her to trot 10 months after surgery. In case 2, the patient improved from wheelchair-bound to independent walking at 10 months postoperatively, while in the previous study the coordinated movement of the lower extremity muscles was first noticed approximately 16 months for patients who underwent contralateral L5 to S1 cross nerve transfer alone.¹⁷ The metal internal fixation might also play a significant part here as it reduced the time of bed rest from 1 month to 1 week.

Considering that stroke is still the leading cause of neurological disability worldwide with increasing demand for treatment, rehabilitation, and support services,²⁷ and the age of hemiplegia after stroke has tended to be younger in recent years,²⁸ the good clinical outcomes reported in this article provide a promising strategy for these patients.

Conclusion

This study demonstrates the safety and benefits of combined contralateral C7 to C7 and L5 to S1 cross nerve transfer for hemiplegic patients after stroke. This novel combined surgical approach could provide an optimal choice for patients suffering from both upper and lower limb dysfunction, to reduce hospital stay while reducing financial burden.

Ethical approval

The authors confirm that the principles outlined in the Declaration of Helsinki were followed throughout this study.

Acknowledgments

The authors wish to acknowledge Xianggui-Chen, Gaowei-Lei MD for their help in data collection for this study.

Disclosure statement

The authors declare no potential conflicts of interest with respect to the research, authorship, and/or publication of this article.

Funding

This work was supported by National Natural Science Foundation of China [81972157, 81525009], Shanghai Top Priority Clinical Medicine Center Construction Project [2017ZZ01006], and Chinese Academy of Medical Sciences Research Fund [2018RU007].

References

- Spasticity LS. Motor recovery, and neural plasticity after stroke. *Front Neurol* 2017;8:1–8.
- Langhorne P, Coupar F, Pollock A. Motor recovery after stroke: a systematic review. *Lancet Neurol* 2009;8:741–54.
- Sakai K, Yasufuku Y, Kamo T, Ota E, Momosaki R. Repetitive peripheral magnetic stimulation for impairment and disability in people after stroke. *Cochrane Database Syst Rev* 2019;11:CD011968.
- Dimyan MA, Cohen LG. Neuroplasticity in the context of motor rehabilitation after stroke. *Nat Rev Neurol* 2011;7:76–85.
- Lin DJ, Finklestein SP, Cramer SC. New directions in treatments targeting stroke recovery. *Stroke* 2018;49:3107–14.
- Zhang ZG, Buller B, Chopp M. Exosomes - beyond stem cells for restorative therapy in stroke and neurological injury. *Nat Rev Neurol* 2019;15:193–203.
- Cook DJ, Teves L, Tymianski M. Treatment of stroke with a PSD-95 inhibitor in the gyrencephalic primate brain. *Nature* 2012;483:213–7.
- Kalladka D, Muir KW. Brain repair: cell therapy in stroke. *Stem Cells Cloning Adv Appl* 2014;7:31–44.
- Midha R, Grochmal J. Surgery for nerve injury: current and future perspectives. *J Neurosurg* 2019;130:675–85.
- Xu W-D, Hua X-Y, Zheng M-X, Xu J-G, Gu Y-D. Contralateral C7 nerve root transfer in treatment of cerebral palsy in a child: case report. *Microsurgery* 2011;31:404–8.
- Hua XY, Qiu YQ, Li T, et al. Contralateral peripheral neurotization for hemiplegic upper extremity after central neurologic injury. *Neurosurgery* 2015;76:187–95.
- Zheng MX, Hua XY, Feng JT, et al. Trial of contralateral seventh cervical nerve transfer for spastic arm paralysis. *N Engl J Med* 2018;378:22–34.
- Yu BF, Qiu YQ, Du MX, et al. Contralateral hemi-fifth-lumbar nerve transfer for unilateral lower limb dysfunction due to incomplete traumatic spinal cord injury: a report of two cases. *Microsurgery* 2020;40:234–40.
- Lundström E, Smits A, Terént A, Borg J. Time-course and determinants of spasticity during the first six months following first-ever stroke. *J Rehabil Med* 2010;42:296–301.
- Katoozian L, Tahan N, Zoghi M, Bakhshayesh B. The onset and frequency of spasticity after first ever stroke. *J Natl Med Assoc* 2018;110:547–52.
- Wang G-B, Qiu Y-Q, Ying Y, et al. Simple grading for motor function in spastic arm paralysis: Hua-Shan grading of upper extremity. *J Stroke Cerebrovasc Dis off J Natl Stroke Assoc* 2019;28:2140–7.
- Qiu YQ, Du MX, Yu BF, et al. Contralateral lumbar to sacral nerve rerouting for hemiplegic patients after stroke: a clinical pilot study. *World Neurosurg* 2019;121:12–8.
- Wilson TJ. Novel uses of nerve transfers. *Neurotherapeutics* 2019;16:26–35.
- Krucoff MO, Miller JP, Saxena T, et al. Toward functional restoration of the central nervous system: a review of translational neuroscience principles. *Neurosurgery* 2019;84:30–40.
- Darmohray DM, Jacobs JR, Marques HG, Carey MR. Spatial and temporal locomotor learning in mouse cerebellum. *Neuron* 2019;102:217–31.
- Hurteau M-F, Thibaudier Y, Dambreville C, Danner SM, Rybak IA, Frigon A. Intralimb and interlimb cutaneous reflexes during locomotion in the intact cat. *J Neurosci* 2018;38:4104–22.
- Harnie J, Doelman A, de Vette E, et al. The recovery of standing and locomotion after spinal cord injury does not require task-specific training. *Elife* 2019;8:e50134.
- Danner SM, Wilshin SD, Shevtsova NA, Rybak IA. Central control of interlimb coordination and speed-dependent gait expression in quadrupeds. *J Physiol* 2016;594:6947–67.
- Arya KN, Pandian S. Interlimb neural coupling: implications for post-stroke hemiparesis. *Ann Phys Rehabil Med* 2014;57:696–713.
- Barss TS, Parhizi B, Mushahwar VK. Transcutaneous spinal cord stimulation of the cervical cord modulates lumbar networks. *J Neurophysiol* 2020;123:158–66.
- Kaupp C, Pearcey GEP, Klarner T, et al. Rhythmic arm cycling training improves walking and neurophysiological integrity in chronic stroke: the arms can give legs a helping hand in rehabilitation. *J Neurophysiol* 2018;119:1095–112.
- Feigin VL, Nichols E, Alam T, et al. Global, regional, and national burden of neurological disorders, 1990–2016: a systematic analysis for the Global Burden of Disease Study 2016. *Lancet Neurol* 2019;18:459–80.
- Wang J, Bai L, Shi M, et al. Trends in age of first-ever stroke following increased incidence and life expectancy in a low-income Chinese population. *Stroke* 2016;47:929–35.