

# Intraoperative Seizure Detection During Active Resection of Glioblastoma Through a Novel Hollow Circular Electroencephalography Array

Ricardo A. Domingo, MD <sup>\*</sup>  
 Tito Vivas-Buitrago, MD <sup>\*</sup>  
 Gaetano De Biase, MD <sup>\*</sup>  
 Erik H. Middlebrooks, MD<sup>\*‡</sup>  
 Perry S. Bechtel, DO<sup>§</sup>  
 David S. Sabsevitz, PhD<sup>\*¶</sup>  
 Alfredo Quiñones-Hinojosa, MD <sup>\*</sup>  
 William O. Tatum, DO<sup>||</sup>

<sup>\*</sup>Department of Neurologic Surgery, Mayo Clinic, Jacksonville, Florida, USA; <sup>‡</sup>Department of Radiology, Mayo Clinic, Jacksonville, Florida, USA; <sup>§</sup>Department of Anesthesiology and Perioperative Medicine, Mayo Clinic, Jacksonville, Florida, USA; <sup>¶</sup>Department of Psychiatry and Psychology, Mayo Clinic, Jacksonville, Florida, USA; <sup>||</sup>Department of Neurology, Mayo Clinic, Jacksonville, Florida, USA

## Correspondence:

Alfredo Quiñones-Hinojosa, MD,  
 Brain Tumor Stem Cell Laboratory,  
 Department of Neurologic Surgery,  
 Mayo Clinic,  
 4500 San Pablo Rd S,  
 Jacksonville, FL 32224, USA.  
 Email: [quinones@mayo.edu](mailto:quinones@mayo.edu)

Received, September 21, 2020.

Accepted, February 8, 2021.

© Congress of Neurological Surgeons  
 2021. All rights reserved.  
 For permissions, please e-mail:  
[journals.permissions@oup.com](mailto:journals.permissions@oup.com)

**BACKGROUND AND IMPORTANCE:** Data supporting the use of electrocorticography (ECoG) monitoring during electrical stimulation in awake craniotomies for resection of supratentorial neoplasms is robust, but its applicability during active resection is often limited by the inability to keep the array in place. Given the known survival benefit of gross total resection in glioma surgery, novel approaches to surgical monitoring are warranted to maximize safe resection and optimize surgical outcomes in patients with glioblastoma.

**CLINICAL PRESENTATION:** A 68-yr-old right-handed woman presented to the emergency department with confusion. Imaging studies revealed a bifrontal intra-axial brain lesion. She underwent a left-sided awake craniotomy procedure with cortical and subcortical mapping. During surgical resection, multiple electrographic seizures were detected on continuous ECoG monitoring with a customized 22-channel high-density hollow circular array. She remained without clinical evidence of seizures at 3 mo after surgery.

**CONCLUSION:** We report a unique case of serial electrographic seizures detected during continuous intraoperative ECoG monitoring during active surgical resection of a glioblastoma using a novel circular hollow array during an awake craniotomy. The use of continuous ECoG monitoring during active resection may provide additional data, with potential influence in outcomes for patients undergoing resection of high-grade glial neoplasms.

**KEY WORDS:** Awake craniotomy, Circular array, Continuous electrocorticography, ECoG, Glioblastoma, Seizure

*Operative Neurosurgery* 0:1–6, 2021

DOI: 10.1093/ons/opab110

Seizures and after-discharges (ADs) can often limit the interpretation of results from functional brain mapping during awake craniotomies for intra-axial tumor resection, preventing proper identification of eloquent regions.<sup>1–4</sup>

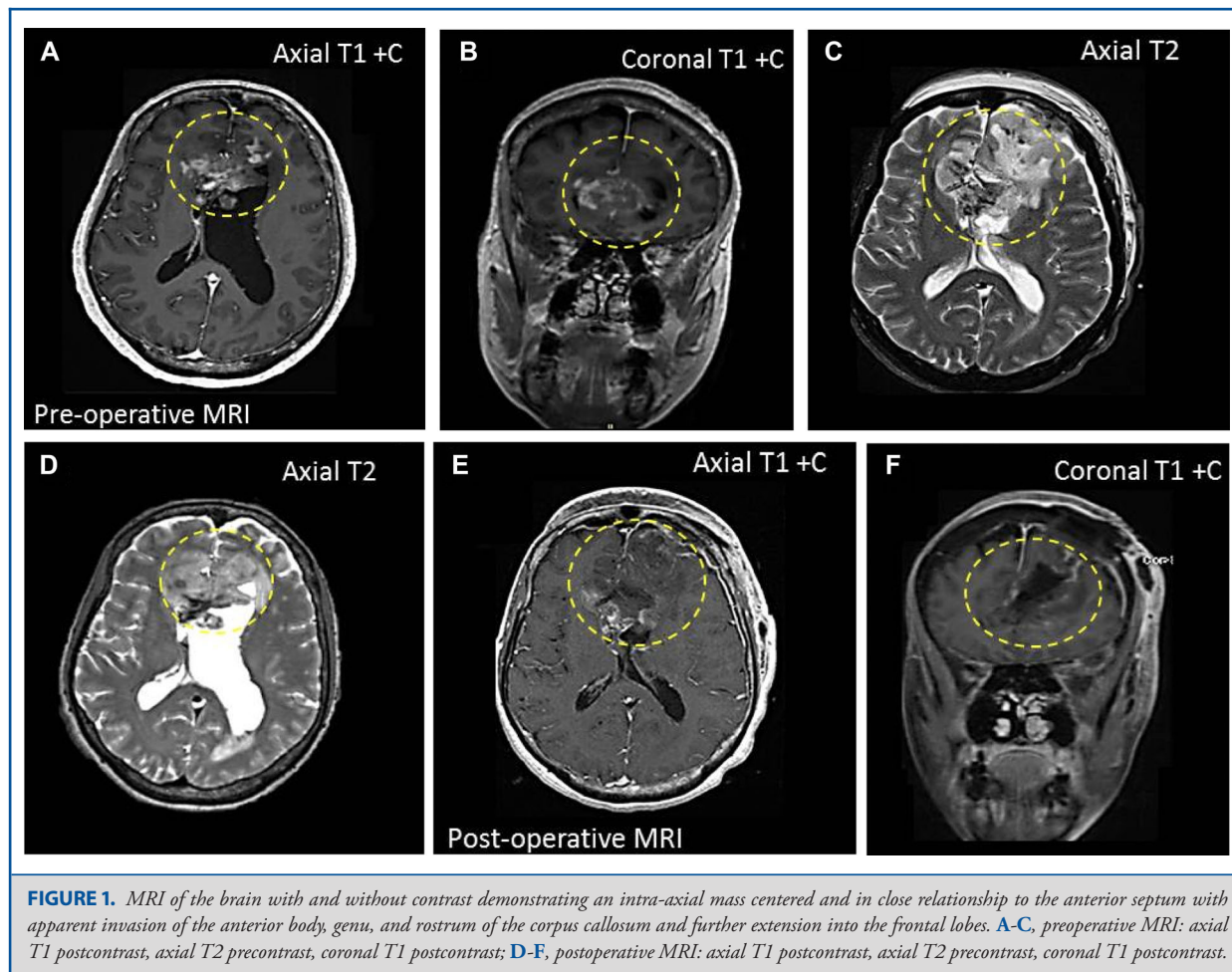
The applicability of electrocorticography (ECoG) is often limited to stimulation mapping, whereas its use during ongoing resection is understudied.<sup>5–8</sup> Recently, our group developed a novel, high-density, hollow, 360° circular array (PCT/US2018/039956), allowing us to maintain the array placed around the surgical corridor while operating through the interior aperture, monitoring for electrical abnormalities throughout the resection.<sup>9–11</sup>

**ABBREVIATIONS:** ADs, after-discharges; **BOLD**, blood oxygenation level dependent; **ECoG**, electrocorticography; **IDH**, isocitrate dehydrogenase;

The use of our novel array has demonstrated detection of new focal epileptiform activity, earlier detection of after-discharges (ADs)<sup>12</sup>, and favorable outcomes due to improved detection of electrographic abnormalities during mapping.<sup>13–15</sup> We present a case of detection of multiple electrographic seizures on continuous ECoG monitoring during active resection of a glioblastoma in a 68-yr-old woman without history of seizures.

## CLINICAL PRESENTATION

A 68-yr-old, right-handed, bilingual woman presented with acute confusion, aphasia, and disorientation in time and place. Head computed tomography (CT) scan showed a bifrontal intra-axial lesion. Retrospectively, her family noted mild cognitive changes and imbalance for ~4 mo. There was no reported history of seizures



or focal neurological deficits noted during physical examination. Neuropsychological testing detected executive dysfunction, with preserved speech/language except for mild word-finding difficulty. Magnetic Resonance Imaging (MRI) demonstrated a partially contrast-enhancing intra-axial mass in close relationship to the anterior septum with extension to the anterior body, genu, and rostrum of the corpus callosum and into the frontal lobes, including the anterior cingulate cortex bilaterally. The lateral ventricles were mildly enlarged with a 5-mm left-to-right midline shift (Figure 1). Differential diagnosis included central neurocytoma vs glial neoplasm. On functional MRI, she had strong left hemispheric language dominance for Spanish (native language), with bilateral frontal activation for English (non-native language) (Figure 2).

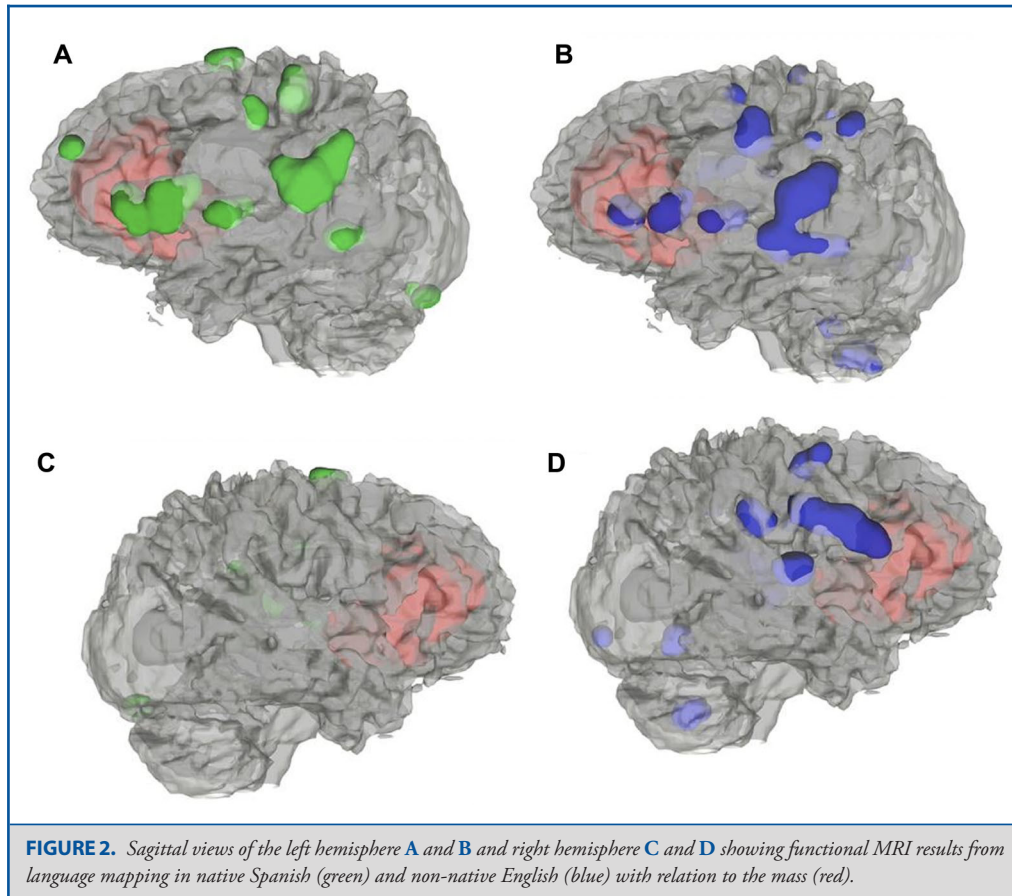
### Operative Details

Patient underwent a left-sided awake craniotomy with cortical/subcortical mapping. Informed consent was obtained, Institutional Review Board (IRB) approval was waived given the fact that this is a case report. Bilateral ultrasound-guided greater

occipital nerve and scalp blocks with 0.5% ropivacaine were performed preoperatively, with supplemental doses of fentanyl during the procedure. Infusion of propofol and dexmedetomidine were used to a light sedation state during craniotomy and discontinued upon dura exposure to achieve a comfortable, wide-awake state for the remainder of the procedure, as well as IV 100 mg of levetiracetam intraoperatively for seizure prophylaxis.<sup>16-18</sup> A left-sided curvilinear incision, myocutaneous flap, and left frontal craniotomy were performed. The dura was opened in a cruciate fashion and the circular array was placed for ECoG monitoring (Figure 3).

### Functional Brain Mapping and ECoG Monitoring

Our novel circular array was utilized for monitoring. Passive ECoG was recorded for 5 min. During functional mapping with an OCS2 Ojemann cortical stimulator (Integra LifeSciences) for a total of 31 min, ADs recurred during electrical stimulation at 3 milliamps at 18 min, reflecting regional electrical hyperexcitability of the frontal neocortices posteriorly. These ADs



lasted 3 to 11 s, resolving spontaneously (Figure 4). Stimulation mapping revealed an area of language representation in which object naming in Spanish was disrupted located anteriorly and corresponding to an area of BOLD activation of the middle frontal gyrus during functional MRI.

### Surgical Monitoring

ECoG continued throughout the surgical resection lasting for 1:16 h. During deep tumor resection through the grid, a prolonged focal seizure was identified at the posterior-inferior electrodes with increasing amplitude and spreading to the anterior-superior electrodes, lasting ~8 min. Two additional seizures were recorded ~46 min into resection: 1 localized at the eloquent cortex identified (anterior-superior electrodes) lasting for 17 s, and another seizure located posterior-inferiorly lasting 3 min (Figure 4). All episodes were detected during active resection of the tumor without electrical stimulation and resolved without clinical manifestations. Postictal attenuations were noted in each event. Cognitive monitoring continued during resection with the patient performing at her presurgical baseline.

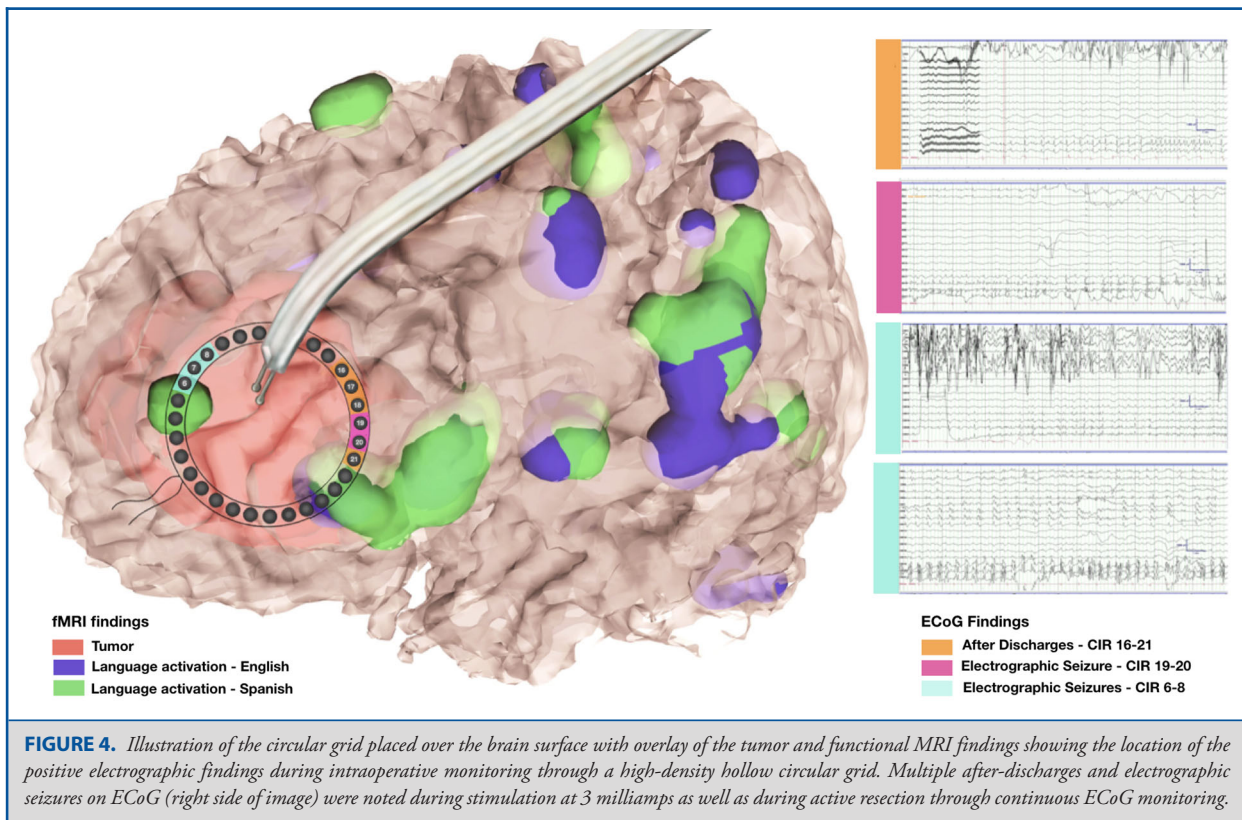
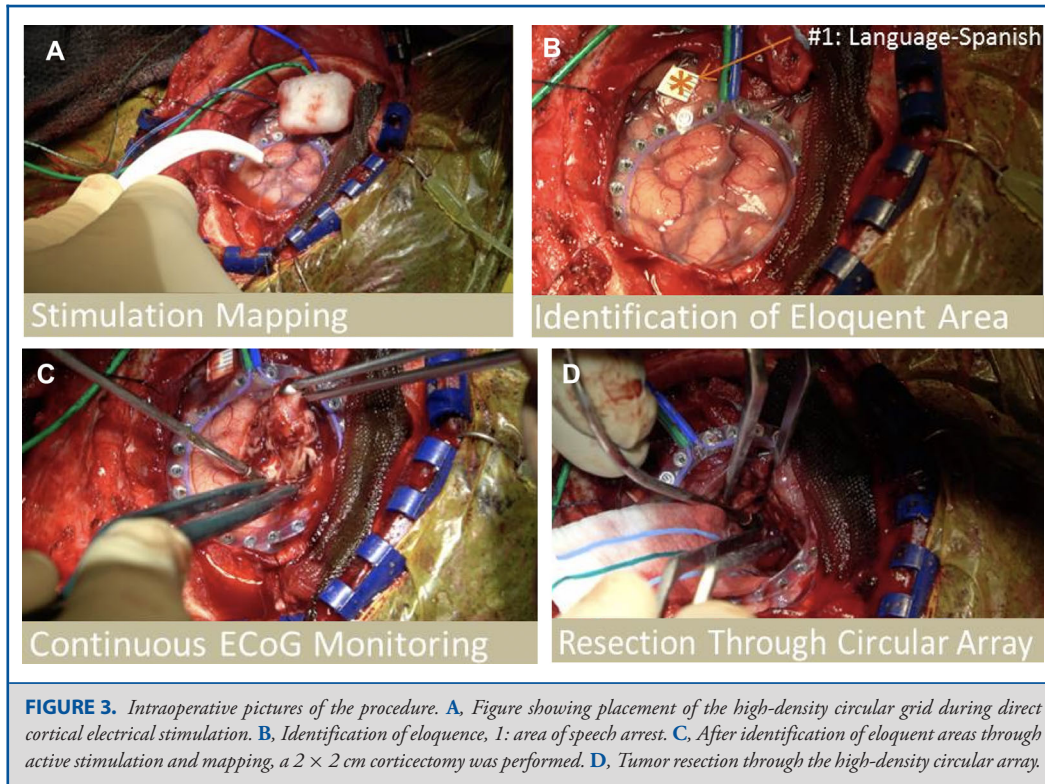
### Postoperative Course

Final pathology was consistent with glioblastoma (isocitrate dehydrogenase [IDH] wildtype and O<sup>6</sup>-methylguanine-DNA methyltransferase (MGMT) nonhypermethylated). She was treated with 100 mg of phenytoin twice daily during hospitalization. The patient was discharged on postoperative day #4. Adjuvant radiation and chemotherapy was subsequently initiated. At 3-mo follow-up, MRI showed subtotal resection with residual tumor along the medial aspect of the right frontal lobe. She remained seizure-free and reported cognitive improvement.

### DISCUSSION

The ability to detect seizures during brain surgery is critical to patient safety. In glioma-related epilepsy, perioperative seizures increase morbidity, especially when prolonged.<sup>16</sup> Subclinical seizures have been noted in ~50% of critically ill glioma patients, which may produce neurocognitive deficits.<sup>19,20</sup> Using our novel circular array, we monitored ECoG through active tumor resection, identifying recurrent seizures (including a prolonged focal seizure) with no evident clinical manifestation.





The inability to keep the array in place as the surgeon expands the surgical corridor represent a challenge when monitoring during resection, often compromising the quality of the data obtained as the grid is frequently repositioned by the surgeon; this is especially true in large infiltrative lesions such as in our patient.<sup>20-22</sup> The recent development of a hollow circular array allows to monitor during resection through the grid in selected cases, obtaining additional data, and as illustrated, detecting electrographic seizures.<sup>23,24</sup>

Frequent activation of the nondominant frontal operculum is often seen with non-native languages, particularly when fluency is limited, likely due to increased activation of frontal attention networks given the complexity of the task.<sup>13,19-21,25</sup> Our patient did not report preoperative seizures; however, we cannot exclude focal impaired-awareness seizures given her initial presentation of sudden onset of confusion and aphasia. Despite the occurrence of intraoperative seizures, the patient remained asymptomatic during the procedure and seizure-free postoperatively, though subtle effects could not be excluded. Interestingly, a seizure was detected at the identified functional area for language, providing potential useful information to confound neuropsychological testing with unreliable results due to a subtle seizure.

Our findings illustrate the feasibility of a novel application for continuous ECoG monitoring during active resection of an intra-axial neoplasm through the hollow aperture of the circular electrode grid array. The detection of electrographic seizures during resection may help prevent clinically relevant events through abortive techniques such as cold saline irrigation and intraoperative administration of antiseizure drugs to limit intraoperative consequences of breakthrough motor seizures during awake craniotomy. It also provides additional information that may help the neurosurgeon tailor surgical resection, interpret behavioral and cognitive fluctuation, modify postoperative management, and potentially predict future outcomes as a result of enhanced ability to detect intraoperative seizures. However, the applicability of our findings is limited by a single case, and as more cases are monitored, we speculate its role during resection and influence in outcomes will be elucidated.

## CONCLUSION

We report a unique case of serial seizures detected through continuous ECoG monitoring during active resection of a glioblastoma using a novel circular array. Increasing our ability to detect seizures through continuous ECoG during active resection may provide additional data to help guide resection and potentially predict postoperative outcomes.

## Funding

Dr Quiñones-Hinojosa was supported by the Mayo Clinic Professorship and a Clinician Investigator award, Florida State Department of Health Research Grant, and the Mayo Clinic Graduate School, as well as the NIH (R43CA221490, R01CA200399, R01CA195503, and R01CA216855).

## Disclosures

The authors have no personal, financial, or institutional interest in any of the drugs, materials, or devices described in this article. Drs Tatum and Quiñones-Hinojosa have a patent pending for the circular grid, no. PCT/US2018/039 956, support by Mayo Clinic Advance the Practice Research Award.

## REFERENCES

- Kovelman I, Baker SA, Petitto L-A. Bilingual and monolingual brains compared: a functional magnetic resonance imaging investigation of syntactic processing and a possible "neural signature" of bilingualism. *J Cogn Neurosci*. 2008;20(1):153-169.
- Eseonu CI, Rincon-Torroella J, ReFaey K, et al. Awake craniotomy vs craniotomy under general anesthesia for perirolandic gliomas: evaluating perioperative complications and extent of resection. *Neurosurgery*. 2017;81(3):481-489.
- Yamao Y, Matsumoto R, Kunieda T, et al. Intraoperative dorsal language network mapping by using single-pulse electrical stimulation. *Hum Brain Mapp*. 2014;35(9):4345-4361.
- Yuan Y, Peizhi Z, Xiang W, et al. Intraoperative seizures and seizures outcome in patients undergoing awake craniotomy. *J Neurosurg Sci*. 2016;63(3):301-307.
- Eseonu CI, Rincon-Torroella J, Lee YM, et al. Intraoperative seizures in awake craniotomy for perirolandic glioma resections that undergo cortical mapping. *J Neurol Surg A: Cent Eur Neurosurg*. 2018;79(03):239-246.
- Nossek E, Matot I, Shahar T, et al. Intraoperative seizures during awake craniotomy: incidence and consequences: analysis of 477 patients. *Neurosurgery*. 2013;73(1):135-140.
- Domingo RA, Vivas-Buitrago T, Sabsevitz DS, et al. Awake craniotomy with cortical and subcortical speech mapping for supramarginal cavernoma resection. *World Neurosurg*. 2020;141:260.
- ReFaey K, Chaichana KL, Feyissa AM, et al. A 360° electronic device for recording high-resolution intraoperative electrocorticography of the brain during awake craniotomy. *J Neurosurg*. 2019;133(2):443-450.
- Tatum WO, McKay JH, ReFaey K, et al. Detection of after-discharges during intraoperative functional brain mapping in awake brain tumor surgery using a novel high-density circular grid. *Clin Neurophysiol*. 2020;131(4):828-835.
- Tatum WO, Feyissa AM, ReFaey K, et al. Periodic focal epileptiform discharges. *Clin Neurophysiol*. 2019;130(8):1320-1328.
- Berger M. Minimalism through intraoperative functional mapping. *Clin Neurosurg*. 1996;43:324-337.
- Roux F-E, Lubrano V, Lauwers-Cances V, et al. Intra-operative mapping of cortical areas involved in reading in mono- and bilingual patients. *Brain*. 2004;127(8):1796-1810.
- Costello T. Awake craniotomy and multilingualism: language testing during anaesthesia for awake craniotomy in a bilingual patient. *J Clin Neurosci*. 2014;21(8):1469-1470.
- Eseonu CI, ReFaey K, Garcia O, et al. Awake craniotomy anesthesia: a comparison of the monitored anesthesia care and asleep-awake-asleep techniques. *World Neurosurg*. 2017;104:679-686.
- Gruenbaum SE, Meng L, Bilotta F. Recent trends in the anesthetic management of craniotomy for supratentorial tumor resection. *Curr Opin Anaesthesiol*. 2016;29(5):552-557.
- Chang EF, Potts MB, Keles GE, et al. Seizure characteristics and control following resection in 332 patients with low-grade gliomas. *J Neurosurg*. 2008;108(2):227-235.
- Claassen J, Mayer S, Kowalski R, et al. Detection of electrographic seizures with continuous EEG monitoring in critically ill patients. *Neurology*. 2004;62(10):1743-1748.
- Feyissa AM, Worrell GA, Tatum WO, et al. Potential influence of IDH1 mutation and MGMT gene promoter methylation on glioma-related preoperative seizures and postoperative seizure control. *Seizure*. 2019;69:283-289.
- Bello L, Acerbi F, Giussani C, et al. Intraoperative language localization in multilingual patients with gliomas. *Neurosurgery*. 2006;59(1):115-125.
- Abutaleb J, Annoni J-M, Zimine I, et al. Language control and lexical competition in bilinguals: an event-related fMRI study. *Cereb Cortex*. 2008;18(7):1496-1505.
- Bilotta F, Stazi E, Delfini R, et al. Language testing during awake "anesthesia" in a bilingual patient with brain lesion adjacent to Wernicke's area. *Anesth Analg*. 2011;112(4):938-939.

22. Giussani C, Roux F-E, Lubrano V, et al. Review of language organisation in bilingual patients: what can we learn from direct brain mapping? *Acta Neurochir (Wien)*. 2007;149(11):1109-1116.
23. Halsband, U. Bilingual and multilingual language processing. *J Physiol-Paris*. 2006;99(4-6):355-369.
24. Hernandez AE, Dapretto M, Mazziotta J, et al. Language switching and language representation in Spanish-English bilinguals: an fMRI study. *Neuroimage*. 2001;14(2):510-520.
25. ReFaey K, Tripathi S, Bhargav AG, et al. Potential differences between monolingual and bilingual patients in approach and outcome after awake brain surgery. *J Neurooncol*. 2020;148(3):587-598.

## COMMENT

The authors highlight the use of a novel circular ECoG array during resection of a bifrontal glioblastoma. The current manuscript emphasizes the ability to detect subclinical seizures during craniotomy and is highly relevant to clinical situations. Though the concept of continuous ECoG monitoring has been applied for several years, the authors provide the reader with their experience using a novel circular

grid and have expanded upon the advantages compared to the traditional, conventional grid. This manuscript adds to our current understanding of applications of ECoG monitoring and demonstrates the ability to detect electrographic seizures during a resection of bifrontal GBM. Ultimately the technology described by the authors also holds promise to potentially predict outcomes and impact post-operative management and could pave the way for future studies.

There is currently a paucity of literature describing experiences utilizing this novel circular grid. The future of this promising technology will involve applying it directly to a multitude of brain pathologies in order to accurately detect electrographic seizures and predict functional outcomes. As the field of neurosurgery continues to be influenced by advances in technology, we will continue to see optimization of technology such as in this manuscript.

**Neil D. Almeida**

*Washington, District of Columbia, USA*

**Jonathan H. Sherman**

*Martinsburg, West Virginia, USA*