

Dystypia Associated with Diaschisis of the Middle Frontal Gyri after Left Angular Infarction

Kengo Maeda, MD, PhD,[‡] Yutaka Yamamoto, MD,* Tomoyuki Shiraishi, ST,[†] and Eriko Fujioka, ST^{†1}

Dystypia without aphasia, agraphia, or apraxia is a rare symptom and has been suggested to result from a lesion in the left middle frontal cortex. We herein describe a man with dystypia with agraphia due to infarction of the left angular gyrus. His dystypia seemed to result from the convergence failure of the kana into the alphabetical spellings. During dystypia, hypoperfusion of the bilateral middle frontal cortices was discovered. However, after his symptoms improved, blood flow in the middle frontal cortices returned to normal. This case suggests that the middle frontal cortex is downstream of the angular gyrus in the dictating pathway and a lesion in the left middle frontal cortex could cause pure dystypia.

Key Words: Dystypia—Middle frontal gyrus—Angular gyrus—Diaschisis

© 2021 Elsevier Inc. All rights reserved.

Case report

A left-handed 53-year-old man presented with convulsion starting from his right hand and spreading to the whole body. Although he could type in a blind touch manner previously, since the day before his admission, he experienced a fluctuating difficulty in typing. He was alert on arrival. There was neither hemiparesis, sensory disturbance, cerebellar ataxia, nor apraxia. Although he did not show aphasia or alexia in standard language test of aphasia, he could not register words in the Japanese or English languages. He also showed difficulty in converting Japanese *kana* (syllabogram) to alphabetical spellings, which is necessary for typing Japanese words on a computer. When he types Japanese, he uses

‘alphabetic input’. For example, when the kana character ‘ha’ is produced, he types ‘h’ followed by ‘a’ (see the Table 1 of the Ref. [1]). He could not answer easy mathematical calculations correctly. Diffusion-weighted magnetic resonance (MR) imaging revealed a subcortical hyperintense lesion on the left angular gyrus (Fig. 1A). MR angiography showed moderate stenosis of the left middle cerebral artery (Fig. 1B). Single-photon emission computed tomography (SPECT) on the fifth day showed hyperperfusion of the left angular gyrus (Fig. 1C) and hypoperfusion of the bilateral middle frontal gyri (Fig. 1D). His symptoms (agraphia, dystypia, and acalculia) improved within 10 days. Abnormalities in SPECT disappeared one month after onset (Fig. 1E, F).

Discussion

In this case, the left angular infarction caused early convulsions, agraphia, acalculia, and dystypia. Hyperperfusion of the left angular lesion suggested reperfusion. Diaschisis of the bilateral middle frontal gyri by a left angular lesion has not been reported previously. However, fiber connection between them is supported by another case.² According to the hypothesis of the dictating pathway,³ the phonological stimulations are conveyed from the primary auditory cortex to the left angular gyrus. This information is further transported to the left premotor hand area probably via the arcuate fasciculus.

From the *Department of Neurology, Shiga University of Medical Science, Seta-Tsukinowa, Otsu, Shiga 520-2192, Japan; †Department of Neurology, National Hospital Organization Higashi-ohmi General Medical Center, 255 Gochi, Higashi-ohmi, Shiga 527-8505, Japan; and ‡Department of Neurology, Vories Memorial Hospital, 492 Kitanocho, Omi-hachiman, Shiga 523-8523, Japan.

Received October 1, 2020; revision received March 11, 2021; accepted March 28, 2021.

Corresponding author. E-mail: maeda@vories.or.jp.

¹Eriko Fujioka is a speech therapist of the National Hospital Organization Higashi-ohmi General Medical Center.

1052-3057/\$ - see front matter

© 2021 Elsevier Inc. All rights reserved.

<https://doi.org/10.1016/j.jstrokecerebrovasdis.2021.105803>

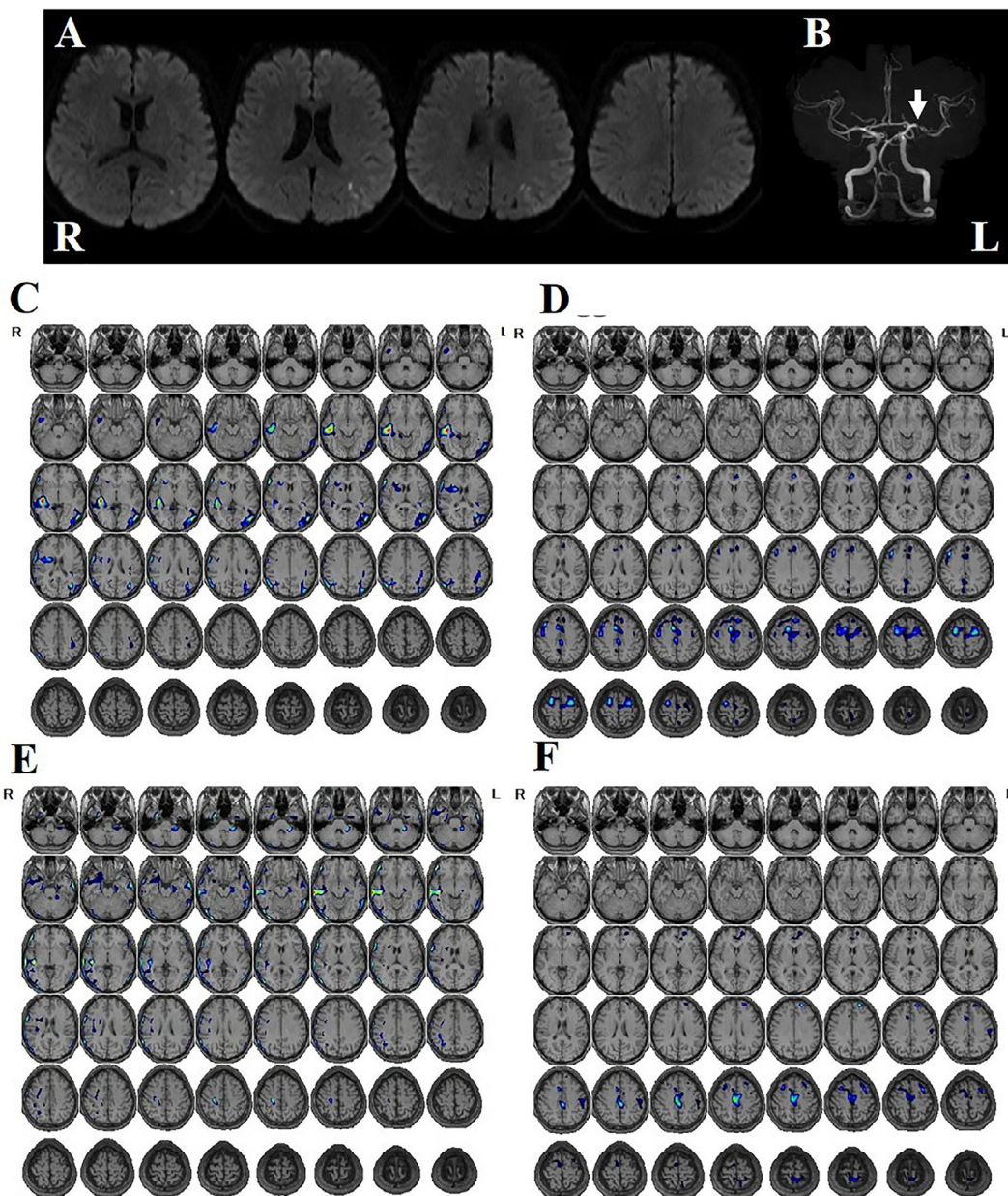


Fig. 1. A: Diffusion-weighted magnetic resonance imaging of the patient. A subcortical hyperintense spot is found at the left angular gyrus. B: Magnetic resonance angiography of the intracranial arteries. Stenosis of the left middle cerebral artery was observed (arrow). C–F: Single photon emission computed tomography using *N*-isopropyl-*p*- ^{123}I iodoamphetamine performed on day 5 of hospital stay (C, D) and one month after onset (E, F). Data are analyzed with the Easy Z-score imaging system. Hyperperfusion with Z-score >2 (C, E) and hypoperfusion with Z-score >2 (D, F) are colored.

Meanwhile, dystypia without aphasia, agraphia, or apraxia was reported in a case of left cerebral infarction involving the foot of the second frontal convolution and frontal operculum.⁴ The shared lesion topography of six cases presenting dystextia or dysptypia was reported to be the left posterior upper insular cortex and superior longitudinal fasciculus.⁵ In our case, typing impairment was due to disturbed conversion of *kana* to alphabetical spelling.⁶ However, if the middle frontal gyrus is downstream of the left angular gyrus in the dictating pathway, and the handwriting and typing pathways are branched from the middle frontal gyrus, a small frontal lesion could cause dystypia

without agraphia. Unlike writing by hand, typing requires bilateral hand movement. The signal for typing would be transferred to the non-dominant hemisphere at the level of the middle frontal gyrus via the corpus callosum.

References

1. Maeda K, Shiraishi T. Revival of historical *kana* orthography in a patient with allographic agraphia. *Intern Med* 2018;57:745-750.
2. Ando Y, Sawada M, Morita M, et al. Incomplete Gerstmann syndrome with a cerebral infarct in the left middle frontal gyrus. *Rinsho Shinkeigaku Clin Neurol* 2009;49:560-565.

3. Sakurai Y, Onuma Y, Nakazawa G, et al. Parietal dysgraphia: characterization of abnormal writing stroke sequences, character formation and character recall. *Behav Neurol* 2007;18:99-114.
4. Otsuki M, Soma Y, Arihiro S, et al. Dystypia: isolated typing impairment without aphasia, apraxia or visuospatial impairment. *Eur Neurol* 2002;47:136-140.
5. Sharma AK, Fridman S, Gleichgerrcht E, et al. Dystextia and dystypia as modern stroke symptoms: a case series and literature review. *Clin Neurol Neurosurg* 2019;180:25-27.
6. Suzuki Y, Inatomi Y, Yonehara T, et al. Dystypia after ischemic stroke: a disturbance of linguistic processing for Romaji (Romanized Japanese)? *Rinsho Shinkeigaku Clin Neurol* 2015;55:8-12.