



Correspondence

MR Imaging Findings in a Neonate With COVID -19-Associated Encephalitis



COVID-19 continues to wreak havoc in many parts of the world. Many children with COVID-19 are asymptomatic or have milder symptoms compared with adults. Neurological symptoms and neuroimaging abnormalities in children with COVID-19 disease are frequently due to parainfectious immune-mediated phenomena or thromboembolic disease and include acute disseminated encephalomyelitis (ADEM), autoimmune encephalitis, Guillain-Barré syndrome, acute flaccid paralysis, myelitis, cranial nerve enhancement, vascular territory infarcts, and microhemorrhages.^{1,2} There are reports of pediatric and neonatal COVID-19 encephalopathy, but these cases have had normal neuroimaging.^{3,4}

We describe a nine-day-old COVID-19 positive boy who presented at six days old with seizures and magnetic resonance imaging (MRI) findings that were suggestive of viral encephalitis. He was born at term without complications. A head computed tomography revealed minimal subdural hematoma attributable to normal parturition. Electroencephalography (EEG) revealed poor sleep state differentiation without epileptiform discharges, which normalized on follow-up. Lumbar puncture on day of admission revealed cerebrospinal fluid (CSF) xanthochromia, red blood cells 9825/cumm, total nucleated cells 0/cumm; elevated protein (69 mg/dL), and normal glucose (53 mg/dl). CSF meningoencephalitis panel was negative, and CSF culture revealed no growth. CSF panel did not include COVID-19.

A nasopharyngeal COVID-19 polymerase chain reaction (PCR) test on day of life seven due to mild desaturations was positive. The patient's grandmother tested positive for COVID-19. In retrospect, parents had influenza-like symptoms with loss of taste and smell at that time but were not tested in the acute setting. Brain MRI performed at nine days of age revealed foci of restricted diffusion in the periventricular white matter and the corpus callosum (Fig) with corresponding heterogeneous T2-weighted signal, compatible with a viral encephalitis.⁵ There was no hemorrhage or abnormal enhancement.

The patient's seizures and hypoxia resolved with antiepileptics and minimal supplemental oxygen. The patient was discharged with normal vitals and physical examination. He appeared normal at the time of his two month follow-up visit.

This is the first report of intracranial imaging abnormalities in a neonate with COVID-19-associated encephalitis.^{1,4} COVID-19 infection in our patient may have been incidental, but contact with COVID-19-positive family members, absence of another etiology and antenatal risk factors, and clinical and imaging findings of neonatal encephalitis suggest COVID-19 as a cause. The high prevalence of COVID-19 in our population also indicates a lower likelihood of a false-positive COVID-19 PCR.

References

1. Lindan CE, Mankad K, Ram D, et al. Neuroimaging manifestations in children with SARS-CoV-2 infection: a multinational, multicentre collaborative study. *Lancet Child Adolesc Health.* 2020;5:167–177.
2. Madaan P, Singanamalla B, Saini L. Neurological manifestations of COVID-19 in children: time to be more vigilant. *Pediatr Neurol.* 2021;115:28.
3. McAbee GN, Brosgol Y, Pavlakis S, Agha R, Gaffoor M. Encephalitis associated with COVID-19 infection in an 11-year-old child. *Pediatr Neurol.* 2020;109:94.
4. Di Nicola P, Ceratto S, Dalmazzo C, Roasio L, Castagnola E, Sannia A. Concomitant SARS-CoV-2 infection and severe neurologic involvement in a late-preterm neonate. *Neurology.* 2020;95:834.
5. Verboon-Macielek MA, Groenendaal F, Cowan F, Govaert P, van Loon AM, de Vries LS. White matter damage in neonatal enterovirus meningoencephalitis. *Neurology.* 2006;66:1267–1269.

Paul J. Martin, MD

Radiology Resident, Department of Radiology, Indiana University School of Medicine, Indianapolis, Indiana

Marcia Felker, MD

Pediatric Neurologist, Department of Neurology, Riley Hospital for Children at Indiana University Health, Indianapolis, Indiana

Rupa Radhakrishnan, MBBS, MS

Pediatric Neuroradiologist, Department of Radiology, Riley Hospital for Children at Indiana University Health, Indianapolis, Indiana
E-mail address: rradhak@iu.edu.

Available online 9 March 2021

Conflict of interests: None.

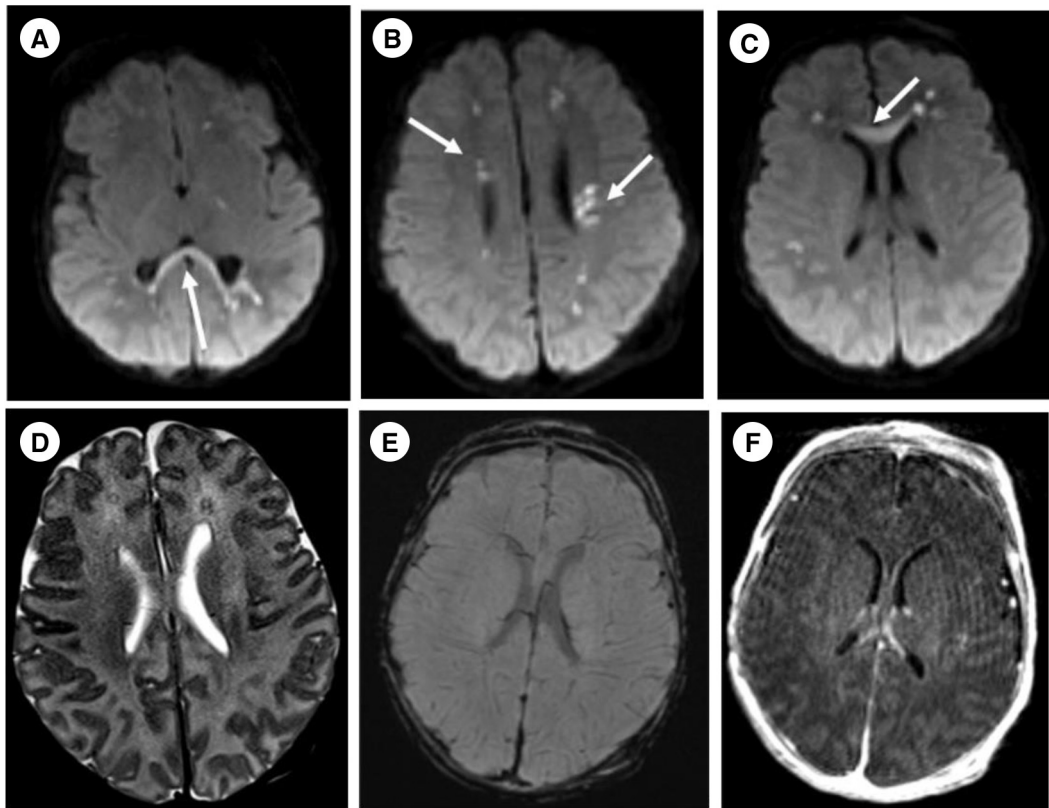


FIGURE. Axial diffusion-weighted images (A-C) at nine days of age showing multiple foci of restricted diffusion in the periventricular and deep white matter and corpus callosum (arrows). Axial T2 weighted image (D) shows corresponding signal abnormality in the deep white matter (arrows). There is no hemorrhage or enhancement associated with these white matter regions of signal abnormality as seen on susceptibility weighted (E) and postcontrast T1-weighted (F) images.