

A new microsurgical revascularization technique for anterior cerebral artery ischemia is reported. An arterial graft bypass interposed between the superficial temporal artery and the distal anterior cerebral artery was successfully completed in a 43-year-old male with transient ischemic attacks in the anterior cerebral artery territory. The contralateral superficial temporal artery was harvested and used as an arterial graft. Both procedures were carried out with one single transcoronal scalp incision. The patient's postoperative cerebral angiogram revealed good filling of the area distal to the stenotic lesion of the anterior cerebral artery through the bypass graft. The patient was discharged with no neurological deficit and has been free of ischemic events for more than 2 years since the surgery. If the bilateral superficial temporal arteries are fairly well developed, the ipsilateral superficial temporal artery can be used as an arterial graft for revascularization of the anterior cerebral artery territory.

MICROSURGERY 9:14-17 1988

AN INTERPOSED SUPERFICIAL TEMPORAL ARTERY GRAFT BYPASS FOR ANTERIOR CEREBRAL ARTERY ISCHEMIA

YOSHIKAZU IWATA, M.D., TADAHISA MIZUTA, M.D.,
OSAMU TAKEMOTO, M.D., KEIJI SHIMIZU, M.D.,
and SUSUMU NAKATANI, M.D.

Microsurgical cerebral revascularization procedures for anterior and posterior circulation have been commonly performed since Donaghy and Yasargil¹ reported their successful cases of superficial temporal artery (STA) to middle cerebral artery (MCA) anastomosis in 1968. However, there have been only a few reports of bypass operations for stenotic or occlusive lesions of the anterior cerebral artery (ACA). Revascularization of the deep-seated area of ACA is usually impossible without using a graft of some kind. An interposed cephalic vein bypass graft between the STA and a distal branch of the ACA was reported.² The ACAs of both sides were anastomosed side-to-side in situ distal to the stenotic lesion.^{3,4}

This paper describes a new approach to correction of ACA ischemia—an interposed arterial graft bypass using the contralateral STA.

CASE REPORT

A 43-year-old right-handed businessman was admitted to our hospital on March 8, 1985 because of a sudden

episode of left hemiparesis followed by dysphasia with a precordial squeezing sensation, which lasted for several minutes without loss of consciousness. In January and March, prior to admission, he had experienced two other episodes of transient weakness of the right lower extremity with focal twitching of the left leg, which cleared up in a few minutes. The patient's familial and personal medical histories were non-contributory.

Neurological examination was normal on admission. No bruit was audible in the neck or around the orbits. Blood pressure was 146/100 mm Hg, while the pulse rate was 60/min, with a regular rhythm. Chest X-rays, an electrocardiogram, and an echocardiogram were normal. The results of the complete laboratory examination were normal, except for mild hyperlipemia. A CT scan of the brain was normal. A four-vessel cerebral angiographic study demonstrated atherosclerotic stenosis of the proximal A-2 portion of the left ACA (Fig. 1).

This lesion was thought to be responsible for the ischemic episodes, since no other stenotic or occlusive lesion was found in any of the extracranial or intracranial cerebral arteries. The STAs were fairly well developed on both sides. A single-photon-emission CT scan revealed decreased cerebral blood flow in the bilateral frontal area, as well as mild general reduction of the blood flow in both hemispheres; the latter was probably due to the diaschisis. Considering the repeated episodes of transient ischemic attack, the findings of cerebral angiography and the patient's relatively young age, bypass surgery to the distal portion of the

From the Department of Neurosurgery, Minoh City Hospital (Y.I., T.M., O.T.) and Osaka University Medical School (K.S., S.N.), Osaka, Japan.

Address reprint requests to Yoshikazu Iwata, M.D., Department of Neurosurgery, Minoh City Hospital, 5-7-1 Kayano, Minoh, Osaka 562, Japan.

Received for publication January 27, 1988.

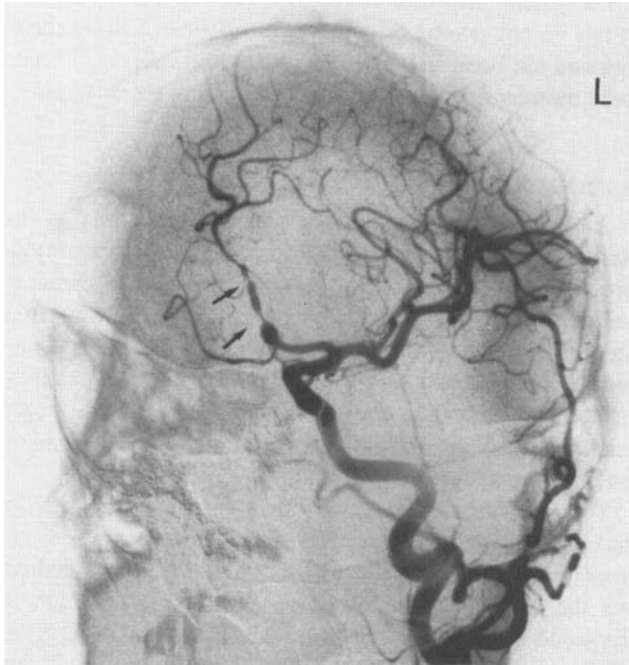

Figure 1. Oblique view of postoperative left (L) carotid angiogram, demonstrating stenosis in the A-2 portion of the left anterior cerebral artery (arrows).

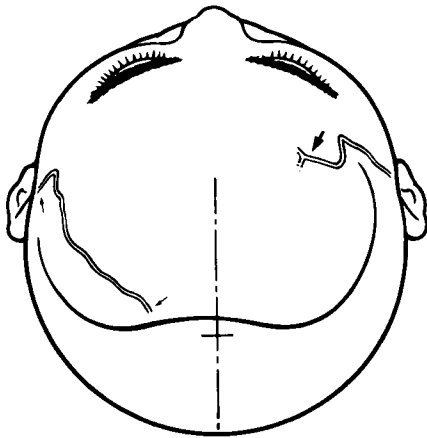


Figure 2. Tracing of the branches of the superficial temporal arteries on both sides in front of the transcoronal scalp incision line. The diagram shows that the dissection of the donor superficial temporal artery on the left, harvesting of the contralateral superficial temporal artery graft (between small arrows), and interposing of the anastomosis between the donor artery (large arrow), the arterial graft and the left internal frontal artery can be performed with a single scalp flap.

left ACA was thought to be justified, to prevent future ischemic events by restoring a normal blood flow to the area of poor perfusion.

Operative Procedure

On March 25, 1985, revascularization surgery was performed. Under satisfactory general anesthesia, a transco-

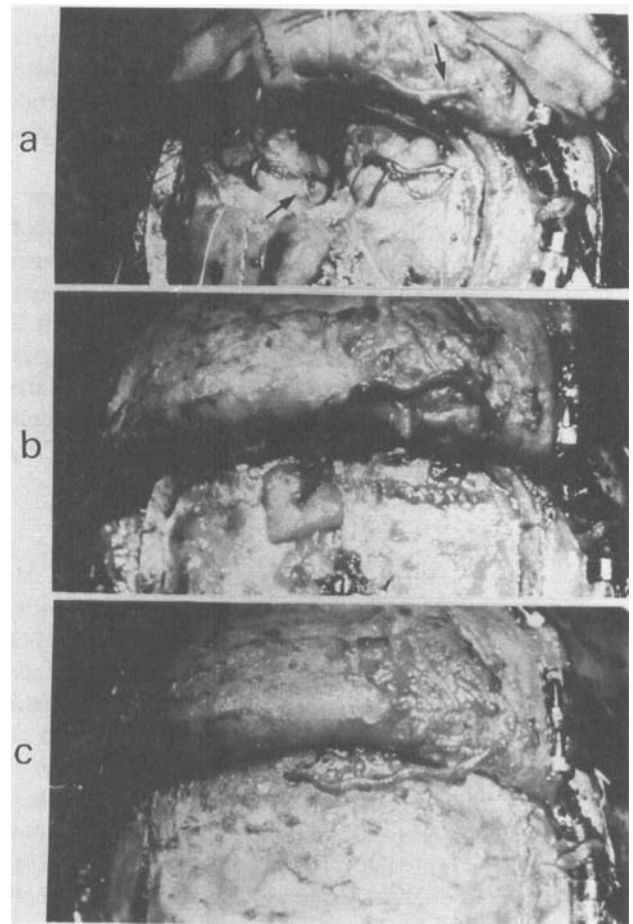


Figure 3. **a:** The arterial graft was anastomosed between the frontal branch of the right superficial temporal artery and the left internal frontal artery. Arrows show site of anastomosis. **b:** On closing the dura, a small gap for the graft to enter was left at its anterior margin. A small piece of gelatin sponge (Gelfoam) around the graft. **c:** The frontal bone flap was replaced and fixed. The graft was passed into the skull via the midfrontal burr hole.

ronal skin incision was made behind the hairline, and a bifrontal craniotomy was carried out (Fig. 2). The dura mater was opened along the anterior margin of the craniotomy. The superior sagittal sinus was ligated and divided at the anterior border in order to minimize brain retraction during the anastomotic procedure. The left internal frontal artery, the peripheral branch of the callosomarginal artery, was exposed along the frontal interhemispheric fissure with the aid of an operating microscope. The frontal branch of the left STA was then isolated, and an 8-cm length was excised from the undersurface of the frontal skin flap for use as an arterial graft. The lumen of the graft was irrigated with heparinized saline.

The anterior branch of the right STA was identified and prepared as the donor artery. After trimming of the vessel stumps, the graft was anastomosed end-to-end to the distal end of the frontal branch of the right STA with 12 inter-

rupted 10-0 nylon monofilament sutures. The lumen of the arterial graft in situ was again irrigated with heparinized saline solution. The distal end of the graft was then anastomosed end-to-side, in the usual manner, to the left internal frontal artery with 11 interrupted 11-0 monofilament nylon sutures.

After removing Scoville's microclips used for temporary occlusion of the vessels, pulsation of the graft and of the left internal frontal artery, as seen under the microscope, seemed satisfactory. Each anastomosis was completed in 35 minutes. The dura was closed, leaving a gap for the graft to enter. The bone flap was replaced, allowing the graft to pass through the burr hole of the skull in the midfrontal area (Fig. 3). The scalp was sutured in two layers. No systemic anticoagulant was administered either during or after the surgery.

Operative Result

The patient's postoperative course was uneventful. No marginal scalp ischemia was noted. Pulsation of the graft was palpable in the patient's right forehead. Right cerebral angiography performed on the 16th postoperative day also proved the patency of the graft (Fig. 4). The left internal frontal artery and the callosomarginal artery were filled via the bypass route. The stenotic lesion of the left ACA per se remained unchanged. Normal cerebral blood flow on both hemispheres, with no focal ischemic region, was confirmed by single-photon-emission CT scans performed on the 23rd day and 7 months after the surgery. Repeated electroencephalograms have been negative for paroxysmal discharges and focal abnormalities.

The patient was discharged in excellent condition without any complications or neurological deficits. He resumed work and has been well and free of cerebral ischemic events for 32 months since the surgery, without any medication.

DISCUSSION

An international randomized trial on extracranial to intracranial (EC-IC) bypass failed to confirm that this procedure has greater efficacy for prevention of stroke than has medical therapy.⁵ Although longer follow-up by repeated angiography and clinical observation is necessary to conclude that this bypass surgery has been effective in preventing cerebral ischemia, the patient described in this paper benefited from the bypass surgery and has been free of ischemic events for more than 2 years.

This is the first report, to our knowledge, of an STA graft bypass for the treatment of ischemic symptoms induced by a stenotic lesion of the ACA. The new method uses the contralateral STA as an arterial graft, which is interposed between the distal branch of the unilateral STA and the distal branch of the ACA. The advantage of the technique is that the graft harvesting and the anastomosis can be carried out with a single transcoronal scalp incision.

Microsurgical revascularization for ACA ischemia has been reported less frequently than for lesions of the MCA and the internal carotid artery. Since there is no suitable scalp artery long enough to reach the deep-seated ACA, revascularization of this artery can only be achieved either by a side-to-side anastomosis between the ACAs^{3,4} or by an interposed graft bypass.²

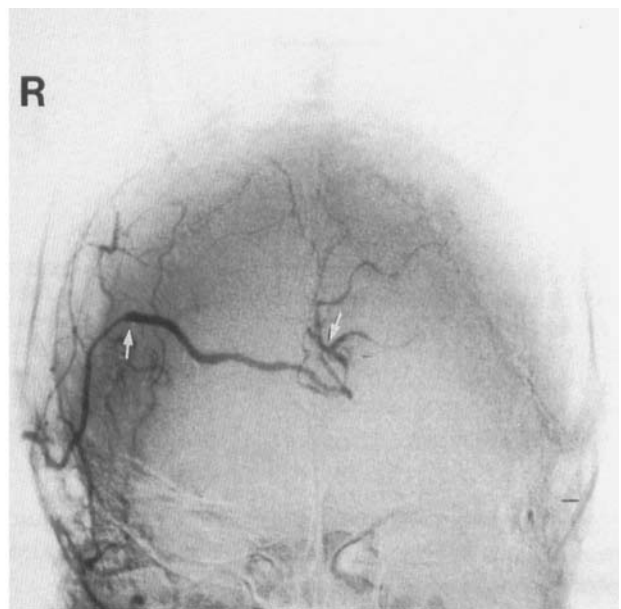
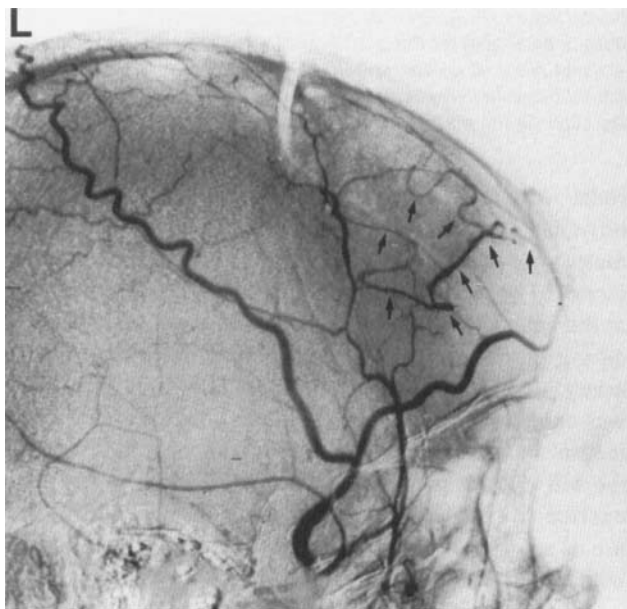


Figure 4. **Left:** Lateral and **Right:** anteroposterior view of postoperative right carotid angiogram, black arrows indicate filling of the left internal frontal artery and the callosomarginal artery on the left

side through the bypass graft. White arrows indicate the site of anastomosis of the graft.

For the interposing graft, synthetic tubes,⁶⁻⁸ veins,⁹⁻¹¹ and free radial artery segments^{12,13} have been used for cerebral revascularization in occlusive cerebrovascular diseases. All currently available microvascular synthetic tube grafts, except for very short ones,⁶ are unsuitable for small arteries involved in EC-IC bypass surgery.⁸ Several disadvantages of the vein bypass graft have been reported.^{10,11} Donor-recipient size discrepancy may pose a technical difficulty to anastomosis. Torsion, angulation, kinking, and easy compressibility of a thin-walled vein conduit may lead to graft thrombosis. Since it is necessary to keep a high flow through a large-sized vein graft between small arteries makes it unsuitable for a short interposed graft. Arteries are thought to be physiologically more suitable as graft vessels than veins.^{14,15} Maroon and Donaghy¹⁴ reported in their experimental study that the patency rate with arterial grafts was better than that with venous grafts. They attributed this to the greater ease of handling due to the thicker wall, the reduced tendency toward redundancy and kinking, and the better graft-to-recipient artery ratio.

Radial arteries have been used for ischemic lesions of the posterior circulation¹² and the anterior circulation.¹³ However, the morbidity associated with removal of the radial artery is not negligible. If the diameter of anterior branch of the STA is large enough to maintain patency, as in this case, the contralateral STA can be used as an arterial graft. It can be harvested easily from the same skin flap and is suitable as a graft for ACA revascularization. The ipsilateral STA can be used as the donor artery.

When the major blood supply to the scalp was disconnected, marginal skin necrosis would be a frequent occurrence in STA-MCA anastomosis.¹⁶ Arterial distributions in the frontal scalp, however, are rich through the supraorbital and zygomaticotemporal arteries, the skin necrosis associated with the transcoronal incision would be a less frequent occurrence in this procedure.¹⁷

CONCLUSION

A new revascularization technique for the ischemic events of ACA was performed. The contralateral STA was utilized as an arterial graft between the STA and the ACA. The advantage of this method is that graft harvesting and

the anastomosis can be carried out with a single transcoronal scalp incision.

REFERENCES

1. Donaghy RMP, Yasargil MG: Extra-Intracranial blood flow diversion. *Proceedings of the 36th American Association of Neurological Surgeons*. 1968, p. 104.
2. Itoh Z: A new technique of intracranial anastomosis between distal anterior cerebral arteries (ACA) for ACA occlusion and its indication. *Neurol Med Chir (Tokyo)* 21:931-939, 1981 (in Japanese).
3. Ishii R, Koike T, Takeuchi S, Ohsugi S, Tanaka R, Konno K: Anastomosis of the superficial temporal artery to the distal anterior cerebral artery with interposed cephalic vein graft: Case report. *J Neurosurg* 58:425-429, 1983.
4. Ikeda A, Okada T, Shibuya M, Noda S, Sugiura M, Iguchi I, Gonda T, Kageyama N: Revascularization of the anterior cerebral artery: A report of two cases. *J Neurosurg* 62:603-606, 1985.
5. The EC/IC Bypass Study Group: Failure of extracranial/intracranial arterial bypass to reduce the risk of ischemic stroke: Results of an international randomized trial. *N Engl J Med* 313:1191-1200, 1985.
6. Derman GH, Reichman OH: Polytetrafluoroethylene for microarterial prosthetic grafts. *Arch Surg* 116:211-216, 1981.
7. Story JL, Brown WE Jr, Eidelsberg E, Arom KV, Stewart JR: Cerebral revascularization: Proximal external carotid to distal middle cerebral artery bypass with a synthetic tube graft. *Neurosurg* 3:61-65, 1978.
8. Weinstein PR, Reinert RL, Brittain F: Delayed thrombosis of synthetic microvascular bypass grafts. *Neurosurg* 9:268-274, 1981.
9. Samson DS, Hodosh RM, Clark K: Microsurgical treatment of transient cerebral ischemia: Preliminary result in 50 patients. *JAMA* 241:376-378, 1979.
10. Spetzler RI, Rhodes RS, Roski RA, Likavec MJ: Subclavian to middle cerebral artery saphenous vein bypass graft. *J Neurosurg* 53:465-469, 1980.
11. Sundt TM Jr, Piepgras DG, Houser OW, Marsh R, Fode C: Saphenous vein bypass grafts for giant aneurysms and intracranial occlusive disease. *J Neurosurg* 65:439-450, 1986.
12. Ausman JI, Nicoloff DM, Chou S: Posterior fossa revascularization: Anastomosis of vertebral artery to PICA with interposed radial artery graft. *Surg Neurol* 9:281-286, 1978.
13. Yasui N, Ohta H, Suzuki A, Kamiyama H: Cervical carotid artery to middle cerebral artery anastomosis with interposed radial artery graft, in Spetzler RF, Carter LP, Selman WR, Martin NA (eds): *Cerebral Revascularization for Stroke*. New York, Thieme Stratton, 1985, pp. 379-385.
14. Maroon JC, Donaghy RMP: Experimental cerebral revascularization with autogenous grafts. *J Neurosurg* 38:172-179, 1973.
15. Whang CJ, Mozingo JR, Rhoton AL Jr: Comparison of blood flow and patency in arterial and vein grafts to basilar artery. *Stroke* 6:445-448, 1975.
16. Reichman OH: Complications of cerebral revascularization. *Clin Neurosurg* 23:318-335, 1976.
17. Elisevich KV, Colohan ART, Brem S, Comair Y: A rapid and modifiable technique for regional exposure in cerebral surgery: A technical note. *J Neurosurg* 67:140-142, 1987.