

## Integrating visual search, eye movement training and reversing prism exposure in the treatment of Balint-Holmes syndrome: a single case report

Francesco Panico, Angela Arini, Pierluigi Cantone, Claudio Crisci & Luigi Trojano

To cite this article: Francesco Panico, Angela Arini, Pierluigi Cantone, Claudio Crisci & Luigi Trojano (2021): Integrating visual search, eye movement training and reversing prism exposure in the treatment of Balint-Holmes syndrome: a single case report, Topics in Stroke Rehabilitation, DOI: [10.1080/10749357.2021.1923319](https://doi.org/10.1080/10749357.2021.1923319)

To link to this article: <https://doi.org/10.1080/10749357.2021.1923319>



Published online: 07 May 2021.



Submit your article to this journal [↗](#)



Article views: 22



View related articles [↗](#)



View Crossmark data [↗](#)



# Integrating visual search, eye movement training and reversing prism exposure in the treatment of Balint-Holmes syndrome: a single case report

Francesco Panico <sup>a</sup>, Angela Arini<sup>b</sup>, Pierluigi Cantone<sup>b</sup>, Claudio Crisci<sup>b</sup>, and Luigi Trojano <sup>a</sup>

<sup>a</sup>Department of Psychology, University of Campania “Luigi Vanvitelli”, Caserta, Italy; <sup>b</sup>Neurorehabilitation Unit, Clinic Center Rehabilitation Institute, Napoli, Italy

## ABSTRACT

**Objective:** For the first time, we administered reversing prism exposure to treat optic ataxia in a single patient with Balint-Holmes Syndrome (BHS), who also underwent specific trainings for simultanagnosia and ocular apraxia.

**Method and Results:** By an introduction and withdrawal experimental design, we observed that the active treatment periods improved patient’s visuospatial defects and functional autonomy.

**Conclusions:** We thus provided a proof of principle supporting the use of reversing prism exposure in optic ataxia within an integrated and personalized rehabilitative approach for BHS.

## ARTICLE HISTORY

Received 14 April 2021

Accepted 24 April 2021

## KEYWORDS

Balint-Holmes syndrome; rehabilitation; optic ataxia; prism exposure; visuo-spatial disorders

## Introduction

Balint-Holmes Syndrome (BHS) is characterized by simultanagnosia, ocular apraxia, and optic ataxia.<sup>1</sup> Simultanagnosia has been described in a “dorsal” form, precluding the detection of multiple objects, and in a “ventral” form, causing difficulties in simultaneously recognizing the individual parts of an object.<sup>2</sup> Ocular apraxia is an impairment of visual fixation related to defective saccade initiation and limited visual pursuit.<sup>3</sup> Optic ataxia corresponds to the difficulty in performing arm movements directed at visual objects, in the absence of primary visual, proprioceptive or motor disorders.<sup>4</sup>

Usually BHS follows bilateral stroke in the parieto-occipital cortex,<sup>2,5</sup> is highly disabling and shows poor spontaneous recovery.<sup>6</sup> Previous rehabilitative interventions aimed at exploiting residual cognitive abilities by compensatory strategies, or at recovering the impaired functions by intensive training, but no large-scale clinical trials are available [for a review<sup>7</sup>] Optic ataxia has been treated by encouraging the patient fixating an object before grasping,<sup>6</sup> and very recently, by a one-day session of intensive repetitive pointing.<sup>8</sup> Nonetheless, the treatment of optic ataxia remains quite overlooked.

Here, we applied, for the first time, a prism exposure training for optic ataxia in a patient with BHS,

aimed at increasing patient’s awareness on discrepancy between the aimed movement and the actual motor output, to prompt strategic motor correction. The individualized rehabilitation plan also included visual search tasks for treating dorsal simultanagnosia and eye movement training for gaze apraxia, as described in the literature.<sup>7</sup>

## Case report

DG, a 55-year-old male teacher, developed wide cortico-subcortical ischemic lesions in the right temporo-parieto-occipital and left parieto-occipital regions following SARS-CoV2 infection.<sup>9</sup>

One month after admission to the rehabilitation unit, the patient was alert and cooperative, well oriented and aware of his condition. Bedside examination revealed severe simultanagnosia, ocular apraxia, and optic ataxia, consistent with a full-blown BHS, and mild left neglect. A formal neuropsychological evaluation based mainly on verbal task revealed word finding difficulties and mild executive dysfunction (Table 1).

The neuropsychological treatment started three months after stroke and was in line with the CARE Guidelines.<sup>17</sup> In an ABAB introduction and withdrawal experimental design,<sup>18</sup> we performed two rehabilitation cycles, each including three sessions

**Table 1.** Neuropsychological examination.

Test	Baseline (T0)	After Treatment (T6)
Montreal Cognitive Assessment (10, 11)	11/30*	18/30*
Digit Span – forward (12)	2*	3*
Verbal Span – words (13)	3*	3*
Constructional Apraxia (13)	1/14*	4/14*
Rey Auditory Verbal Learning Test – immediate (14)	13/75*	43/75
Rey Auditory Verbal Learning Test – delayed (14)	2/15*	8/15
Babcock Memory Test (13)	11,3/16	13,6/16
Word Fluency: phonemes (14)	14*	12*
Word Fluency: categories (13)	7,25*	15,25
Frontal Assessment Battery (15, 16)	7/18*	12/18*

\* = pathological performance according to age- and education-adjusted Italian normative studies

in a week. DG provided his written consent to take part in the rehabilitation plan; procedures were in line with the 1978 Helsinki Declaration.

In each session, the three trainings were given in random order. In the visual search training,<sup>19</sup> the patients had to look for the grayscale pictures of objects named by the examiner within centrally presented  $4 \times 4$ ,  $6 \times 6$  or  $9 \times 9$  matrices (size:  $21 \times 29,7$  cm; distance from the patient: 50 cm). During eye movement training,<sup>20</sup> the patient had to place his index fingers at a distance of 15 cm from his face and to move his gaze to one or the other alternately during a 5-min period. Distance between the two index fingers was increased from 5 to 15 and 30 cm (15 trials per distance; total trials per session: 45). The reversing prism exposure training<sup>21</sup> involved pointing movements while the patient wore prism glasses whose base changed every few trials. This procedure makes the participant unable to develop full adaptation but stimulates error correction and error compensation mechanisms.<sup>21</sup> In our training, the patient was asked to point with his right hand toward a centrally placed target (a 1-cm dot) while wearing glasses shifting the visual field by  $10^\circ$ . The direction of the prism shift was reversed (left to right and vice versa) every 5 trials and the same sequence was

repeated three times (total trials: 30). The patient was encouraged first to search for the target, then to develop a movement plan, and finally to execute a fast, one-shot movement toward the target. Verbal feedback and instructions were provided during the planning phase for identifying object position<sup>6</sup> and coding knowledge about object position and limb position; in case of error, verbal feedback aimed at noticing the misplacement of movement outcome and at correcting it were given.

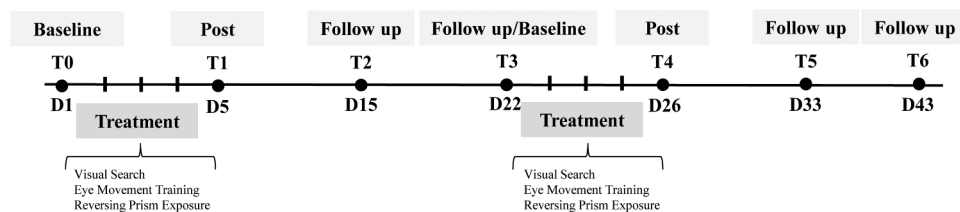
Before and after each cycle, we evaluated simultanagnosia, gaze apraxia, and optic ataxia (T0-T6; Figure 1). At the end of the rehabilitation period, the patient underwent a general neuropsychological assessment (Table 1).

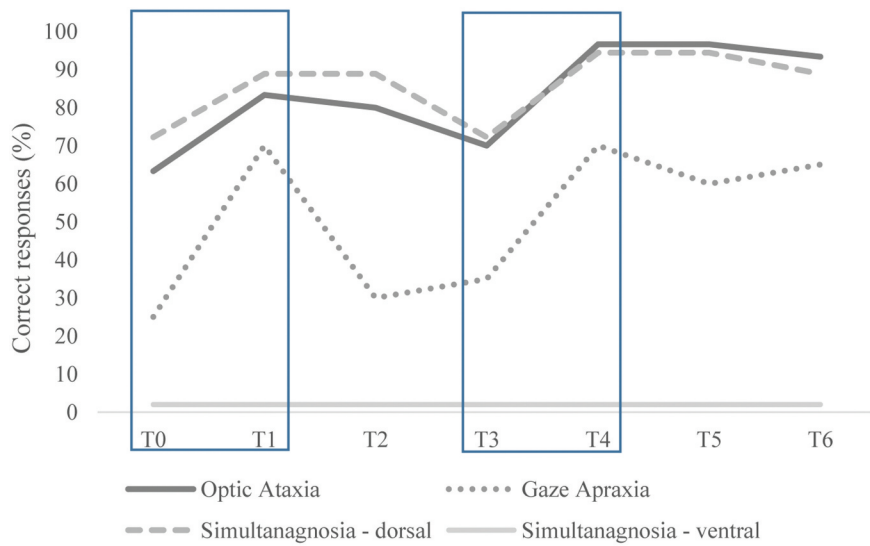
To assess ventral simultanagnosia, we asked the patient what he could see when looking at 10 large silhouettes made up of small parts (e.g. a large letter ‘G’ formed by small letters ‘E’). To assess dorsal simultanagnosia, the patient was asked to name single objects in the right ( $n = 6$ ) or left ( $n = 6$ ) visual field, or two centrally located objects ( $n = 6$ ).

To assess gaze apraxia, the patient was required to look at statically presented objects in four possible locations (left, right, upper, or lower visual field;  $n = 5$  each), without making concurrent head movements. The examiner visually checked whether each patient’s eye movement was quick and direct or slow, hesitant and inaccurate.

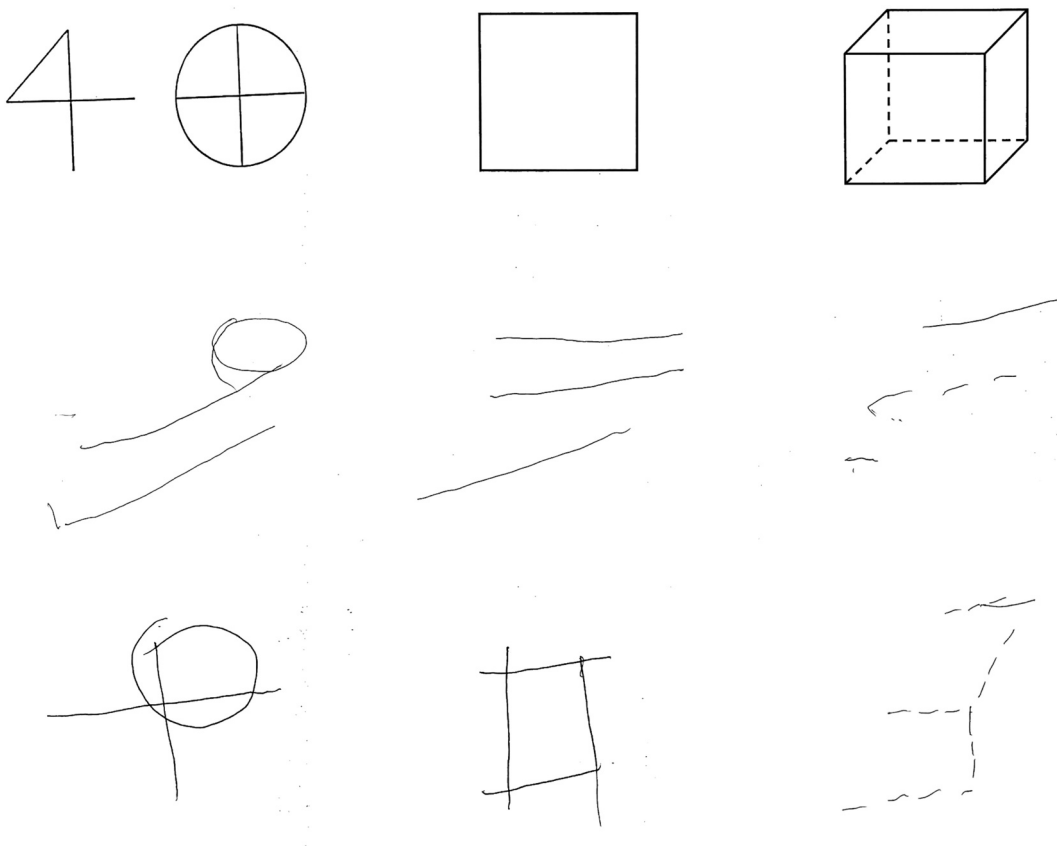
To assess optic ataxia, the patient was required to reach for a visually displayed object (a yellow cup) in the left, right or central visual field with his left or right hand. Five trials for each hand and field combination were given for a total of 20 trials. A response was considered correct when the patient could touch the target at his first direct attempt, or immediately self-corrected his mistake.

Before and after the rehabilitation program (T0, T6), we also assessed DG’s functional autonomy in 10 specific daily life activities (eating, grooming,

**Figure 1.** Timeline of neuropsychological rehabilitation plan (D means days, T assessments).



**Figure 2.** Percentage of correct responses at the tasks assessing optic ataxia, gaze apraxia and ventral and dorsal simultanagnosia at the different stages of the rehabilitation period. The evaluations after the active rehabilitation period correspond to T1 and T4 (see Figure 1 for the whole timeline).



**Figure 3.** Examples of patient's performance in copying geometrical figures (top row) at baseline assessment (T0, middle row) and at the end of the rehabilitation period (T6, bottom row).

**Table 2.** Measures of functional outcome.

Daily life activities	Baseline (T0)	After Treatment (T6)
Eating	1	4
Grooming	1	3
Bathing	1	2
Upper dressing	1	4
Lower dressing	1	3
Toileting	1	2
Wheelchair driving	1	2
Stairs	1	1
Comprehension	5	5
Expression	3	3
Total score	16	31

1 = complete assistance, 2 = moderate assistance, 3 = minimal assistance, 4 = moderate independence, 5 = complete independence.

bathing, upper and lower dressing, toileting, wheelchair driving, going up and down stairs, comprehension, and expression) on a 5-point scale (from 1 = complete assistance to 5 = complete independence).

Visual inspection of the curves<sup>18</sup> depicting patient's performance during the rehabilitation period (Figure 2) suggests that at the end of the first treatment period (T1), optic ataxia, gaze apraxia, and dorsal simultanagnosia improved, whereas ventral simultanagnosia did not. When treatment was withdrawn, performance returned to baseline levels (T2-T3). Crucially, at the end of a new cycle of treatment (T4), optic ataxia, gaze apraxia, and dorsal simultanagnosia improved further and then remained stable or decreased a little, without returning to the baseline level after treatment withdrawal (T5-T6). Such improvements enhanced copying abilities (Figure 3), and autonomy in daily life activities (Table 2).

## Discussion

Here, we described a rehabilitative approach for BHS, in which we applied for the first time reversing prism exposure,<sup>21</sup> along with visual search and eye movement trainings already described in the literature. After each treatment session patient's performance improved, while it remained unchanged or worsened when no specific treatment was delivered. The visual search treatment ameliorated patient's ability to allocate attention toward visual objects (dorsal simultanagnosia), but not to identify multipart objects (ventral simultanagnosia), and the eye movement training produced more accurate and larger saccades and visual pursuit, in line with previous studies addressing

rehabilitation of BHS.<sup>7,19,20</sup> The novel finding here is that the implementation of prism exposure<sup>21</sup> contributed to improve patient's ability to plan and execute reaching movements, thus reducing optic ataxia. The reversing prism exposure training promoted more accurate voluntary object reaching movements, likely by exploiting residual recalibration abilities. In the prism adaptation literature, recalibration is conceptualized as a fast, explicit, strategic mechanism of error correction and compensation, depending on a brain network including cerebello-parieto-motor areas.<sup>22,23</sup> The present results would suggest that exposure to prism shift in a condition where the visual shift is frequently changed (before full adaptation occurs) could train residual recalibration abilities and induce more accurate movements. During the training session, DG received frequent verbal feedback and instructions for planning movements, and, in case of error, for noticing distance between the aimed object and the actual movement outcomes, and for correcting them. These verbal feedback followed the compensative approaches already applied for rehabilitation of BHS,<sup>7</sup> and paralleled the rehabilitative approaches for visuo-constructional impairments.<sup>24</sup> Our results might also be in line with the finding that intense movement repetition is able to improve reaching abilities.<sup>8</sup> However, future studies are needed to compare improvements in optic ataxia following mere repetition of pointing movements versus pointing movements during reversing prism exposure.

The improvements in allocating attention toward objects, in directing gaze, and in performing movements toward objects, improved patient's performance on copying tasks, and in everyday activities, such as eating, grooming and dressing, which

depend on accurate control of upper limb movements. DG himself, his relatives, and health-care personnel appreciated the higher level of independence achieved.

The above-described findings have to be interpreted with caution due to the limitations related to the single case design adopted here. Indeed, we could not control possible confounding variables, such as test–retest effects. Moreover, we could not assess the long-term effects of the training after discharge. It is also to be acknowledged that spontaneous recovery could be relevant during the first months after a brain lesion. However, as improvements in patient’s performance closely followed treatment periods (and were null during treatment withdrawal), and ventral simultanagnosia did not ameliorate during the rehabilitation period, we would suggest that spontaneous recovery was not a likely explanation of our results. It remains to be assessed whether a more comprehensive rehabilitation plan, including training for the ability of integrating multipart objects, could contribute to ameliorate the entire spectrum of BHS.



### Author contributions

FP and AA collected the data and wrote the first draft; LT, CC and PC revised original manuscript. All authors read and approved the final manuscript.

### Funding

FP received funding from the program V:ALERE2019 Università della Campania “Luigi Vanvitelli”, D.R. 907/2019, prot. n. 148008, 4/10/2019.

### ORCID

Francesco Panico  <http://orcid.org/0000-0001-8346-5484>  
Luigi Trojano  <http://orcid.org/0000-0002-0328-9642>

### References

1. Hecaen H, De Ajuriaguerra J 1954. Balint’s syndrome (psychic paralysis of visual fixation) and its minor forms. <http://brain.oxfordjournals.org/>
2. Rizzo M, Vecera SP. Psychoanatomical substrates of Bálint’s syndrome. *J Neurol Neurosurg Psychiatry*. 2002;72(2):162–178. doi:10.1136/jnnp.72.2.162.
3. Pierrot-Deseilligny C. Saccade and smooth-pursuit impairment after cerebral hemispheric lesions. *Eur Neurol*. 1994;34(3):121–134. doi:10.1159/000117025.
4. Pisella L, Rossetti Y, Rode G. Optic ataxia in Bálint-Holmes syndrome. *Ann Phys Rehabil Med*. 2017;60(3):148–154. doi:10.1016/j.rehab.2016.01.003.
5. Parvathaneni A, Das JM. 2020. Balint syndrome. *StatPearls*. <http://www.ncbi.nlm.nih.gov/pubmed/31335067>
6. Kerkhoff G, Heldmann B. Balint-syndrom und assoziierte storungen. Anamnese - diagnostik - behandlungsansatze. *Nervenarzt*. 1999;70(10):859–869. *Nervenarzt*. doi:10.1007/s001150050589.
7. Heutink J, Indorf DL, Cordes C. The neuropsychological rehabilitation of visual agnosia and Balint’s syndrome. *Neuropsychol Rehabil*. 2019;29(10):1489–1508. Routledge. doi:10.1080/09602011.2017.1422272.
8. Baumard J, Etcharry-Bouyx F, Chauviré V, et al. Effect of object substitution, spontaneous compensation and repetitive training on reaching movements in a patient with optic ataxia. *Neuropsychol Rehabil*. 2020;30(9):1786–1813. doi:10.1080/09602011.2019.1607397.
9. Panico F, Arini A, Cantone P, Crisci C, Trojano L. 2020. Balint-Holmes syndrome due to stroke following SARS-CoV-2 infection: a single case report. <https://doi.org/10.21203/rs.3.rs-95298/v1>
10. Nasreddine ZS, Phillips NA, Bédirian V, et al. The Montreal cognitive assessment, MoCA: a brief screening tool for mild cognitive impairment. *J Am Geriatr Soc*. 2005;53(4):695–699. doi:10.1111/j.1532-5415.2005.53221.x.
11. Santangelo G, Siciliano M, Pedone R, et al. Normative data for the montreal cognitive assessment in an Italian population sample. *Neurol Sci*. 2015;36(4):585–591. doi:10.1007/s10072-014-1995-y.
12. Orsini A, Grossi D, Capitani E, Laiacona M, Papagno C, Vallar G. Verbal and spatial immediate memory span: normative data from 1355 adults and 1112 children. *Ital J Neurol Sci*. 1987;8(6):537–548. doi:10.1007/BF02333660.
13. Spinnler H, Tognoni G. Standardizzazione e taratura italiana di test neuropsicologici. Gruppo Italiano per lo Studio Neuropsicologico dell’Invecchiamento. *Ital J Neurol Sci*. 1987;8:111–119. doi:10.1007/BF02337583.
14. Carlesimo GA, Caltagirone C, Gainotti G, et al. The mental deterioration battery: normative data, diagnostic reliability and qualitative analyses of cognitive impairment. *Eur Neurol*. 1996;36(6):378–384. doi:10.1159/000117297.
15. Appollonio I, Leone M, Isella V, et al. The frontal assessment battery (FAB): normative values in an Italian population sample. *Neurol Sci*. 2005;26(2):108–116. doi:10.1007/s10072-005-0443-4.
16. Dubois B, Slachevsky A, Litvan I, Pillon B. The FAB: a frontal assessment battery at bedside. *Neurology*. 2000;55(11):1621–1626. doi:10.1212/WNL.55.11.1621.

17. Gagnier JJ, Kienle G, Altman DG, et al. The CARE guidelines: consensus-based clinical case reporting guideline development. *J Med Case Rep.* 2013;7(1):223. doi:10.1186/1752-1947-7-223.
18. Smith JD. Single-case experimental designs: a systematic review of published research and current standards. *Psychol Methods.* 2012;17(4):510–550. doi:10.1037/a0029312.
19. Zgaljardic DJ, Yancy S, Levinson J, Morales G, Masel BE. Balint's syndrome and post-acute brain injury rehabilitation: a case report. *Brain Inj.* 2011;25(9):909–917. doi:10.3109/02699052.2011.585506.
20. Rosselli M, Ardila A, Beltran C. Rehabilitation of Balint's syndrome: a single case report. *Appl Neuropsychol.* 2001;8(4):242–247. doi:10.1207/S15324826AN0804\_7.
21. Prablanc C, Panico F, Fleury L, et al. Adapting terminology: clarifying prism adaptation vocabulary, concepts, and methods. *Neurosci Res.* 2020;153:8–21. doi:10.1016/j.neures.2019.03.003.
22. Panico F, Fleury L, Trojano L, Rossetti Y. Prism adaptation in M1. *J Cogn Neurosci.* 2020;33(4):563–573. doi:10.1162/jocn\_a\_01668.
23. Panico F, Rossetti Y, Trojano L. On the mechanisms underlying Prism Adaptation: a review of neuro-imaging and neuro-stimulation studies. *Cortex.* 2020;123:57–71. doi:10.1016/j.cortex.2019.10.003.
24. Grossi D, Trojano L. Riabilitazione dei disturbi visuo-spaziali. In: Mazzucchi A, ed. *La riabilitazione neuropsicologica.* 4th ed. Edra; Milan 2020:1936–2006.