

## Bilateral Opercular Syndrome and Crossed Aphemia Due to a Right Insular Lesion: A Clinicopathological Study

SERGIO E. STARKSTEIN, MARCELO BERTHIER, AND RAMON LEIGUARDA

*Instituto de Investigaciones Neurológicas Dr. Raul Carrea,  
Ayacucho 2166, 1112 Buenos Aires*

A right-handed male patient suddenly noted lower bilateral facial and lingual palsy, and inability to masticate and swallow, but with preserved automatic functions. He was mute, communicating only through writing, but verbal comprehension was normal (aphemia). On anatomopathological examination, an ischemic infarction of the entire right insula, with mild extension to the fronto-temporoparietal operculum was observed. The left hemisphere was normal. The clinical findings suggest a bilateral opercular syndrome due to a right hemisphere lesion and a crossed aphemia. © 1988 Academic Press, Inc.

The opercular syndrome was first described by Foix, Chavany and Marie (1926), and recognized as an independent entity among the pseudobulbar palsies by Alajouanine and Thurel (1933). The syndrome is clinically characterized by loss of voluntary functions of the muscles of the face, tongue, mastication, and swallowing with preservation of reflex and automatic functions (Bruyn & Gathier, 1969).

Aphemia is considered a severe dysarthria without aphasia, featuring muteness and/or hypophonic spoken output at onset, but with normal comprehension and writing. The syndrome usually indicates lesion involving the pars opercularis, inferior prerolandic gyrus, and the subjacent white matter (Schiff, Alexander, Naeser, & Galaburda, 1983).

We report a right-handed patient who developed a bilateral opercular syndrome and aphemia due to a right insular ischemic infarction.

### CLINICAL CASE

A 55-year-old right-handed male, with a history of rheumatic valve disease, valvular surgery at 50, and on oral anticoagulants since then,

We are indebted to Drs. D. Frank Benson and Lynn Speedie for their advice and critical reading of the manuscript. Address correspondence and reprint requests to Sergio E. Starkstein, M.D., Department of Psychiatry and Behavioral Sciences, Meyer 4-119, Johns Hopkins Hospital, Baltimore, MD 21205.

presented with mutism, inability to swallow, and weakness on his left side on 12/7/84. There was no previous history of neurological events.

On examination he was alert, oriented in space and person, but not in time, with severe bilateral weakness of the lower facial muscles; his mouth remained open and he dribbled. The tongue remained immobile inside his mouth, voluntary deglutition and mastication were impossible demanding feeding through a nasogastric tube. There was a bilateral palate palsy with an abolished palatal and brisk jaw reflex. He could neither utter a sound nor articulate simple words. Neither on command nor to imitation could he produce suction movements, throw a kiss, blow out a match, or imitate the gallop of a horse. No upper facial disturbances, ophthalmoplegia, or visual hemifield defects were observed, his upper facial motility being bilaterally intact. It was also observed that the patient could swallow automatically, cough, and yawn, disclosing then a severe left lower facial palsy. A left multimodal neglect and hemiparesis were also demonstrated.

On the Edinburgh Inventory (Oldfield, 1971), the patient scored +100 (right-handed). On multiple interviews with the patient's sister, wife, and two daughters, no history of familial left-handedness was disclosed. The patient has always been right-handed and there was no history of neurological illness during his childhood. The patient was mute and could only communicate by writing. Comprehension was almost normal. On a short version of the Token test (De Renzi & Vignolo, 1962) the patient score 26 out of 29, and errors were related to his left hemispatial neglect. After reading an article in the newspaper, the patient could adequately summarize, by writing, its main points. Denomination by writing was also error-free, as he could accurately denominate 10 out of 10 objects (5 high frequency and 5 low frequency) shown to him. He could also write fluently, and in fact, he did that compulsively, answering each question with long sentences. He did not show any feature of aphasic agraphia. On spontaneous writing, phrases were semantically and syntactically correct, and there were no paraphasias. The patient, however, showed a severe spatial dysgraphia (he wrote with an upward slant and extra strokes, leaving a wide left margin). Writing to copy or to dictation disclosed similar findings. The patient also showed a moderate ideomotor apraxia for the right hand, with temporospatial errors and using body parts as objects. On imitation or when performing with the actual object, he showed a mild improvement.

A CT scan was performed showing an ischemic infarction involving the right insula and extreme capsulae but sparing the lentiform nucleus (Fig. 1). An EEG only showed a right frontotemporal slowing.

On 12/14/84 the patient began to utter some guttural sounds. Direct laryngoscopy was performed, showing normal motility of the vocal folds. No pharyngeal saliva accumulation was observed. By 12/28/84 there

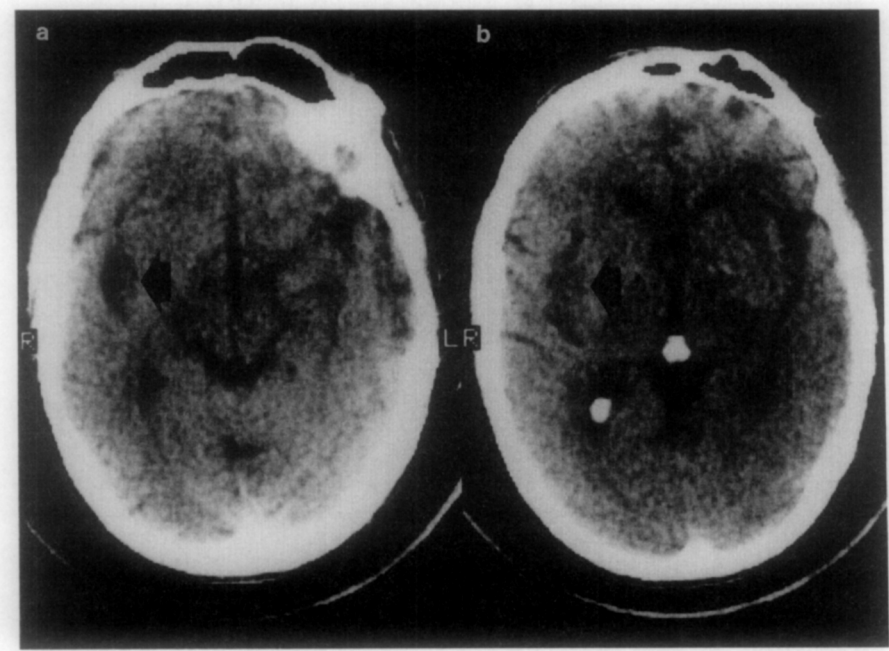


FIG. 1. (a) and (b) Computer tomographic (CT) scan showing an ischemic infarction involving the right insula.

was a complete recovery of palate motility. On that same day the patient uttered some vowels in a strenuous and dysprosodic way. On 12/30/84 he uttered isolated words and 3 days later recovered some lingual motility, opened his mouth properly on command, but remained unable to perform more complex movements (like throwing a kiss, imitating the gallop of a horse, or blowing out a match) to either command or imitation. On 1/3/85 he suffered a cardiac arrest, responding to resuscitation, but remained in deep coma. A repeat CT scan showed a new low-density lesion in the right corona radiata. He died some hours later after a second cardiac arrest.

#### ANATOMOPATHOLOGICAL EXAMINATION

Neck vessels exhibited marked arteriosclerosis. A basilar artery atheroma was also observed. The external surface of both hemispheres was quite normal. No hemisphere malformations were observed. The horizontal portion of the right Sylvian fissure was shorter and situated higher than the left one, and formed an obtuse angle rostrally. Both hemispheres were sectioned together in 8-mm-thick coronal slices. No cerebral damage

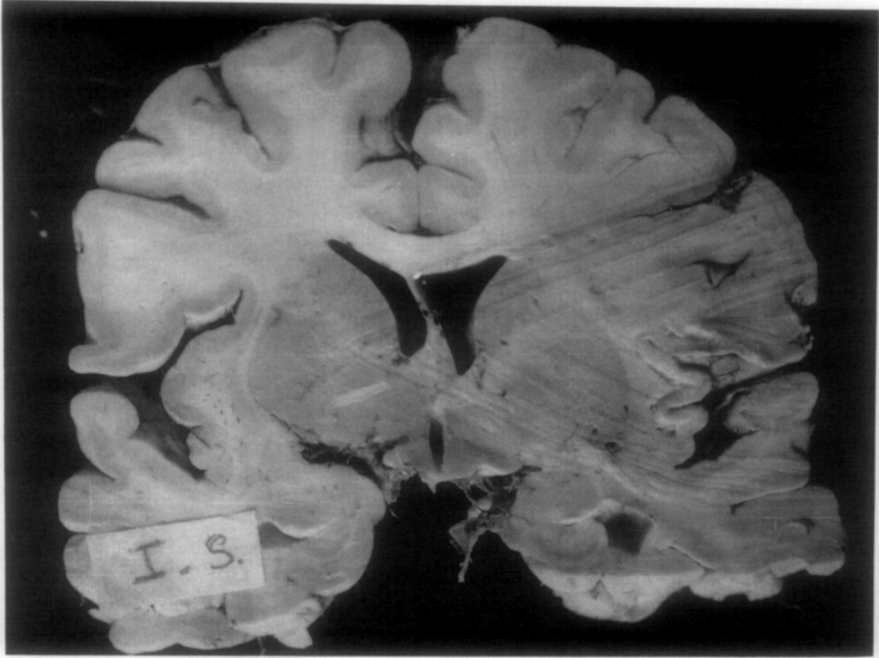


FIG. 2. Coronal section of brain showing an ischemic infarction involving the entire right insula and the inner cortical surface on the right frontotemporalparietal operculum. No lesion is observed in the left insulo-opercular region.

was observed in the anterior part of the frontal lobes. An ischemic infarction was observed involving the whole right insula and the inner cortical surface on the right frontotemporalparietal operculum (Fig. 2). Infarcts less than 1 cm in diameter were also observed in the right corona radiata. On myelin staining (Weigert technique), demyelination was observed in the right corona radiata. No lesion was observed in the left hemisphere. After paraffin embedding, microscopic examination was carried out to determine the chronological correlation of the different lesions. On hematoxylin–eosin staining technique the right insula was completely destroyed as were the extreme capsulae and the inner cortical surface of the frontotemporalparietal operculum. The necrotic areas were infiltrated by lipid- and hemosiderin-laden macrophages. Ferruginated neurons were present along the margin of the infarct. The right corona radiata showed diffuse demyelination with some small infarcts. No foam of macrophage cells were observed. Careful examination of the left hemisphere failed to show any evidence of infarction nor did the cerebellum or the brainstem. To summarize, we observed a 1-month-old right operculoinsular infarction

that caused the opercular syndrome. The diffuse demyelination of the right corona radiata was probably due to anoxia-ischemia suffered during terminal cardiac arrests. Small recent infarcts had presumably developed when the patient suffered the first arrest as suggested by the last CT scan.

### DISCUSSION

The cortico-subcortical type of the pseudobulbar palsy is clinically manifested by the opercular syndrome (Bruyn & Gathier, 1969). Neuropathological findings consist in bilateral or unilateral cortico-subcortical lesions involving the rolandic operculum, inferior portion of the Fa, base of F3, and insula (Foix & Chavany, 1926; Chateau, Fau, Gros Lambert, Perret, Boucharlat, & Chatelain, 1966). Symptoms appear for both bilateral and unilateral lesions (Schott, Boulliart, Cotte & Vauterin, 1961; Pertuiset & Perrier, 1960). In the former, symptoms are always bilateral, while in the latter, symptoms can be bilateral or contralateral in left-sided lesions, but only contralateral for right-sided ones. A transient and distal pyramidal-type paresis of the arm on the same side as the cranial nerve involvement invariably accompanies the syndrome. Hemianesthesia may be present for all modalities due to involvement of the parietal operculum and posterior central convolution. A pseudoperipheral facial nerve palsy can also be seen, together with ptosis and conjugate deviation of the head and eyes toward the site of the most recent lesion following a stroke (Bruyn & Gathier, 1969). In the unilateral type, two distinct syndromes may be seen. The anterior features motor deficits with aphasia (or anarthria) conspicuous. The posterior type, due to involvement of the parietal operculum, exhibits impaired sensation. Hemihypoesthesia, hemianesthesia, or a pseudothalamic dysesthesia may be present, sometimes combining paresthesias and a sensory deficit with a cheiro-oral distribution (Bruyn & Gauthier, 1969).

A salient aspect of the opercular syndrome is automatic-voluntary dissociation, so that the patient cannot voluntarily smile or cry, not even swallow food, but succeeds in an automatic mode (Alajouanine & Thurel, 1933). There is usually a palate palsy, with palate reflex abolishment, but some patients present normal vocal fold motility (Ferrari, Bonisegna, & Beltramello, 1979), while others have a uni- or bilateral vocal fold palsy (Alajouanine & Thurel, 1933). Our patient's clinical findings suggest the opercular syndrome. He began with mutism, deglutition and mastication inability, a bilateral palate palsy, and a brisk jaw reflex. He had a deep buccolinguofacial apraxia, and a mild left hemiparesis. The automatic-voluntary dissociation was patent. The patient was aphonic and anarthric but was able to communicate by writing. Assal, Perentes, & Dervaz (1981) reported a right-handed patient with a global aphasia and some symptoms similar to our patient, such as difficulty in lower facial and

buccorespiratory movements, either on command or to imitation, limb apraxia, left side hemispatial neglect, spatial dysgraphia, and a severe depression. The lesion was within the territory of the middle cerebral artery sparing the entire cerebral cortex except the insula, but affecting the lower part of the centrum semiovale and the upper portion of both anterior and posterior limbs of the internal capsule. Laterally, the lesion extended into the lower and medial portion of the superior T gyrus (T1) and into the entire insula. Even though the lesion was restricted to the right hemisphere, the authors emphasized that the external configuration of the Sylvian fissure had a reverse pattern to that seen in most right-handed individuals, suggesting an altered cerebral dominance pattern.

Our patient had pathology involving the entire insula and extended slightly into the frontotemporoparietal operculum, but spared the external cortical surface in the right and the entire left hemisphere. A Sylvian fissure typical of most right-handers (Rubens, Mahowald, & Hutton, 1976) was demonstrated. We believe our case is the first description of a bilateral opercular syndrome due to a right-hemispheric lesion. As our patient had a total insular infarction with hardly any involvement of the rolandic operculum, we suggest that the classic opercular syndrome, hitherto ascribed to opercular lesions, may be mainly attributable to insular damage. Further support may be found in the literature, as insular damage is regularly reported as a feature of the opercular syndrome. In addition, the importance of insular lesions in the etiology of oral apraxia has also been stressed (Tognola & Vignolo, 1980).

A brief literature review is in order before discussing the aphemia seen in our patient. There are several descriptions of patients with aphonia and anarthria. Dejerine (1891) described two patients with a long-lasting aphonia. One had a lesion which involved, in addition to the lower precentral gyrus, large portions of the white matter underlying the third frontal convolution and lower perirolandic cortex of the left hemisphere. His other patient also showed a white matter lesion in the region of the left frontal convolution, precentral cortex, and anterior insula. Both patients exhibited a right vocal fold paresis. Rosenblath (1907) presented another case of aphonia with a left hemisphere lesion in the precentral and lower postcentral cortex, Broca's area, insula, claustrum, and putamen. Dimitri (1933) described two completely mute patients, both having lesions which invaded insula, claustrum, putamen, and white matter underlying the facial cortex and Broca's area. Other lesions may cause mutism, such as left-side supplementary motor area (Botez, 1960; Damasio & Van Hoesen, 1980), anterior cingulate cortex (Rubens, 1975; Buge, Escourrolle, Rancurel, & Poisson, 1975), and extensive right frontoparietal damage (Ludwig, 1939). Jurgens, Kirzinger, and Von Cramon (1982) presented a patient with a deep reaching left-sided lesion which involved Broca's area, the pre- and postcentral cortex, rolandic operculum, the inferior

parietal cortex, insula, claustrum, parts of the putamen and white matter underlying the inferior frontoparietal, and insular cortex. He was aphonic for more than 10 weeks following the insult. Phonation recovered to a slightly breathy but monotonous voice with a reduced singing capacity. During the aphonic period, there was a complete bilateral paresis of the vocal folds and lower facial and tongue muscles, accompanied by dysarthria and buccolingual apraxia. The lesion involved several brain areas which have been shown to receive substantial projection from the cortical larynx area (Broca's area, postcentral and adjacent parietal cortex, insula, claustrum, and putamen). The author suggested that the prolonged aphonia was partially due to involvement of those structures.

Our patient presented an opercular syndrome with aphonia, anarthria, and a palatal palsy. Seven days later he began to utter some guttural sounds, and laryngoscopy showed normal motility of the vocal folds. Fourteen days later normal palate motility and reflex were observed, and he began to articulate some vowels. Two days later he began to utter simple words.

Jurgens et al. (1982) observed that their patient's vocal fold palsy was bilateral despite demonstration of a unilateral (left-sided) lesion. It is known that the electrical stimulation of the cortical larynx area in one hemisphere produces movements of both vocal folds (Foerster, 1936) and that the left hemisphere seems to dominate the right one in phonatory behavior (Conrad, 1948). In our patient, both hemispheres seemed equally important for phonatory behavior, thus explaining his rapid phonatory recovery. Insulocingulate connections were severed which probably contributed to the phonatory impairment. In fact, the anterior cinguli has been reported to function as a drive-controlling mechanism of phonation with mutism a result of focal impairment (Jurgens & Von Cramon, 1982). Moreover, while bilateral destruction of the rolandic operculum produces permanent inability to modulate phonation voluntarily, after unilateral lesions, the state seems to be temporary, as in Jurgens's et al. (1982) and our patients.

Our patient regained phonation before articulatory control, as is common in Broca's aphasics (Lecours & Lhermitte, 1976; Mohr, Pessin, Finkelstein, Funkenstein, Duncan, & Davis, 1978); the reverse was true for the patient of Jurgens et al., (1982) who suggested that a patient can begin with complete aphonia, progress to a stage in which phonation can be initiated but not controlled in its acoustic structure, and end in a stage in which sounds of different pitch can be produced, although lacking in accurate and reliable phonatory control. The stage characterized by the inability to initiate phonation voluntarily with retained ability to utter nonverbal emotional vocalizations could not be detected in their patient. Our patient soon recovered his phonatory abilities, could utter nonverbal emotional vocalizations, and ended with an ability to articulate simple words. This

case underlines the importance of the operculoinsular structures in the phonatory and articulatory language functions, and constitutes a rare case of crossed aphemia.

## REFERENCES

- Alajouanine, T., & Thurel, R. 1933. La diplegie faciale cerebrale forme corticale de la paralysie pseudobulbaire. *Revue Neurologique*, **2**, 441-458.
- Assal, G., Perentes, E., & Deruaz, J. P. 1981. Crossed aphasia in a right handed patient. Postmortem findings. *Archives of Neurology*, **38**, 455-458.
- Botez, M. J. 1960. Clinical contribution to the study of tumoral frontal syndrome. *Psychiatrie und Neurologie*, **140**, 347-368.
- Bruyn, G. W., & Gathier, J. C. 1969. The operculum syndrome. In P. J. Vinken & G. W. Bruyn, (Eds.), *Handbook of clinical neurology*. Amsterdam: Elsevier.
- Buge, A., Escourolle, R., Rancurel, G., & Poisson, N. 1975. Mutisme akinetique et ramollissement bi-cingulaire. Trois observations anatomo-cliniques. *Revue Neurologique*, **131**, 121-137.
- Chateau, R., Fau, R., Gros Lambert, R., Perret, J., Boucharlat, J., & Chatelain, R. 1966. A propos de trois observations de diplegie linguo-facio-masticatrice d'origine corticale: la forme de l'adulte et celle de l'enfant. *Revue Neurologique*, **114**, 390-395.
- Conrad, K. 1948. Strukturanalysen hirnpatologischer fälle. IV Mitteilung. Über subcorticale motorische aphasia. *Archiv für Psychiatrie und Nervenkrankheiten*, **180**, 54-104.
- Damasio, A. R., & Van Hoesen, W. 1980. Structure and function of the supplementary motor area. *Neurology*, **30**, 359.
- Dejerine, M. J. 1891. Contribution a l'etude de l'aphasie motrice sous-corticale et de la localization cerebrale des centres larynges (muscles phonateurs). *Compte Rendu des Seances de la Societe de Biologie*, **43**, 155-162.
- De Renzi, E., & Vignolo, L. A. 1962. The Token test: A sensitive test to detect disturbances in aphasias. *Brain*, **85**, 665-678.
- Dimitri, V. 1933. *Afasiyas. Estudio anatomoclinico*. Buenos Aires: El Ateneo.
- Ferrari, G., Bonisegna, C., & Beltramello, A. 1979. Foix-Chavany syndrome: Ct study and clinical report of three cases. *Neuroradiology*, **18**, 41-42.
- Foix, C., & Chavany, J. A. 1926. Diplegies faciales d'origine corticale. *Annales de Medicine*, **480**.
- Foix, C., Chavany, J. A., Marie, J. 1926. Diplegie facio-linguo-masticatrice d'origine cortico-sous corticale sans paralysie de membres. *Revue Neurologique*, **1**, 214-219.
- Foerster, O. 1936. Motorische felder und bahnen. In O. Bumke & O. Foerster, (Eds.), *Handbuch der Neurologie*. Berlin: Springer. Vol. VI.
- Jurgens, U., Kirzinger, A., & von Cramon, D. 1982. The effects of deep reaching lesions in the cortical face area on phonation. A combined case report and experimental monkey study. *Cortex*, **18**, 125-140.
- Jurgens, U., & von Cramon, D. 1982. On the role of the anterior cingulate cortex in phonation: A case report. *Brain and Language* **15**, 234-248.
- Lecours, A. R., & Lhermitte, F. 1976. The "pure form" of the phonetic desintegration syndrome (pure anarthria); anatomoclinical report of a historical case. *Brain and Language*, **3**, 88-113.
- Ludwig, M. E. 1939. Beitrag zur frage der bedeutung der unterwertigen hemisphäre. *Zeitschrift für die Gesamte Neurologie und Psychiatrie*, **164**, 735-747.
- Mohr, J. P., Pessin, M. S., Finkelstein, S., Funkenstein, H. H., Duncan, G. W., & Davis, K. R. 1978. Broca aphasia: Pathologic and clinical. *Neurology*, **28**, 311-324.
- Oldfield, R. C. 1971. The assessment and analysis of handedness: The Edinburgh Inventory. *Neuropsychologia*, **9**, 97-113.



- Pertuisset, B., & Perrier, F. 1960. Le syndrome operculaire unilateral (rolandique inferieur) d'origine vasculaire. *Revue Neurologique*, **103**, 63-64.
- Rosenblath, W. 1907. Ein fall von erweichung in linken stirnhirn mit motorischer aphasia, agraphie und alexie und simptomen von pseudobulbarparalyse. *Deutsche Zeitschrift fur Nervenheilkunde*, **33**, 195-209.
- Rubens, A. B. 1975. Aphasia with infarction in the territory of the anterior cerebral artery. *Cortex*, **11**, 239-250.
- Rubens, A. B., Mahowald, M. W., & Hutton, J. T. 1976. Asymmetry of the lateral (Sylvian) fissures in man. *Neurology*, **26**, 620-624.
- Schiff, H. B., Alexander, M. P., Naeser, M. A., & Galaburda, A. M. 1983. Aphemia: Clinical anatomic correlations. *Archives of Neurology* **40**, 720-727.
- Schott, B., Boulliat, G., Cotte, L., & Vauterin, C. 1961. Le syndrome operculaire bilateral et unilateral. *Lyon Medicale*, **206**, 365-378.
- Tognola, G., & Vignolo, L. A. 1980. Brain lesions associated with oral apraxia in stroke patients: A clinico-neuroradiological investigation with the CT scan. *Neuropsychologia*, **18**, 257-272.