

Clinical practice

Bilateral arachnoid cyst-associated subdural fluid collections in an infant following TBI



Katherine W. Canty^{a,*}, Mark S. Shiroishi^b, Gabriel Zada^c, Supriya Sharma^a,
Melissa A. Jimenez^a

^a Department of Pediatrics, Harbor-UCLA Medical Center, Torrance, CA, United States

^b Department of Radiology, LAC-USC Medical Center, Los Angeles, CA, United States

^c Department of Neurological Surgery, Keck School of Medicine, University of Southern California, Los Angeles, CA, United States

ARTICLE INFO

Keywords:

Congenital arachnoid cyst
Abusive head trauma
Subdural fluid collection
Infant
Traumatic brain injury

ABSTRACT

Introduction: arachnoid cyst-associated subdural fluid collections have been documented in children and adults following traumatic brain injury (TBI). However, this phenomenon has not been previously demonstrated in infants less than 12 months of age. We present a case of an infant with bilateral arachnoid cyst-associated subdural fluid collections identified after TBI.

Case presentation: a 9-month-old female infant with profound macrocephaly presented to medical care with altered mental status following a witnessed fall down steps while unsecured in a stroller. Neuroimaging revealed bilateral subdural fluid collections, in addition to a hyperdense subdural hematoma, that raised concern for abusive head trauma (AHT) among the pediatric inpatient team and the hospital's Suspected Child Abuse and Neglect (SCAN) Team was consulted. After excluding occult abusive injuries as well as testing for underlying medical conditions, the infant's bilateral subdural fluid collections were attributed to rupture of a pre-existing left middle cranial fossa arachnoid cyst with evidence of prior macrocephaly.

Conclusion: In infants and toddlers, the identification of subdural fluid collections on neuroimaging warrants inclusion of AHT in the differential diagnosis. However, in infants with a history of congenital macrocephaly, and an otherwise negative AHT workup, an accidental mechanism for the formation of subdural collections should be considered, especially when co-occurring with an arachnoid cyst.

1. Background and importance

Arachnoid cysts have a reported incidence of 2.4% in children and 1.4% in adults.^{1,2} They are most often asymptomatic and found incidentally on imaging but have been associated with neurological syndromes. The location of an arachnoid cyst may impact the patient's clinical presentation and symptoms, such as those in the suprasellar region that can disrupt the hypothalamic-pituitary-axis and cause endocrinopathies.³ In general, when symptoms are present, they are vague, ranging from headache, nausea and vomiting to papilledema and diplopia. In an infant, an enlarging head circumference may be the only presenting feature.

While cases of arachnoid cyst-associated subdural hygromas and hematomas following traumatic brain injury (TBI) have been well-documented in children and adults, few cases have been reported in very young children, and none in infants under 12 months of age

(Table 1).^{4,5,11,14-25} A case series of subdural hygromas resulting from traumatic rupture of arachnoid cysts was reported in 3 children (6–13 years) who underwent operative management. Prior to the onset of symptoms, each child had a history of TBI, including a “mild” football injury and a fall.⁴

Similarly, in a case series of 8 pediatric patients with arachnoid cysts and coexistent subdural hygromas, 6 patients had a history of antecedent TBI. Two of the patients described were toddlers, including a 12-month-old female who had fallen from her crib 1-month prior. In 4 of the cases, the subdural collections were bilateral.⁵

We report a rare case of a 9-month-old infant with bilateral arachnoid cyst-associated subdural fluid collections that prompted initial consideration of abusive head trauma (AHT). In children under 2 years of age, AHT is responsible for more than half of fatal head injuries.⁶ AHT refers to inflicted cranial, intracranial, and spinal injuries that result from a number of biomechanical forces including blunt force trauma,

* Corresponding author. Department of Pediatrics, Harbor-UCLA Medical Center, 1000 W. Carson Street, Torrance, CA, 90502, United States.

E-mail address: kcanty@dhs.lacounty.gov (K.W. Canty).

<https://doi.org/10.1016/j.jflm.2021.102189>

Received 16 March 2021; Received in revised form 29 April 2021; Accepted 10 May 2021

Available online 21 May 2021

1752-928X/© 2021 Elsevier Ltd and Faculty of Forensic and Legal Medicine. All rights reserved.

Table 1

Review of published case reports and series describing the association between arachnoid cysts and subdural fluid collections.

Publication	Number of Patients	Patient Ages	Presenting Symptoms	Trauma History	Location of Cyst
¹¹ Cullis and Gilroy 1983	1	11 years	Recurrent, unilateral headaches	Absent	Middle cranial fossa
¹⁴ Yamanouchi et al. 1986	1	9 years	Headache, nausea, vomiting, drowsiness	Present	Middle Cranial Fossa
¹⁵ Rakier and Feinsod 1995	1	13 years	Headache, bulging of unilateral temporal bone	Absent	Middle cranial fossa
¹⁶ Albuquerque and Giannotta 1997	5	6–25 years	Included lethargy, confusion, headaches, and nausea	Present in 4 cases	Middle cranial fossa 1 patient also had a quadrigeminal cyst
¹⁷ Ergun et al. 1997	1	14 years	Headache, nausea, vomiting, and right hemiparesis	Absent	Middle cranial fossa
¹⁸ Parsch et al. 1997	16	5–80 years	Included headaches, seizure, hemiparesis and alterations in mental status	Present in 14 cases and mostly minor	15 had cysts in the middle cranial fossa, of which 1 also had a posterior fossa cyst 1 patient had a cyst adjacent to the sylvian fissure
¹⁹ Sener 1997	1	12 years	Sudden onset headache and various signs of increased intracranial pressure	Absent	Middle cranial fossa
²⁰ Choong and Lee 1998	1	9 years	Episodic headache and vomiting	Absent	Middle cranial fossa
²¹ Cayli 2000	1	12 years	Headache, nausea, and vomiting	Absent	Middle cranial fossa
²² Donaldson et al. 2000	2	5 and 14 years	Headache, nausea, vomiting, lethargy	Present and described as mild	Middle cranial fossa
⁴ Gelabert-Gonzalez et al. 2002	3	6–13 years	Included headaches, nausea, and vomiting	Present	Middle cranial fossa
⁵ Maher et al. 2013	8	1–12 years	Included headaches, photophobia, transient diplopia, and vomiting, as well as a rapidly enlarging head circumference in the 2 patients who were 12 and 13-months-old	Present in 6 cases	Middle cranial fossa
²³ Khilji et al. 2016	1	9 years	Headaches, nausea, vomiting, and photophobia	Absent	Left temporal
²⁴ Wu et al. 2018	14	1–41 years	Not reported	Present in 8	Majority in middle cranial fossa and cerebral convexity
²⁵ Tinois et al. 2020	10	2–16 years	Headache, vomiting, diplopia/strabismus, partial seizures	Present in 8	Not reported

shaking, or the two in combination.⁷ The differential diagnosis of AHT includes accidental injury and birth trauma, as well as metabolic and hematologic disorders, among others; however, it is rare that these medical entities encompass the full range of clinical findings seen with AHT.⁸ In this specific case, AHT was excluded after multidisciplinary assessment and consultation with the child protection team.

2. Clinical presentation

A 9-month-old female infant with profound macrocephaly presented to the Emergency Department (ED) after becoming acutely altered (Glasgow Coma Scale 3) following a witnessed fall down steps while unsecured in her stroller, with resultant cranial impact. Per history obtained from the infant's mother, the infant was being cared for by her maternal great-aunt at the time of the incident. Reportedly, the maternal great-aunt, who was preparing to take the infant on a walk, exited the home, but lost her footing and grip on the stroller, and the stroller fell down two steps causing the infant to strike her forehead on the ground. The caregiver immediately called 911 and the infant was transported by ambulance to the hospital. In the ED, the infant's neurological status rapidly recovered (Glasgow Coma Scale 15); however, a non-contrast enhanced computed tomography (CT) of the head revealed a comminuted, depressed right frontal skull fracture, a hyperdense subdural fluid collection along the left anterior frontal convexity, bilateral isodense frontal-parietal subdural fluid collections (Fig. 1A–C), benign enlargement of the subarachnoid spaces along the frontal lobes, and a 3-cm extra-axial cyst in the left middle cranial fossa. With the exception of a right frontal hematoma where the infant's forehead had struck the ground, the examination showed no other skin lesions suspicious for physical abuse. However, the hospital's Suspected Child Abuse and Neglect (SCAN) Team was consulted for concerns of AHT as a cause of the intracranial injury and mixed density subdural fluid collections that had been mischaracterized as "bleeds of different ages". When questioned about the patient's past medical history, the mother reported that the infant was delivered vaginally in the breech position. Additionally,

2–3 months prior, she had rolled off a ground-level mattress, impacted her head and cried immediately, but was otherwise asymptomatic. Prior to the TBI, the infant had been healthy with the exception of mild gross motor delay by history, as she was not yet sitting without support.

Further investigation included a review of birth and primary care records which revealed chronic, progressive macrocephaly (Fig. 3). This was presumed to be familial by the pediatrician, as the infant's mother had been affectionately called "tweety bird" as a child due to her large head size. To further evaluate for occult injury, a skeletal survey was performed and did not reveal additional fractures. Magnetic resonance imaging (MRI) of the brain and cervical spine was obtained to characterize the intracranial injury and reaffirmed the findings on CT of bilateral subdural fluid collections and a congenital arachnoid cyst in the left middle cranial fossa (Fig. 2). A dilated fundoscopic exam was notable for bilateral intraretinal hemorrhages centered around the optic nerve. The genetics and neurology services were consulted to evaluate for an underlying medical condition given her macrocephaly and history of gross motor delay. However, the acylcarnitine profile was normal and no genetic defects were identified on whole exome sequencing, thereby excluding glutaric aciduria type 1 (GA1) and several other conditions. GA1 is a rare, metabolic disorder that is often included in the differential diagnosis of AHT, as affected children are at risk of developing subdural hematomas with or without preceding trauma. While the genetic testing was normal, the exclusion of GA1 was also supported by the absence of characteristic neuroimaging findings, such as widening of the sylvian fissures.⁹ Lastly, laboratory testing was performed to assess for a bleeding diathesis and was negative.

Other than being treated prophylactically with Kepra to prevent seizures, the infant's hospital course was unremarkable. After six days, she was discharged home with a referral to a tertiary children's hospital for neurosurgical follow-up without plans for repeat imaging.

3. Discussion

In this rare case presentation, the primary diagnostic dilemma faced

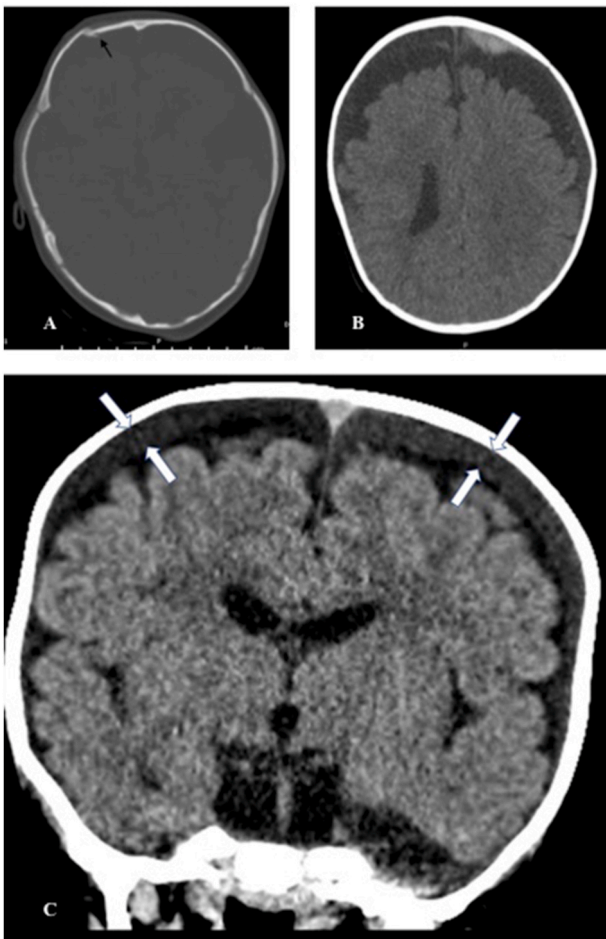


Fig. 1. (A) Axial non-contrast enhanced CT of the head showing a depressed right frontal skull fracture (indicated by black arrow). (B) Axial non-contrast enhanced CT of the head depicting a hyperdense subdural fluid collection along the left anterior frontal convexity most consistent with an acute subdural hematoma. (C) Coronal CT image demonstrating isodense bilateral convexity subdural collections (between white arrows) and subjacent enlarged sub-arachnoid spaces.

by the infant's treating physicians was to differentiate the neuroimaging findings of accidental TBI from those more specific to AHT. Ultimately, it was the determination of the SCAN Team that the infant's right frontal depressed skull fracture and acute left frontal subdural hematoma were consistent with the accidental TBI mechanism provided of the infant falling down steps while in a stroller and striking her head, rather than AHT. While the infant had intraretinal hemorrhages, the hemorrhages lacked characteristic features of those more classically ascribed to AHT. Retinal hemorrhages in AHT are frequently reported as being too numerous to count, bilateral, multilayered, and extending to the ora serrata.¹⁰ Macular retinoschisis and folds can also be present in patients with severe AHT, as can other ocular injuries such as subconjunctival hemorrhage or globe rupture.¹⁰

In contrast, the team hypothesized that the bilateral subdural fluid collections could be attributed to the arachnoid cyst, as previous case reports of arachnoid cyst-associated subdural fluid collections demonstrated communication between the arachnoid cyst and the subdural space intra-operatively.^{4,11} In this case, the presence of pre-existing macrocephaly lends credence to the hypothesis that the infant had a congenital arachnoid cyst and perhaps a form fruste of hydrocephalus,¹² the former of which may have ruptured causing fluid to accumulate within the subdural space.

In a review of subdural hygromas, leading explanations for the

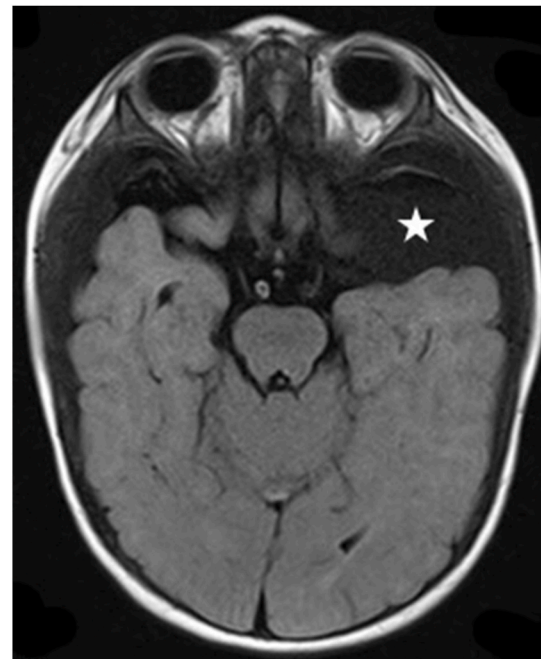


Fig. 2. Axial FLAIR MRI of the brain with an extra-axial cyst in the left middle cranial fossa (marked by a white star).

formation of subdural hygromas were discussed, including: 1) the delayed formation of subdural hygromas from acute subdural hematomas and 2) the rapid formation of subdural hygromas from direct trauma and/or disruption of the arachnoid membrane resulting in accumulation of cerebrospinal fluid in the subdural space.¹³ Interestingly, rupture of pre-existing arachnoid cysts as a cause of subdural hygromas was theorized, but had not yet been described in infants, until now.¹³

4. Conclusion

AHT should be high on the differential in any non-ambulatory infant with intracranial hemorrhage. However, in patients with known macrocephaly and history of low-impact trauma, congenital arachnoid cysts can be a cause of subdural fluid collections, and should be investigated for and ruled out prior to an AHT diagnosis.

CRediT authorship contribution statement

Katherine W. Canty: Conceptualization, the case report, drafted the initial manuscript, reviewed and revised the manuscript. **Mark S. Shiroishi:** Conceptualization, the case report, drafted the initial manuscript, reviewed and revised the manuscript, reviewed the neuroimaging studies and provided consultation. **Gabriel Zada:** Conceptualization, the case report and critically reviewed the manuscript and neuroimaging studies. **Supriya Sharma:** drafted the initial manuscript, performed a literature review, and critically reviewed and revised the manuscript. **Melissa A. Jimenez:** provided the patient case and critically reviewed and revised the manuscript, All authors approve the final manuscript as submitted and agree to be accountable for all aspects of the work.

Declaration of competing interest

The authors have no conflicts of interest to declare.

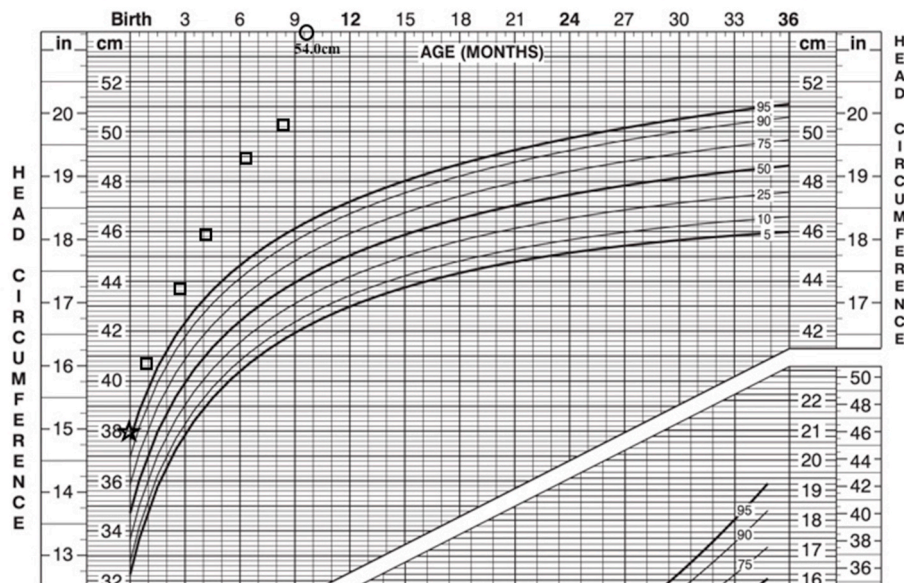


Fig. 3. Head circumference chart documenting the infant’s progressive macrocephaly, including her head circumference on the day of presentation (black circle).

References

- Al-Holou WN, Yew A, Boomsaad Z, Garton HJL, Muraszko KM, Maher CO. Prevalence and natural history of arachnoid cysts in children. *J Neurosurg.* 2010;5: 578–585.
- Al-Holou WN, Terman S, Kilburg C, Garton HJL, Muraszko KM, Maher CO. Prevalence and natural history of arachnoid cysts in adults. *J Neurosurg.* 2013;118: 222–231.
- Jafrani R, Raskin JS, Kaufman A, Lam S. Intracranial arachnoid cysts: pediatric neurosurgery update. *Surg Neurol Int.* 2019;10:15.
- Gelabert-Gonzalez M, Fernandez-Villa J, Cutrin-Prieto J, Garcia Allut A, Martinez-Rumbo R. Arachnoid cyst rupture with subdural hygroma: report of three cases and literature review. *Child’s Nerv Syst.* 2002;18:609–613.
- Maher CO, Garton HJL, Al-Holou WN, Trobe JD, Muraszko KM, Jackson EM. Management of subdural hygromas associated with arachnoid cysts. *J Neurosurg Pediatr.* 2013;12:434–443.
- Choudhary AK, Servaes S, Slovis TL, et al. Consensus statement on abusive head trauma in infants and young children. *Pediatr Radiol.* 2018;48(8):1048–1065.
- Narang SK, Fingarson A, Lukefahr J, Council On Child Abuse And Neglect. Abusive head trauma in infants and children. *Pediatrics.* 2020;145(4), e20200203.
- Wittschieber D, Karger B, Pfeiffer H, Hahnemann ML. Understanding subdural collections in pediatric abusive head trauma. *AJNR.* 2019;40(3):388–395.
- Vester ME, Bilo RA, Karst WA, Daams JG, Duijst WL, van Rijn RR. Subdural hematomas: glutaric aciduria type 1 or abusive head trauma? A systematic review. *Forensic Sci Med Pathol.* 2015;11(3):405–415.
- AAP COUNCIL ON CHILD ABUSE AND NEGLECT, AAP SECTION ON OPHTHALMOLOGY, AMERICAN ASSOCIATION OF CERTIFIED ORTHOPTISTS, AMERICAN ASSOCIATION FOR PEDIATRIC OPHTHALMOLOGY AND STRABISMUS, AMERICAN ACADEMY OF OPHTHALMOLOGY Christian CW, Levin AV. The eye examination in the evaluation of child abuse. *Pediatrics.* 2018;142 (2), e20181411.
- Cullis PA, Gilroy J. Arachnoid cyst with rupture into the subdural space. *J Neurol Neurosurg Psychiatry.* 1983;46:454–456.
- Zada G, Krieger MD, McNatt SA, Bowen I, McComb JG. Pathogenesis and treatment of intracranial arachnoid cysts in pediatric patients younger than 2 years of age. *Neurosurg Focus.* 2007;22(2):E1.
- Wittschieber D, Karger B, Niederstadt H, Pfeiffer H, Hahnemann ML. Subdural hygromas in abusive head trauma: pathogenesis, diagnosis, and forensic implications. *AJNR.* 2015;36:432–439.
- Yamanouchi Y, Sameda K, Oka N. Spontaneous disappearance of middle fossa arachnoid cyst after head injury. *Child’s Nerv Syst.* 1986;2:40–43.
- Rakier A, Feinsod M. Gradual resolution of an arachnoid cyst after spontaneous rupture into the subdural space. *Case Report. J Neurosurg.* 1995;83(6):1085–1086.
- Albuquerque FC, Giannotta SL. Arachnoid cyst rupture producing subdural hygroma and intracranial hypertension: case reports. *Neurosurgery.* 1997;41(4):951–955.
- Ergün R, Ökten AI, Beşkonaklı E, et al. Unusual complication of arachnoid cyst: spontaneous rupture into the subdural space. *Acta Neurochir.* 1997;139:692–694.
- Parsch CS, Krauss J, Hoffman E, Meixensberger J, Roosen K. Arachnoid cysts associated with subdural hematomas and hygromas: analysis of 16 cases, long-term follow-up, and review of the literature. *Neurosurgery.* 1997;40(3):483–490.
- Sener RN. Arachnoid cysts associated with post-traumatic and spontaneous rupture into the subdural space. *Comput Med Imag Graph.* 1997;21(6):341–344.
- Choong CT, Lee SH. Subdural hygroma in association with middle fossa arachnoid cyst: acetazolamide therapy. *Brain Dev.* 1998;20(5):319–322.
- Cayli SR. Arachnoid cyst with spontaneous rupture into the subdural space. *Br J Neurosurg.* 2000;14(6):568–570.
- Donaldson JW, Edwards-Brown M, Luerssen TG. Arachnoid cyst rupture with concurrent subdural hygroma. *Pediatr Neurosurg.* 2000;32(3):137–139.
- Khilji MF, Jeswani NL, Hamid RS, Al Azri F. Spontaneous arachnoid cyst rupture with subdural hygroma in a child. *Case Rep Emerg Med.* 2016;2016, 6964713.
- Wu X, Li G, Zhao J, Zhu X, Zhang Y, Hou K. Arachnoid cyst-associated chronic subdural hematoma: report of 14 cases and a systematic literature review. *World Neurosurg.* 2018;109:e118–e130.
- Tinois J, Bretonnier M, Proisy M, Morandi X, Riffaud L. Ruptured intracranial arachnoid cysts in the subdural space: evaluation of subduro-peritoneal shunts in a pediatric population. *Childs Nerv Syst.* 2020;36:2073–2078.