

Case Report

Isolated sixth nerve palsy as an initial presentation of primary angiitis of the central nervous system

Koji Nakajima^a, Takeshi Yoshida^{a,*}, Kinuko Nishikawa^a, Kengo Kora^a,
Atsushi Yokoyama^a, Naoko Yano^a, Takahiro Hayashi^a, Toru Takaori^a,
Saeko Sasaki^a, Kanako Maizuru^a, Takayuki Kikuchi^b, Junko Takita^a

^a Department of Pediatrics, Kyoto University Graduate School of Medicine, Kyoto, Japan

^b Department of Neurosurgery, Kyoto University Graduate School of Medicine, Kyoto, Japan

Received 11 February 2021; received in revised form 28 April 2021; accepted 1 May 2021

Abstract

Background: Primary angiitis of the central nervous system (PACNS) is a newly-emerging disease, and it is known that early diagnosis with treatment is important for the improvement of prognosis.

Case description: Here, we report the case of a previously healthy 13-year-old girl who presented with right eye abduction failure, attributed to isolated right sixth nerve palsy, as the initial symptom of PACNS. Magnetic resonance angiography (MRA) showed stenosis in the distal portion of the right internal carotid artery, and delay alternating with nutation for tailored excitation (DANTE)-prepared contrast-enhanced magnetic resonance imaging confirmed vasculitis at the same site. The patient was subsequently treated with three courses of pulse corticosteroid therapy (methylprednisolone intravenously 30 mg/kg/day for three consecutive days). Diplopia completely resolved within 3 months after three course of steroid pulse therapy, and when taking 10 mg PSL daily. Follow-up MRA confirmed complete resolution of the arterial narrowing, and no relapse was observed after 2 months of steroid cessation.

Discussion: This case report illustrates an unusual presentation of PACNS with isolated sixth nerve palsy. PACNS was thought to cause insults on a single cranial nerve either through local spread of inflammation or hypoxic-ischemic insults on the nerve root due to involvement of feeding microvessels. The decision to perform imaging studies in cases of isolated sixth nerve palsy remains controversial because of the possibility of spontaneous recovery. Our case supports the existing literature that recommends that even an isolated symptom of unilateral abducens nerve palsy requires timely imaging studies.

© 2021 The Japanese Society of Child Neurology. Published by Elsevier B.V. All rights reserved.

Keywords: Primary angiitis of the central nervous system; Sixth nerve palsy; Magnetic resonance angiography; Pathogenesis

* Corresponding Author at: Department of Pediatrics, Kyoto University Graduate School of Medicine, 54 Kawaharacho, Shogoin, Sakyo-ku, Kyoto 606-8507, Japan.

E-mail address: yoshida.takeshi.3a@kyoto-u.ac.jp (T. Yoshida).

1. Introduction

Primary angiitis of the central nervous system (PACNS) is an increasingly recognized cause of pediatric inflammatory brain diseases. The diagnosis of childhood PACNS is often based on the Calabrese criteria for adults [1]: 1) newly acquired focal or diffuse neurologic deficits or psychiatric symptoms, 2) angiographic and/or histopathologic features in the central nervous system, and 3) in the absence of an underlying systemic inflammatory process.

Neuroimaging often provides conclusive evidence for PACNS. The most typical angiographic finding of childhood PACNS is unilateral involvement of the terminal segment of the carotid artery and the proximal segments of the anterior and middle cerebral arteries [2]. Whether or not PACNS can be detected by angiography depends on the size of the affected vessel. Such angiography-positive PACNS can result in profound and permanent neurological deficits; therefore, timely identification and immunosuppressive treatment are considered crucial [3]. On the other hand, childhood PACNS can present with a wide variety of neurologic deficits and psychiatric symptoms [4]. Owing to its rarity, the initial decision of neuroimaging can be challenging.

Herein, we describe a girl who initially presented with symptoms of isolated sixth nerve palsy. The swift decision to conduct magnetic resonance angiography (MRA) led to the rapid identification and treatment of PACNS, and thus, the successful resolution of her symptoms.

2. Case report

A previously healthy 13-year-old girl presented to our hospital with a three-day history of persistent double vision. Her diplopia progressively worsened over the three days, but she did not report any other symptoms. She also did not recall any preceding infection or vaccination within the past few weeks. Her vital signs were as follows: temperature, 36.8 °C; pulse rate, 78 bpm; respiratory rate, 17 bpm; and blood pressure, 94/56 mm Hg. Neuroophthalmological inspection revealed a limitation in abduction beyond the midline in her right eye (Fig. 1).

The patient showed no sign of Horner's syndrome or any kind of visual disturbance. Otolaryngology examination was normal without evidence of sinusitis or otitis media. The rest of her neurological examination were also normal. A brain CT scan was performed, which showed no abnormalities or any mass lesion suggestive of a tumor. MRI scans with contrast were performed for further evaluation. MRA revealed stenosis of the right internal carotid artery at the C2–C5 level, and also slightly at the C1 and A1 level (Fig. 2A). Delay alternating with nutation for tailored excitation (DANTE)-prepared contrast-enhanced magnetic resonance imaging showed circumferential vessel wall enhancement and thickening at the same site, suggestive of vasculitis (Fig. 3A, C). A coexistent abnormal contrast enhancement of the adjacent right sixth nerve explained her sixth nerve palsy (Fig. 3B, D). The structure with triangular enhancement, located bilaterally lateral to the internal carotid artery, was considered Meckel's cavity (Fig. 3B) [5].

The patient was hospitalized two days later for further tests and treatment. Post-admission computed tomography angiography (CTA) of the head and neck was performed, and right internal carotid artery stenosis was confirmed, without any sites of obstruction or dissection (Fig. 3E, F). The uneven diameter of the vessel wall was noted at the peripheral 3 cm segment adjacent to the right internal carotid bifurcation, which suggested vascular inflammation at the same site. Additional examinations were conducted to rule out other causes of vasculitis. Laboratory blood analysis indicated the following: CRP (C-reactive protein), <0.1 mg/dL; ESR (erythrocyte sedimentation rate) 1hr, 16 mm; D-dimer, <0.3 µg/mL; and serum antibody testing for ANA (antinuclear antibody), MPO-ANCA (myeloperoxidase-anti-neutrophil cytoplasmic antibody), PR3-ANCA (serine proteinase3-anti-neutrophil cytoplasmic antibody), SS-A (anti-Ro antibody), SS-B (anti-La antibody) were all negative. Virus antibody tests were indicative for past infection of herpes simplex virus, varicella-zoster virus, Epstein Barr virus. Whole-body contrast CT ruled out the presence of any underlying systemic vasculitis. Cerebrospinal fluid analysis was normal, except for slightly increased white blood cells.

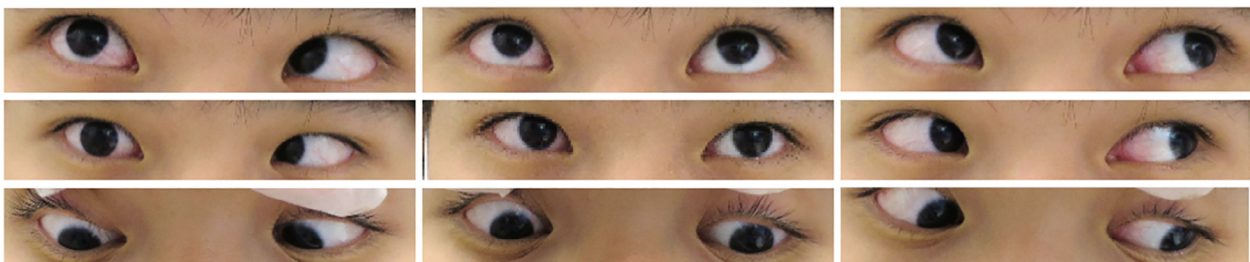


Fig. 1. Isolated limitation of abduction of the right eye shown on a 9-gaze photograph.

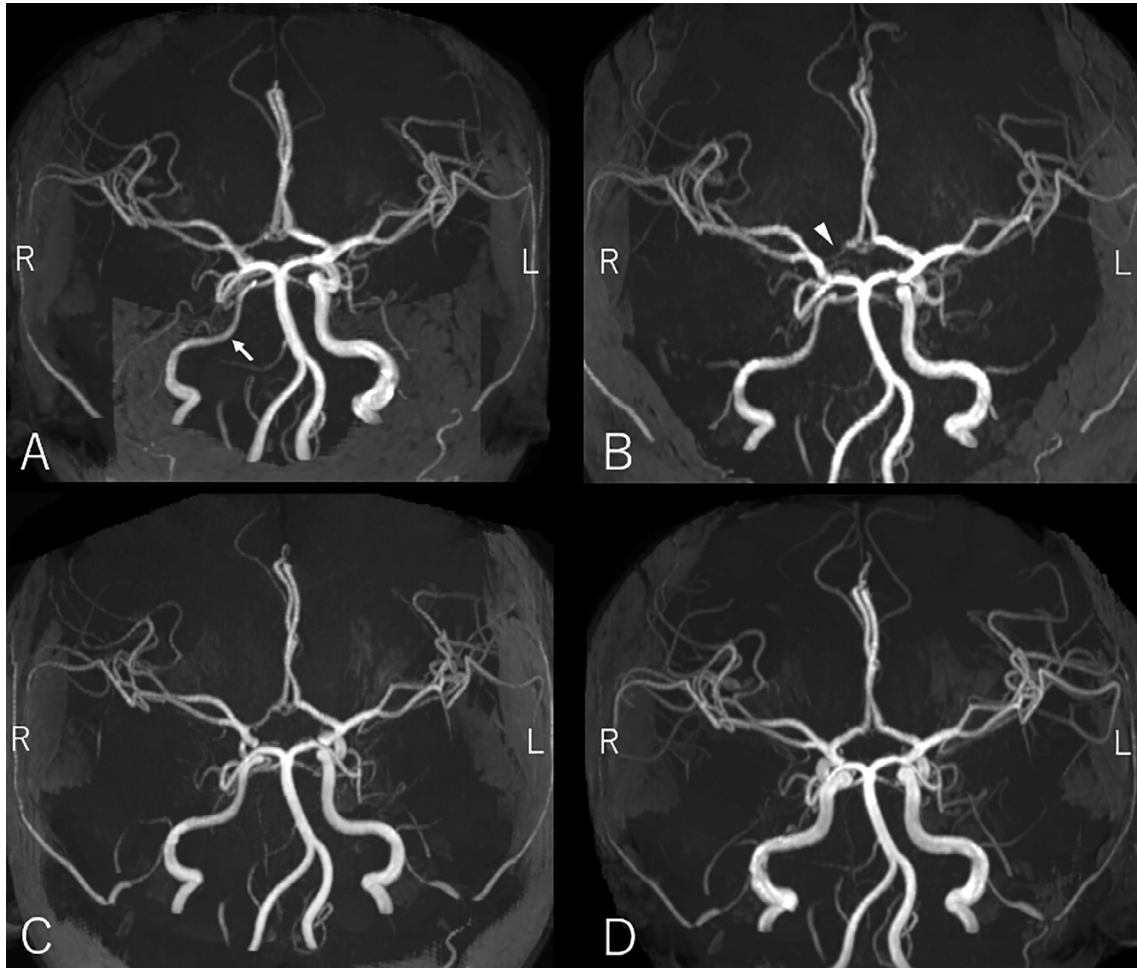


Fig. 2. Serial MRA imaging during and after steroid therapy. Magnetic resonance angiography (MRA) of the brain at admission (A) shows stenosis of the right internal carotid artery (arrow). MRA after one course of pulse steroid therapy (B) shows exacerbation of stenosis of right anterior cerebral artery (arrowhead). MRA after three courses of pulse steroid therapy (C) and 2 months after steroid cessation (D) shows chronological improvement.

Based on these findings, the patient was diagnosed with angiography-positive PACNS and was provided three courses of pulse corticosteroid therapy with methylprednisolone. After the first course, her abduction limitation slightly resolved. Intraluminal thinning and vessel wall enhancement of the right anterior cerebral artery seemed exacerbated (Fig. 2B), but the patient did not show any novel symptoms related to the right anterior cerebral artery vasculitis. After the third course of pulse therapy, treatment with prednisolone (1 mg/kg) was administered. MRI evaluation showed improvement (Fig. 2C) and her symptoms were alleviated; hence, she was discharged.

In the outpatient setting, the patient's steroid dose was tapered off over 4 months, and there were no steroid-related adverse events. Her diplopia completely resolved, and the follow-up MRI conducted 2 months after steroid cessation showed no signs of relapse (Fig. 2D). Written informed consent was obtained from

the patient and her parents for the use of the pictures and the publication of this report.

3. Discussion

We describe a patient with sixth nerve palsy as the initial presentation of PACNS. The presence of vasculitis was identified by MRA and confirmed by subsequent CTA and vessel wall enhancement on DANTE-prepared contrast-enhanced magnetic resonance. Rapid diagnosis and initiation of steroid pulse therapy completely resolved her symptoms, and the dose of steroids could be tapered over a relatively short period.

Childhood PACNS is classified according to the affected vessel size into two types: angiography-positive PACNS (affecting large/middle cerebral vessels) and angiography-negative PACNS (affecting the small cerebral vessels). Angiography-negative childhood PACNS affects small vessels that would not appear on

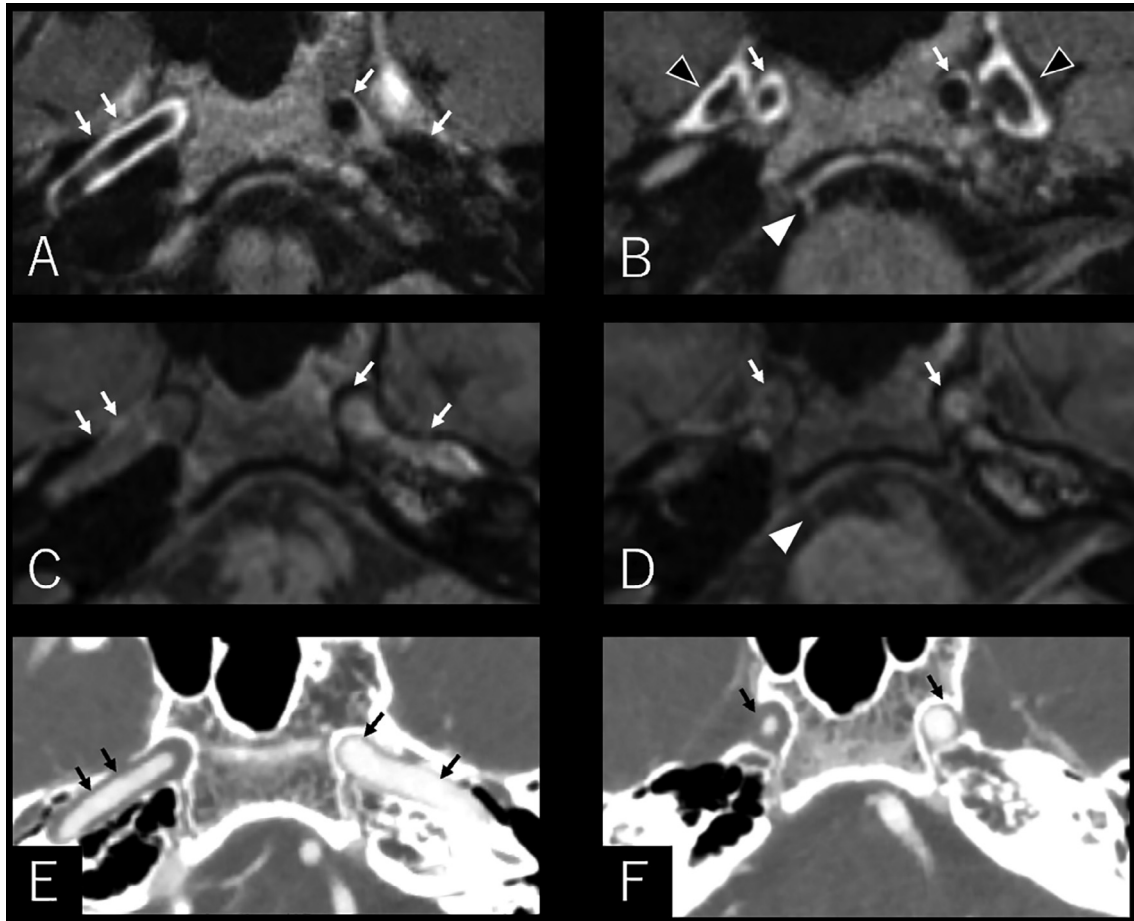


Fig. 3. Brain MRI & CT imaging of the patient on admission. Delay Alternating with Nutation for Tailored Excitation (DANTE)-prepared contrast-enhanced magnetic resonance imaging of the brain (A, B) and non-enhanced T1-weighted imaging (C, D) at admission show wall thickening of the right internal carotid artery (arrow) and abnormal contrast enhancement of the right sixth nerve (white arrowhead). Meckel's cavity is seen lateral to the internal carotid artery (black arrowhead) (B). CT angiography at admission confirms right internal carotid artery stenosis (E, F). Axial views at the level of the ponto-medullary junction (A, C, E) and mid-lower pons (B, D, F), respectively.

neuroimaging; thus, a high level of suspicion would necessitate a brain biopsy for definitive diagnosis. This type of small-vessel PACNS is more likely to present with seizures, cognitive dysfunction, visual abnormalities, and a high level of inflammatory markers [6,7]. On the other hand, angiography-positive PACNS, like in this case, tends to present with focal neurologic deficits, reminiscent of stroke, such as acute hemiparesis, hemisensory deficit, and fine motor deficits [8]. Thus, our report is unique in that although inflammation of a relatively large cerebral vessel was evident in angiography, the patient initially presented with an atypical and subtle symptom of isolated diplopia.

Sixth nerve palsy causes horizontal diplopia and limited outward movement of the affected eye, due to weakness of lateral rectus muscle. As the most common type of cranial nerve palsy in children [9,10], the underlying cause is often tumor or trauma [11]. In our case, potential mechanisms include infarction of the abducens nerve caused by vasculitis of feeding vessels such as the medial

clival artery, which branches from the internal carotid artery [12]. In addition, internal carotid vasculitis itself could have caused the direct spread of inflammation to the adjacent sixth nerve in the cavernous sinus. A similar report of cerebral vasculitis and sixth nerve cranial palsy, caused by the focal inflammation from post-dental treatment, which this patient did not undergo, supports this view [13]. Finally, cerebral vasculitis could also have led to intracranial hypertension, causing compression and subsequent damage to the sixth nerve [14].

When sixth nerve palsy is accompanied by multiple neurologic abnormalities, neuroimaging may be an easy decision. However, the indication for neuroimaging in isolated sixth nerve palsy can be more difficult and controversial. Previous reports suggest that isolated sixth nerve palsy can be closely observed without imaging studies as long as other symptoms and signs do not appear, since most cases resolve spontaneously [15,16]. More recent reports suggest that neuroimaging should be conducted because the possibility of a tumor cannot

be denied [11,17]. Our study adds to the existing literature on the latter, and importantly, not only conventional MRI but also MRA was crucial for the rapid identification of PACNS and prevention of further neurological symptoms.

Declaration of Competing Interest

The authors declare that they have no known competing financial interests or personal relationships that could have appeared to influence the work reported in this paper.

Acknowledgements

The authors would like to thank the patient and families for their cooperation in this study. The authors would also like to thank Editage (www.editage.com) for English language editing.

References

- [1] Calabrese LH, Mallek JA. Primary angiitis of the central nervous system. Report of 8 new cases, review of the literature, and proposal for diagnostic criteria. *Medicine (Baltimore)*. 1988;67:20–39.
- [2] Aviv RI, Benseler SM, Silverman ED, Tyrrell PN, Deveber G, Tsang LM, et al. MR imaging and angiography of primary CNS vasculitis of childhood. *AJNR Am J Neuroradiol*. 2006;27:192–9.
- [3] Smitka M, Bruck N, Engelland K, Hahn G, Knoefler R, von der Hagen M. Clinical Perspective on Primary Angiitis of the Central Nervous System in Childhood (cPACNS). *Front Pediatr*. 2020;8:281.
- [4] Twilt M, Benseler SM. The spectrum of CNS vasculitis in children and adults. *Nat Rev Rheumatol*. 2011;8:97–107.
- [5] Leclercq D, Thiebaut JB, Héran F. Trigeminal neuralgia. *Diagn Interv. Imaging*. 2013;94:993–1001.
- [6] Cellucci T, Tyrrell PN, Sheikh S, Benseler SM. Childhood primary angiitis of the central nervous system: identifying disease trajectories and early risk factors for persistently higher disease activity. *Arthritis Rheum*. 2012;64:1665–72.
- [7] Benson CE, Knezevic A, Lynch SC. Primary Central Nervous System Vasculitis With Optic Nerve Involvement. *J Neuroophthalmol*. 2016;36:174–7.
- [8] Benseler SM, Silverman E, Aviv RI, Schneider R, Armstrong D, Tyrrell PN, et al. Primary central nervous system vasculitis in children. *Arthritis Rheum*. 2006;54:1291–7.
- [9] Kodsi SR, Younge BR. Acquired oculomotor, trochlear, and abducent cranial nerve palsies in pediatric patients. *Am J Ophthalmol*. 1992;114:568–74.
- [10] Holmes JM, Mutyala S, Maus TL, Grill R, Hodge DO, Gray DT. Pediatric third, fourth, and sixth nerve palsies: a population-based study. *Am J Ophthalmol*. 1999;127:388–92.
- [11] Dotan G, Rosenfeld E, Stolovitch C, Kesler A. The role of neuroimaging in the evaluation process of children with isolated sixth nerve palsy. *Childs Nerv Syst*. 2013;29:89–92.
- [12] Moore PM, Cupps TR. Neurological complications of vasculitis. *Ann Neurol*. 1983;14:155–67.
- [13] Ivancic BD, Jovanovic I, Ljevak J, Poljakovic Z. Sixth cranial nerve palsy and ipsilateral segmental carotid arteritis after tooth alveolectomy. *Neurol Sci*. 2019;40:1975–7.
- [14] Dursun I, Gunduz Z, Poyrazoglu HM, Gumus H, Yikilmaz A, Dusunsel R. Cerebral vasculitis and unilateral sixth-nerve palsy in acute post-streptococcal glomerulonephritis. *Ann Trop Paediatr*. 2008;28:155–9.
- [15] Aroichane M, Repka MX. Outcome of sixth nerve palsy or paresis in young children. *J Pediatr Ophthalmol Strabismus*. 1995;32:152–6.
- [16] Burde RM, Savino PJ, Trobe JD. Clinical decisions in neuro-ophthalmology. 3rd ed. Philadelphia: Mosby; 2009. p. 171–2.
- [17] Brodsky MC. Pediatric neuro-ophthalmology. 2nd ed. New York: Springer; 2010. p. 281–93.