

CHANGES IN SENSORY INATTENTION, DIRECTIONAL MOTOR NEGLECT AND “RELEASE” OF THE FIXATION REFLEX FOLLOWING A UNILATERAL FRONTAL LESION: A CASE REPORT

CHARLES M. BUTTER,* STEVEN RAPCSAK,† ROBERT T. WATSON and KENNETH M. HEILMAN

Department of Neurology, College of Medicine, University of Florida and Veteran's Administration Medical Center, Gainesville, Florida, U.S.A.

(Received 25 May 1987; accepted 9 December 1987)

Abstract—We recorded eye movements to and away from visual stimuli from a patient with left-sided neglect following a right frontal infarct in order to determine (a) whether and to what extent his neglect was due to sensory inattention and directional motor neglect and (b) whether he had difficulty suppressing inappropriate eye movements to visual stimuli (“release” of visual grasp) as his sensory inattention declined. In the first testing session, conducted 5 days following his stroke, he often failed to move his eyes when a stimulus on the left required a rightward eye movement, but he consistently moved his eyes to a stimulus on the right. Thus, he showed contralateral but not ipsilateral sensory inattention. Initially, he also was impaired in making leftward eye movements when right stimuli were presented. Thus, he also showed a directional motor neglect. In subsequent tests, his left-sided sensory inattention as defined above decreased, and was no longer present three weeks following his stroke, nor in a follow-up test conducted almost 6 months following this stroke. In contrast, his directional motor neglect, as defined above, was still present in the follow-up test. As his left-sided sensory inattention declined, his tendency to move his eyes incorrectly to stimuli on the left side (the side contralateral to his lesion) when these stimuli required eye movements to the right became stronger (“release” of visual grasp); he continued to show this strong tendency in the test conducted almost 6 months following his stroke.

INTRODUCTION

INVESTIGATIONS of frontal lobe lesions in animals and humans have disclosed both decreased responses (i.e. neglect) [1, 8, 9, 11, 16, 26, 28, 31, 33, 37, 38] and increased or “released” orienting responses to external stimuli [3, 13, 24, 25]. It is not clear when or under what conditions these opposed effects of frontal lobe lesions appear. Furthermore, there have been few attempts to determine whether neglect following frontal lobe lesions is sensory, motor (i.e. hemispatial and directional akinesia), or both. A sensory basis of neglect is suggested by the finding that monkeys with unilateral frontal eye field lesions show a contralateral impairment of visual detection when detection is evaluated by responses that are not directed to the visual stimulus [28]. Evidence for sensory neglect following frontal lesions is provided

*Address correspondence to: Charles M. Butter, Neuroscience Laboratory, 1103 E. Huron St., Ann Arbor, MI 48109, U.S.A.

†Department of Neurology, University of Arizona Health Sciences Center, Tucson, Arizona, U.S.A.

by findings of contralateral inattention to sensory stimuli in humans with frontal lobe lesions [9, 16]. On the other hand, evidence has also been presented for a motor component in neglect following frontal lesions in monkeys [37]; in addition, contralateral motor neglect has been described in patients with unilateral frontal lesions [5, 31]. However, in only one study involving monkeys [37] and one with human subjects [1] have both sensory and motor aspects of neglect been investigated in the same subjects.

Recently we had the opportunity to test a patient with unilateral neglect following a right frontal lesion in a situation where we recorded his eye movements to and away from visual stimuli. Thus, we could determine whether and to what extent his neglect was sensory, motor or both, and whether he had difficulty suppressing inappropriate eye movements to visual stimuli ("release" of visual grasp). Since we tested this patient on several occasions, we also had the opportunity to trace the time course of his deficits and thus further clarify the relationship between visual neglect and release of visual grasp.

CASE REPORT

The patient was a 63-yr old, right-handed man with 3 yr of college education. He had a history of treated hypertension. On 5/9/86 his coworkers noted that he was having difficulty using his left hand, and he was admitted to a local hospital. Two days later, he was transferred to the Gainesville VAMC for further evaluation. He complained of some difficulty with his left hand but denied other problems.

His general physical examination was unremarkable, except for a blood pressure of 168/90. His neurological examination revealed that he was alert and oriented to person, place and time. He had left-sided neglect on letter cancellation and line bisection. Whereas he responded to most visual, auditory and tactile stimuli presented on the left side, he showed extinction in all three modalities. He also showed poor visuospatial ability as disclosed by his defective drawing. Whereas his propositional speech was intact, he showed a marked lack of prosody in his speech, which was still evident when he was retested several days later. However, he was able to recognize emotional tone in the examiner's speech. His recent and remote memory were intact. His cranial nerves were normal except for a mild left facial weakness. Pain, temperature, light touch and joint position sense on the left were decreased. He had mild weakness on the left side of the body, especially distally, which interfered with fine movements of the fingers.

Cerebellar tests and gait were normal. Although his reflexes were symmetric, he had an extensor plantar response on the left. Forced grasping was not present. When movements were elicited to command, he showed some motor perseveration as well as impersistence. Laboratory tests at admission were normal, except for mild leukocytosis (14,000). His waking EEG showed right-sided slowing in the delta range, superimposed on alpha activity. A computerized tomographic scan (CT) on the day of admission to the VAMC showed a hypodense area in the right prefrontal and premotor cortex, including the frontal eye field, and extending slightly into the Sylvian fissure, the motor strip and adjacent postcentral gyrus (see Fig. 1). The posterior parietal lobe and occipital lobe showed no abnormalities. Another CT scan taken 3 days later (approximately 7 days following his stroke) was unchanged.

He showed gradual improvement in the use of his left hand and arm over the course of his stay in the hospital; his visual and tactile extinction also became less severe over this period.

METHOD

In formal testing, eye movements were recorded with Ag-AgCl electrodes (Beckman) attached to the external canthi. DC potentials were amplified and recorded on a Grass polygraph (7WC 20PA). In the first testing session, conducted 3 days following his admission, the patient was initially instructed to move his eyes from a central fixation point (the examiner's nose) to the examiner's left or right index finger (located approximately 30° laterally) when one of them moved (uncrossed-response test). Next, he was instructed to fixate the examiner's nose and, when the examiner moved his index finger, to move his eyes to the side opposite it and toward the index finger that was not moving (crossed-response test). In three subsequent sessions, conducted over a 17-day period, the visual stimuli were provided by two, 28-V red-jeweled lamps, located on a black perimeter, 30° to the left and right of the center. The lamps were 1.2 cm in diameter; at the viewing distance employed they subtended 1.3°. During testing, he sat facing the perimeter with his chin in a molded support. In the first series of trials (uncrossed-response test) he was instructed to fixate a small spot in the center of the perimeter and to move his eyes to a lamp when it was briefly illuminated (0.5–0.75 sec). After completing the first series of trials, he was instructed to move his eyes from the fixation spot to the unilluminated lamp on the side opposite the one briefly illuminated (crossed-response test). In each session stimuli were presented 18–30 times in each of the two series of trials, approximately 50% on each side. In each series, stimuli were presented in a pseudorandom sequence. Approximately 6 months later, his eye

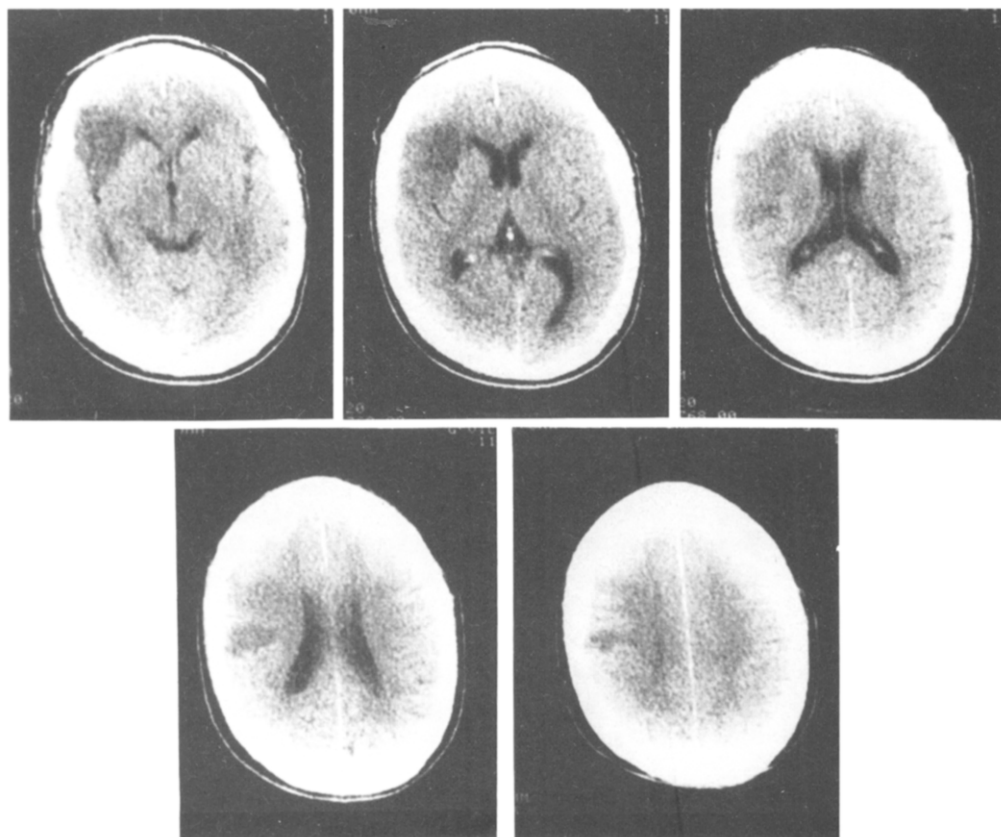


FIG. 1. CT scan at five levels showing patient's right frontal infarct.

movements were again recorded while he moved his eyes toward and away from illuminated lamps by the same procedures used in the previous three sessions.

The control subjects were five men ranging in age from 53 to 66 yr (mean age = 62 yr). They were free of neurological disease involving the brain and had no eye movement disorders. None had histories of alcohol or drug abuse. Their eye movements were recorded while they were tested in a single session by the same procedures employed with the patient in the last four sessions. In the uncrossed-response test, failure to move the eyes toward a stimulus contralateral to the lesion could be attributed either to sensory neglect or to directional motor neglect or to both. However, in the crossed-response test, failure to move the eyes when a stimulus is presented on the side contralateral to the lesion cannot be explained by motor neglect and indicates sensory neglect. Furthermore, when stimuli are presented ipsilateral to the lesion in the crossed-response test, failure to move the eyes away from the stimulus and into contralateral hemispace cannot be explained by sensory neglect and suggests directional motor neglect. Finally, in our test, release of visual grasp to a stimulus is indicated by initially moving the eyes toward the stimulus (even if it is followed by a correct eye movement to the right) in the crossed-response test.

RESULTS

Table 1 shows the two kinds of errors that the patient and his controls made in testing—incorrect eye movements and failures to perform eye movements—when they were presented with stimuli on each side in the uncrossed- and crossed-response tests. Whereas the control's subjects made very few errors in any of the conditions of testing, the patient made considerably more errors in both the uncrossed and crossed-response tests. Furthermore, the severity of his impairments in some of the tests varied with the time of testing.

With regard to his performance with the uncrossed-response tests, his total errors in moving his eyes toward left-sided stimuli (the side contralateral to his lesion), which provide a measure of his overall left-sided neglect, was 23.3% in the first session. In contrast, in the same session, his total errors in moving his eyes toward stimuli on the right side, which provide a measure of his overall right-sided neglect, was only 3.3% over the next three sessions, which spanned a 16-day period. A similar result was obtained when he was retested approximately 6 months after his stroke (see Table 1).

With regard to his performance in the crossed-response tests, his total errors in moving his eyes to the side that he neglected (the left) in response to stimuli presented on the opposite side were substantial in the first two sessions (20.6 and 31.0%). Although his total errors in this testing condition declined somewhat in sessions 3 and 4, in the final session they were as frequent as they had been in the first session.

Second, when stimuli were presented on the left side in the crossed-response test of the first session, the patient's failure to move his eyes, which assesses his sensory inattention to the left independently of his motor neglect, was evident in a large number of trials (38.7%). Over the next three sessions, the frequency with which he failed to perform eye movements in this testing condition declined and was zero in the final session (see Table 1).

Thirdly, whereas initially, the patient made very few incorrect eye movements to stimuli presented on the left side in the crossed-response test; in subsequent sessions his tendency to inappropriately move his eyes to left-sided stimuli grew stronger until, in the final session, he did so on more than 80% of the trials. On most of the trials in which he made these errors, he performed corrective saccades to the right. In contrast to his increasing tendency to look toward left-sided stimuli in the crossed-response tests, his tendency to inappropriately move his eyes toward stimuli presented on the right side in the crossed-response tests, which varied between 10 and 23%, did not increase over the five testing sessions (see Table 1).

The patient's deficit in moving his eyes to the left when right-sided stimuli were presented in early testing sessions was accompanied by other eye movement deficits. When DC

Table 1. Percent incorrect (Inc. E.M.) and no eye movement (No. E.M.)* of patient (PT.) in each session and control subjects (Cont.)†

Session (days following stroke)		1 (5)		2 (12)		3 (14)		4 (21)		5 (170)	
Test	Stim. position	%Incorr E.M.	%No E.M.	%Incorr E.M.	%No E.M.	%Incorr E.M.	%No E.M.	%Incorr E.M.	%No E.M.	%Incorr E.M.	%No E.M.
Uncrossed-response	L PT.	3.3	20.0	0.0	16.0	3.7	15.1	0.0	9.5	0	6.2
	Cont.	0.0	0.0								
	R PT.	0.0	3.3	5.5	5.5	0	0	4.5	9.1	0	7.1
	Cont.	0.0	1.0 (0 5.0)								
Crossed-response	L PT.	3.2	38.7	12.5	12.5	37.9	13.8	75.0	5.0	81.2	0.0
	Cont.	2.0 (0 5.0)	0								
	R PT.	10.3	10.3	23.0	8.0	10.0	7.3	11.1	0.0	20.0	0.0
	Cont.	2.0 (0 5.0)	0								

*Defined as eye movements initially made in the wrong direction irrespective of subsequent corrections.

†Numbers in parentheses are ranges of control subjects' errors.

amplification was sufficient to evaluate saccade amplitudes (sessions 1 and 3), he showed hypometric eye movements to the left. In session 1, the mean amplitude of his correct leftward saccades ($X=20.7^\circ$) was significantly smaller ($t=6.03$; $df=90$; $P<0.005$) than the mean amplitude of his rightward saccades ($X=27.7^\circ$), which was close to the eccentricity of the target (30°). A similar result was obtained in session 3 (mean amplitude of correct leftward saccades = 23.4° ; mean amplitude of correct rightward saccades = 28.7° ; $t=4.38$; $df=81$; $P<0.0005$). Furthermore, similar differences between leftward and rightward saccades were also found on both uncrossed and crossed-response trials in these sessions ($P<0.0005$ in all tests). However, when tested 6 months later (session 5), he no longer showed hypometric saccades to the left in the uncrossed or crossed-response series (overall mean amplitude of leftward saccades = 29.7° ; overall mean amplitude of rightward saccades = 29.4°). In addition, in sessions 1 and 3, his leftward eye movements contained many staircase saccades; in these sessions he performed staircase saccades to the left on 75% of the trials in which he correctly moved his eyes in that direction, whereas he performed staircase saccades to the right on 27.5% of the trials in which he correctly moved his eyes in that direction. However, 6 months later, he performed very few staircase saccades to the left (5%) and none to the right.

In order to determine whether the latencies of his eye movements (correct trials only) were affected by the conditions of testing, latencies recorded in sessions 2–4 were transformed to natural logs and analyzed by two, repeated-measure ANOVAS in which the scores obtained in these three sessions served as the repeated measure. In the first ANOVA, the factors were side of stimulus presentation (left vs right) and the required response (uncrossed vs crossed). The only significant source of variance was the uncrossed vs crossed response factor ($F=17.71$; $df=1/2$; $P<0.05$). This outcome is attributed to the considerably longer eye movement latencies in the crossed condition ($X=917$ msec) than in the uncrossed condition ($X=472$ msec). In the second ANOVA, which included the direction of response (left vs right), and the crossed vs uncrossed-response factor, again, only the latter factor was significant. Similar differences between eye movement latencies in the uncrossed- and crossed-response series were found in the testing session administered 6 months after the first four tests (correct eye movement in crossed-response test: $X=1373$ msec; correct eye movement in uncrossed-response test: $X=572$ msec).

Analyses of the control subjects EOG recordings disclosed that the mean latencies of their correct eye movements on uncrossed-response trials (overall $X=383$ msec; range = 304–507 msec) overlapped those of the patient ($X=472$ msec; $SD=238$ msec) in sessions 2–4. However, their average eye movement latencies on crossed-response trials (overall $X=492$ msec; range = 380–592 msec) were all considerably shorter than the patient's eye movement latencies on crossed-response trials in session 2–4 ($X=917$ msec; $SD=387$ msec).

Finally, transformed latencies of the patient's incorrect eye movements to the side opposite the lesion on crossed-response trials (i.e. release of visual grasp to the left), were compared to the transformed latencies of his eye movements when he correctly moved his eyes to the left in crossed and uncrossed-response trials in sessions 3 and 4. The latencies of his released eye movements to the left ($X=490$ msec) were significantly shorter ($t=4.01$; $df=61$; $P<0.01$) than were the latencies of his correct movements to the left in the crossed-response trials ($X=726$ msec). However, in the same sessions, the mean latency of his released eye movements to the left did not differ significantly from the latencies of his correct eye movements to the left in uncrossed-response trials ($X=470$ msec). Similar differences were

obtained when latencies of "released" and correct eye movements recorded in the 6 month follow-up test were analyzed (released eye movements to left: $X = 294$ msec; correct eye movements to left in uncrossed-response test: $X = 513$ msec; correct eye movements to left in crossed-response test: $X = 1429$ msec). In this session, the latencies of released eye movements to the left did not differ significantly from the latencies of correct eye movements to the left in the uncrossed-response test. However, the difference between latencies of released and correct eye movements to the left also failed to attain significance. Furthermore, the latencies of leftward eye movements in these three conditions did not differ significantly from those of leftward eye movements in three sessions.

DISCUSSION

As mentioned in the Introduction, studies of the effects of frontal lobe lesions have yielded apparently contradictory findings: some investigators have reported reduced responses to external stimuli, whereas others have reported enhanced responses to external stimuli. In the patient we tested, we found evidence of both reduced and enhanced eye movements at different times following a frontal lobe infarct. We will deal with the question of possible relationships between these opposed abnormalities later.

Considering first his reduced eye movements, the patient was impaired in moving his eyes toward visual stimuli presented on the side contralateral to his lesion, but showed little or no impairment in moving his eyes toward ipsilateral visual stimuli. This directionally-selective deficit was most pronounced in the first testing session and declined in subsequent sessions. The results obtained in the crossed-response tests suggest that this deficit involved two components—contralateral inattention and directional motor neglect, a reduced tendency to look to the left. As stated previously, sensory inattention in our testing situation can be evaluated independently of directional motor neglect by failure to move the eyes when a stimulus on the left requires an eye movement to the right. Furthermore, in order to assess the contralateral component of this inattention, the patient's tendency to neglect visual stimuli irrespective of their position should be taken into account. We assessed this tendency by the patient's failure to move his eyes when a stimulus on the right required an eye movement to it. Figure 2 shows the patient's contralateral sensory inattention, as defined above, minus this measure of his general neglect. Defined in this way his contralateral inattention declined over the first three testing sessions and was no longer present in the last two sessions. The validity of our measure of inattention is strengthened by the observation that in the first three testing sessions but not in the last two, the patient was deficient in reporting visual stimuli (the examiner's finger) presented on the left. Furthermore, in the last testing session, conducted 6 months later, in which he showed no sensory inattention to the left in testing, he consistently reported all visual stimuli presented on the left. However, it is possible that the measure of sensory inattention used here may in part reflect a deficit in visual-eye movement coordination.

It should be noted that in the first testing session (but not in later ones) the patient's deficit in moving his eyes toward leftward stimuli, which we assume reflects both sensory inattention and directional motor neglect, was less severe than his deficit in sensory attention, i.e. moving his eyes to the right when a stimulus was presented on the left in the crossed-response test. This finding suggests that in session 1 his deficit in moving his eyes to the right in response to a stimulus on the left was in part due to a disturbance in looking away from stimuli and/or fatigue, as well as to inattention to stimuli on the left.

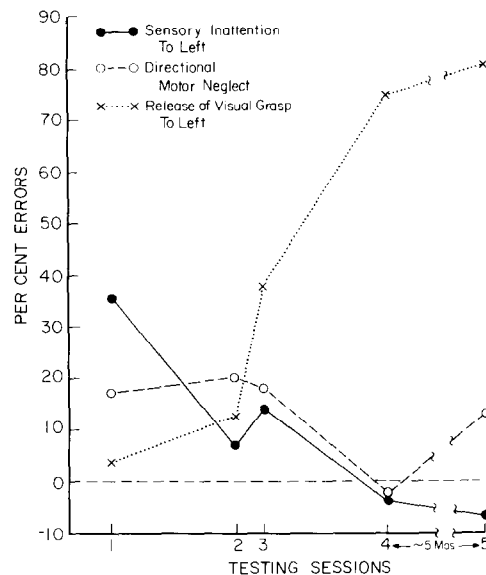


FIG. 2. Percent errors of the patient in the five testing sessions. Sensory inattention: percent trials with no eye movements when stimulus on left presented in crossed-response tests minus percent trials with no eye movements when stimulus on right presented in uncrossed-response tests. Directional (left) hypokinesia: percent trials in which patient failed to move eyes to left in crossed-response test minus percent trials in which patient failed to move eyes to right in uncrossed-response test. Release of visual grasp to left: percent trials in which patient moves eyes to target on left in crossed-response test.

In addition to his sensory inattention to the left, the patient's eye movements to the left were directionally hypokinetic (directional motor neglect) when evaluated in a testing situation in which stimuli were presented on the right side and thus were not affected by his leftward inattention. Figure 2 shows the patient's failure to move his eyes to the left in the crossed-response tests relative to his failure to move his eyes to the right in the uncrossed-response tests, which provides a measure of his non-directional hypokinesia. By this measure, his directional motor neglect, unlike his left-sided inattention, did not decline over the first three sessions. Although his directional motor neglect was not present in the fourth session, it reappeared in the last session. Thus, it appears that overall, his directional motor neglect was somewhat more severe than his contralateral sensory inattention. The finding that both a sensory attentional deficit and a directional motor neglect are present following a discrete lesion is consistent with the view that each structure in a distributed attentional system controls both sensory attention and movements directed to the same region of space [34]. However, this finding would not be predicted by the view that the frontal lobe controls only the motor component of attentional processes [32].

Of the three components of motor neglect that have been described previously—a reduced tendency to move, hypometria and increased latency to initiate movement [14, 19], the patient showed the first two, but not the third. His reduced tendency to move the eyes to the left is a finding that is consistent with previous observations of reduced limb movements in patients [1, 5, 31] and monkeys [37] with unilateral frontal lesions. This deficit was not due to a paralysis of gaze, for the patient was capable of making full-amplitude saccadic eye

movements to the left on command and occasionally (although rarely) performed them in the testing sessions in which he showed directional motor neglect.

In addition to his reduced tendency to look to the left, early in testing the patient also showed another manifestation of motor neglect—leftward hypometria—which has also been observed in the limb movements of a patient with a lesion confined to the right frontal lobe [31]. A related eye movement disorder shown by the patient reported here was an abnormally high incidence of staircase saccades to the side opposite his lesion, a finding that has also been reported in a series of patients with neglect following damage to the right hemisphere [12, 18]. These eye movement deficits, together with his reduced tendency to look to the left, may collectively reflect a decrease in the strength of a premotor process that normally activates voluntary, goal-directed movements to contralateral hemispace. The observation that the left hand and arm movements of the patient were also reduced suggests the frontal lesion he sustained also impaired other movements. However, it should be noted that the latencies of the patient's saccades directed to the side opposite to his lesion were not longer than the latencies of his saccades directed to the ipsilateral side. GUITTON *et al.* [13] also failed to find increased latencies of contralateral saccades following unilateral frontal surgery. Nor were the latencies of the patient's saccades in either direction on uncrossed trials longer than those of the control subjects, a finding also obtained by Guitton *et al.* In contrast, lesions involving the right parietal lobe have been reported to selectively increase the latencies of eye movements to contralateral targets [12, 35]. These findings suggest that the contribution of the parietal lobe to visually-directed saccades differs from that of the frontal lobe.

As the patient's sensory inattention declined, his tendency to inappropriately shift his gaze to a left-sided stimulus in the crossed-response test became more prominent and was still strong approximately 6 months following his stroke. This disinhibitory tendency was directional; his tendency to look inappropriately to right sided stimuli was much weaker, although it was probably somewhat abnormal, since the control subjects showed virtually no release of inappropriate eye movements in either direction. A similar release of inappropriate eye movements to visual stimuli in patients with unilateral frontal lobe lesions has been reported recently by GUITTON *et al.* [13]. The major difference between the results of that study and ours is that whereas the patients of Guitton *et al.* showed released saccades to stimuli both ipsilateral and contralateral to their lesions, our patient showed much stronger release of eye movements to contralateral than to ipsilateral stimuli. This discrepancy between the results of the two studies may be due to differences in pathology of the patients: the patients of Guitton *et al.* received surgery for the relief of intractable epilepsy and unlike our patient probably had long-standing pathology.

Furthermore, the finding that the latencies of the patient's saccades on crossed-response trials (but not those of his saccades on uncrossed-response trials) were much longer than those of the control subjects, together with his disinhibition of leftward gaze, suggests a deficiency in the process whereby cognitive sets controlling eye movements override the tendency to fixate visual stimuli. Loss of cognitive control and especially flexibility appears to be central to the behavioral abnormalities seen in patients following frontal lobe lesions. These patients are severely impaired when required to implement a plan, especially one that involves the inhibition of stereotyped or automatic responses. LURIA [30] observed that in these patients "... goal directed selective behavior was replaced by habitual stereotypes based on the direct action of a particular stimulus which the patient did not compare to the

original plan and did not inhibit" (p. 295), and that they would "... continue with their automatic action quite regardless of the instructions they have just received ..." (p. 297). These observations suggest that the frontal lobes are critical for selective, voluntary control over more automatic and reflex-like behaviors and therefore provide the organism with a degree of independence from the immediate demands of the environment. Although loss of cognitive control may have contributed to our patient's abnormal performance on crossed-response trials, it is important to point out again that this deficit was spatially selective, i.e. his inappropriate eye movements to the left were much more frequent than were his inappropriate movements to the right. It is possible that the release of eye movements shown by the patient reported here was due to the disinhibition of subcortical structures controlling fixation of visual stimuli. The most likely candidate for this role is the superior colliculus, which controls visually-elicited saccades (see review by WURTZ and ALBANO [39]. Furthermore, studies in both animals [24, 25] and humans [21], indicate that the prefrontal cortex, which projects to the superior colliculus both directly [27, 29] and indirectly via the caudate-nigral pathway [20], controls visually-guided saccades.

It may seem paradoxical that in the final session in which he was tested, the patient whose results we report here showed both an abnormally high frequency of inappropriate eye movements to the left and, to a lesser degree, a reduced tendency to look leftward, which we interpret as a directional motor neglect. However, these two alterations are not mutually contradictory. The former was found in a testing condition where a stimulus on the left is a signal to move the eyes to the right and is interpreted as a difficulty in overcoming the tendency to fixate visual stimuli. The latter was found in a testing condition where a stimulus on the right is a signal to move the eyes to the left and is interpreted as an impairment in performing a voluntary movement in a particular direction. Both alterations, then, may be regarded as impairments in voluntary control over eye movements. Rather than being mutually contradictory, they are consistent.

The finding that release of inappropriate eye movements to the left only appeared after the patient's sensory inattention declined is not surprising, for, by the way in which it was defined, the latter deficit is incompatible with the former. Sensory inattention may decline in time because the disturbed function is normally mediated by a distributed system involving a number of cortical and subcortical structures [19], which take time to function again after one component is damaged. It is possible that initially following a frontal lesion, sensory neglect is stronger than and thus masks the release of visually-guided saccades. Alternatively, release may appear later than the other symptoms because the lesion has two effects, which occur at different times (a) an initial diaschisis of the subcortical mechanism controlling the visually-guided saccades, and (b) later, when the diaschisis is no longer exerted, release of the same subcortical mechanism.

Finally, the sensory inattention and directional hypokinesia on the one hand and release of visual grasp on the other that the patient we studied showed may depend upon damage to independent or related mechanisms. By the former view, the frontal lobe provides separate, independent mechanisms for directing attention to and responding to stimuli and for modulating visually-guided saccades. According to this view, both of these mechanisms were impaired in the patient whom we tested. Whether this interpretation, or the alternative one which asserts that a single mechanism mediates all the disturbed functions, is correct remains to be determined by further observations of the behavioral effects of frontal lobe lesions more limited than that of the patient reported here.

Acknowledgements—This research was supported by a National Health Service Research Award (No. F33 NS07946) to Charles M. Butter, by the V.A.M.C. Research Service and by the Florida Memory Disorder Clinics.

REFERENCES

1. BISIACH, E., BERTI, A. and VALLAR, G. Analogical and logical disorders underlying unilateral neglect of space. In *Attention and Performance XI*, M. I. POSNER and O. S. M. MARIN (Editors), pp. 239–249. Lawrence Erlbaum, Hillsdale, New Jersey, 1985.
2. BRUCE, C. J. and GOLDBERG, M. E. Primate frontal eye fields: I. Single neurons discharging before saccades. *J. Neurophysiol.* **53**, 603–635, 1985.
3. BUTTER, C. M. Habituation of orienting responses to novel stimuli in monkeys with selective frontal lesions. *Science* **964**, 313–315, 1964.
4. CASTAIGNE, P., LAPLANE, D. and DEGOS, J.-D. Trois cas de négligence motrice par lésion retro-rolandique. *Revue Neurologique* **122**, 233–242, 1970.
5. CASTAIGNE, P., LAPLANE, D. and DEGOS, J.-D. Trois cas de négligence motrice par lésion frontale retro-rolandique. *Revue Neurologique* **126**, 5–15, 1972.
6. COSLETT, H. B., BOWERS, D. and HEILMAN, K. M. Reduction in cognitive activation following right hemisphere stroke. *Neurology* **34**, Suppl. 1, 190, 1984.
7. COSLETT, H. B. and HEILMAN, K. M. Hemihypokinesia following right hemisphere stroke. *Neurology* **34**, Suppl. 1, 190, 1984.
8. CROWNE, D. P., YEO, C. N. and RUSSELL, I. S. The effects of unilateral frontal eye field lesions in the monkey: visual motor guidance and avoidance behaviour. *Behav. Brain Res.* **2**, 165–187, 1981.
9. DAMASIO, A. R., DAMASIO, H. and CHUI, H. C. Neglect following damage to frontal lobe or basal ganglia. *Neuropsychologia* **18**, 123–132, 1980.
10. DERENZI, E. and FAGLIONI, P. The comparative efficiency of intelligence and vigilance test detecting hemispheric change. *Cortex* **1**, 410–433, 1965.
11. DEUEL, R. K. Loss of motor habits after nonsensorimotor lesions. *Neuropsychologia* **15**, 205–215, 1977.
12. GIROTTI, F., CASAZZA, M., MUSICCO, M. and AVANZINI, G. Oculomotor disorders in cortical lesions in man: the role of unilateral neglect. *Neuropsychologia* **21**, 543–553, 1983.
13. GUITTON, D., BUCHTEL, H. A. and DOUGLAS, R. M. Frontal lobe lesions in man cause difficulties in suppressing reflexive glances and in generating goal-directed saccades. *Exp. Brain Res.* **58**, 455–472, 1985.
14. HEILMAN, K. M., BOWERS, D., COSLETT, H. B., WHEN, H. and WATSON, R. T. Directional hypokinesia: prolonged reaction times for leftward movements in patients with right hemisphere lesions and neglect. *Neurology* **35**, 855–859, 1985.
15. HEILMAN, K. M., BOWERS, D. and WATSON, R. T. Performance on hemispacial pointing task by patients with neglect syndrome. *Neurology* **33**, 661–664, 1983.
16. HEILMAN, K. M. and VALENSTEIN, E. Frontal lobe neglect in man. *Neurology* **22**, 660–664, 1972.
17. HEILMAN, K. M. and VALENSTEIN, E. Mechanisms underlying hemispacial neglect. *Annals of Neurology* **5**, 166–170, 1979.
18. HEILMAN, K. M., WATSON, R. T. and VALENSTEIN, E. Unilateral gaze deficit associated with hemispacial neglect. *Neurology* **30**, 360, 1980.
19. HEILMAN, K. M., WATSON, R. T. and VALENSTEIN, E. Neglect and related disorders. In *Clinical Neuropsychology*, (2nd Edition), K. M. HEILMAN and E. VALENSTEIN (Editors). Oxford University Press, New York, 1985.
20. HIKOSAKA, O. and WURTZ, R. H. Visual and oculomotor functions of the monkey substantia nigra pars reticulata. III. Memory contingent visual and saccade responses. *J. Neurophysiol.* **49**, 1268–1284, 1983.
21. HOLMES, G. The cerebral integration of ocular movements. *Br. Med. J.* **2**, 107–112, 1938.
22. HOWES, D. and BOLLER, F. Evidence for focal impairment from lesions of the right hemisphere. *Brain* **98**, 317–332, 1975.
23. JONES, G. M. and DEJONG, J. D. Dynamic characteristics of saccadic eye movements in Parkinson's disease. *Exp. Neurol.* **31**, 17–31, 1971.
24. JEANNEROD, M. Role du cortex frontale dans la motricité oculaire. *Revue Otoneuro-Ophthalmologique* **44**, 187–203, 1972.
25. JEANNEROD, M., KIYONO, S. and MOURET, J. Effects des lésions frontales bilatérales sur le comportement oculomoteur chez le chat. *Vision Research* **8**, 575–582, 1968.
26. KENNARD, M. A. and ECTORS, L. Forced circling movements in monkeys following lesions of the frontal lobes. *J. Neurophysiol.* **1**, 45–54, 1938.
27. KUNZLE, H. and AKERT, K. Efferent connections of cortical area 8 (frontal eye fields) in *Macaca fascicularis*. A reinvestigation using the autoradiographic technique. *J. comp. Neurol.* **173**, 147–164, 1977.
28. LATTO, R. and COWEY, A. Visual field defects after frontal eye field lesions in monkey. *Brain Res.* **30**, 1–24, 1981.
29. LEICHNETZ, G. R. An anterogradely-labeled prefrontal cortico-oculomotor pathway in the monkey demonstrated with HRP gel and and TMB neurohistochemistry. *Brain Res.* **198**, 440–445, 1980.

30. LURIA, A. R. *Higher Cortical Functions in Man*. 2nd edition, New York, Basic Books, 1980.
31. MEADOR, K. J., WATSON, R. T., BOWERS, D. and HEILMAN, K. M. Hypometria with hemispatial and limb motor neglect. *Brain* **109**, 293–305, 1986.
32. MESULAM, M.-M. A cortical network for directed attention and unilateral neglect. *Neurology* **10**, 399–325, 1981.
33. RIZZOLATTI, G., MATELLI, M. and PAVESI, G. Deficits in attention and movement following the removal of postarcuate (area 6) and prearcuate (area 8) cortex in macaque monkeys. *Brain* **106**, 655–673, 1983.
34. RIZZOLATTI, G., GENTILUCCI, M. and MATELLI, M. Selective spatial attention: one center one circuit, or many circuits? In *Attention and Performance XI*, M. I. POSNER and O. S. M. MARIN (Editors), Lawrence Erlbaum, Hillsdale, N.J., 251–265, 1985.
35. SUNDQVIST, A. Saccadic reaction time in parietal-lobe dysfunction. *The Lancet* **1**, 870, 1979.
36. VALENSTEIN, E. and HEILMAN, K. M. Unilateral hypokinesia and motor extinction. *Neurology* **31**, 445–448, 1981.
37. WATSON, R. T., MILLER, B. D. and HEILMAN, K. M. Nonsensory neglect. *Annls Neurol.* **3**, 505–508, 1978.
38. WELCH, K. and STUTEVILLE, P. Experimental production of neglect in monkeys. *Brain* **81**, 341–347, 1958.
39. WURTZ, R. H. and ALBANO, J. E. Visuo-motor function of the primate superior colliculus. *A. Rev. Neurosci.* **39**, 766–772, 1976.