

# ChAdOx1 nCoV-19 vaccine-induced immune thrombotic thrombocytopenia and cerebral venous sinus thrombosis (CVST)

Preethi Suresh, William Petchey

Cardiology, West Suffolk  
Hospitals NHS Trust, Bury Saint  
Edmunds, UK

## Correspondence to

Dr Preethi Suresh;  
preethisuresh16@gmail.com

Accepted 29 May 2021

## SUMMARY

A 27-year-old fit and well man presented with intermittent headaches associated with eye floaters and vomiting. His symptoms started 48 hours after having the first dose of ChAdOx1 nCoV-19 vaccine (Vaxzevria, previously AstraZeneca COVID-19 vaccine; AstraZeneca) and bloods showed raised D-dimer, low platelets and fibrinogen. CT venogram demonstrated significant cerebral venous sinus thrombosis. He was immediately started on intravenous immunoglobulins and dabigatran after liaising with haematologist. The next day, he complained of worsening headache and new homonymous hemianopia. Repeat CT of the head showed an acute parenchymal bleed with subdural extension and was given idarucizumab and high-dose steroids. He had an emergency decompressive craniotomy and external ventricular drain as his intracranial pressures were difficult to control. Despite full medical and surgical management, his intracranial pressures continued to rise and his brain injury was felt to be too devastating and was deemed unsurvivable.

## BACKGROUND

COVID-19 is an ongoing global pandemic caused by SARS-CoV-2. COVID-19 vaccines were developed after being carefully evaluated in clinical trials, and play an important role in management of COVID-19. However, reports have emerged of a small number of vaccine recipients developing an unusual thrombocytopenia and thrombosis. Researchers have speculated an immune response that resembles a rare reaction to heparin for development of thrombocytopenia and thrombosis. This case reflects a very similar presentation of vaccine-induced immune thrombotic thrombocytopenia (VITT).

## CASE PRESENTATION

A 27-year-old fit and well man presented with intermittent headaches associated with eye floaters and vomiting. His symptoms started 48 hours after having the first dose of ChAdOx1 nCoV-19 vaccine. He tried simple analgesia with no benefit and his headache persisted for 10 days. No personal or family history of thromboembolic events. On arrival, he complained of mild headache with no neurological deficits and normal funduscopy. His bloods showed raised D-dimer, low platelets and fibrinogen (table 1). His CT of the head was normal and CT venogram confirmed significant cerebral venous sinus thrombosis (CVST), as shown in

figures 1 and 2. After liaising with haematology, he was started on dabigatran and intravenous immunoglobulins (IVIg) (1 g/kg). His platelets and clotting profile was regularly monitored and samples for platelet factor 4 (PF4) antibodies were sent off (subsequently positive). Fifteen hours after the first dose of dabigatran, he developed severe headache and vomiting. Neurological examination showed left-sided homonymous hemianopia. Repeat CT of the head revealed an acute 5.3 × 3.2 cm parenchymal haemorrhage in the right parietal lobe, as shown in figure 3. He was started on idarucizumab as advised by neurosurgeons. Haematology advised high-dose steroids with proton pump inhibitors (PPI) cover. He was continued on IVIg but his Glasgow Coma Scale (GCS) continued to drop and required intubation and emergency decompressive craniotomy. He required an external ventricular drain as his intracranial pressures were difficult to control. Despite full medical and surgical management, his intracranial pressures continued to rise and his brain injury was felt to be too devastating and was deemed unsurvivable. Eventually, his treatment was withdrawn and he passed away peacefully.

## TREATMENT

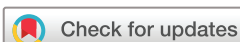1. IVIg (1 g/kg) OD (once a day) initiated immediately.
2. Anticoagulation with dabigatran after discussing bleeding risks.
3. Idarucizumab to reverse the action of dabigatran as the patient developed an intracranial bleed.
4. Prednisolone 80 mg OD (1 mg/kg) with PPI cover.

## OUTCOME AND FOLLOW-UP

Despite full medical and surgical management, the patient passed away.

## DISCUSSION

ChAdOx1 nCoV-19 is a recombinant adenovirus vector vaccine developed by Oxford University. It is marketed with a trade name Vaxzevria (previously AstraZeneca COVID-19 vaccine, AstraZeneca). Researchers have proposed a possible mechanism for development of thrombocytopenia and thrombosis after receiving ChAdOx1 nCoV-19 which suggests that it is an immune response that resembles a drug heparin which is an anticoagulant. Researchers have categorised this syndrome as VITT.<sup>1 2</sup> They have also suggested an association with PF4 antibodies and advised to have a



© BMJ Publishing Group Limited 2021. No commercial re-use. See rights and permissions. Published by BMJ.

**To cite:** Suresh P, Petchey W. *BMJ Case Rep* 2021;**14**:e243931. doi:10.1136/bcr-2021-243931

Table 1 Blood results

Bloods	9 April 2021	10 April 2021	11 April 2021
Haemoglobin (g/L)	155	151	138
White cell count ( $10^9/L$ )	12.0	9.5	12.7
Platelets ( $10^9/L$ )	90	68	73
D-dimer (ng/mL)	34071		
PT (s)	12.9	15.9	15.6
APTT (s)	27.5	28.2	26.4
Fibrinogen (g/L)	1.94	1.93	2.04
Sodium (mmol/L)	140	140	138
Potassium (mmol/L)	3.6	4.1	4.0
Urea (mmol/L)	5.0	3.2	5.2
Creatinine ( $\mu\text{mol/L}$ )	65	62	60
eGFR	>90	>90	>90
CRP (mg/L)	14		14
Bilirubin ( $\mu\text{mol/L}$ )	7		11
ALP (U/L)	87		71
PF4 antibodies	Positive: inhibitory (IgG) Optical density=3.125 (cut-off for positive reactions >0.400).		

9 April 2021 CT of the head: No acute intracranial abnormality.

10 April 2021 CT venogram (figures 1 and 2): There is significant under filling of the right transverse sinus with a filling defect, strongly suspicious of thrombus. The left transverse sinus is largely normally opacified, although a small focal filling defect is seen anteriorly, again raising the possibility of thrombus.

Normal opacification of the straight sinus. There is a small filling defect in the posterior aspect of the sagittal sinus. Appearances are in keeping with significant cerebral venous sinus thrombosis.

11 April 2021 CT of the head (figure 3): There is 5.3×3.2 cm acute parenchymal haemorrhage in the right parietal lobe with mild perifocal oedema. There is probable haemorrhagic subdural extension to the right tentorium.

There is mild dilatation of temporal horn of the right lateral ventricle. No other significant intracranial abnormality.

ALP, alkaline phosphatase; APTT, activated partial thromboplastin time; CRP, C-reactive protein; eGFR, estimated glomerular filtration rate; PF4, platelets factor 4; PT, prothrombin time.

low threshold for ELISA testing for PF-4 heparin antibodies in patients with suspected VITT.<sup>1,2</sup> Although there is an association with VITT and PF-4 antibodies, we need further studies to assess whether these antibodies are induced by vaccine cross-reacting with PF4 and platelets or strong inflammatory stimulus of the vaccine itself.

UK's expert Haematology Panel has published guidelines for diagnosis and management for VITT. They have advised anticoagulating with non-heparin-based therapies and urgent use of IVIg (1g/kg). They also advised to consider steroids if there is a delay in initiating IVIg and correct fibrinogen level

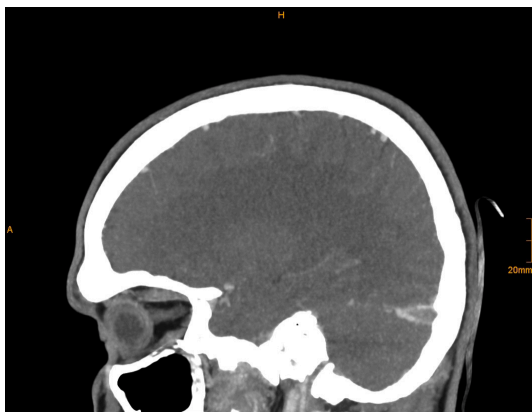


Figure 1 CT venogram showing significant cerebral venous sinus thrombosis.

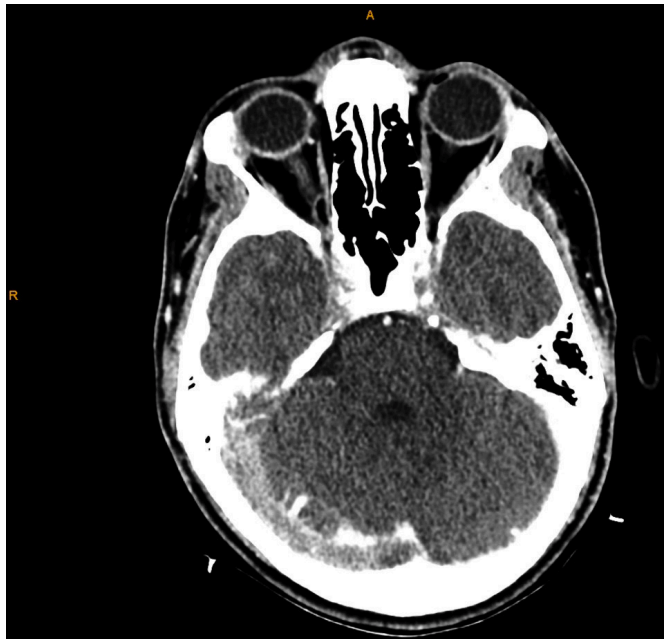


Figure 2 CT venogram showing significant under filling of the right transverse sinus with a filling defect, strongly suspicious of thrombus.

with fibrinogen concentrate or cryoprecipitate if it drops to less than 1.5 g/L.<sup>3</sup> It is mandatory for all the cases of thrombosis and thrombocytopenia post vaccination to be reported to the Medicines and Healthcare products Regulatory Agency (MHRA) through online yellow card reporting.<sup>4</sup>

We treated our patient as advised by the haematology team and was started on IVIg and non-heparin-based anticoagulation but unfortunately patient developed a life-threatening bleed which required urgent surgical intervention.

The MHRA has advised to seek prompt medical advice if the patient develops the following symptoms after vaccination:

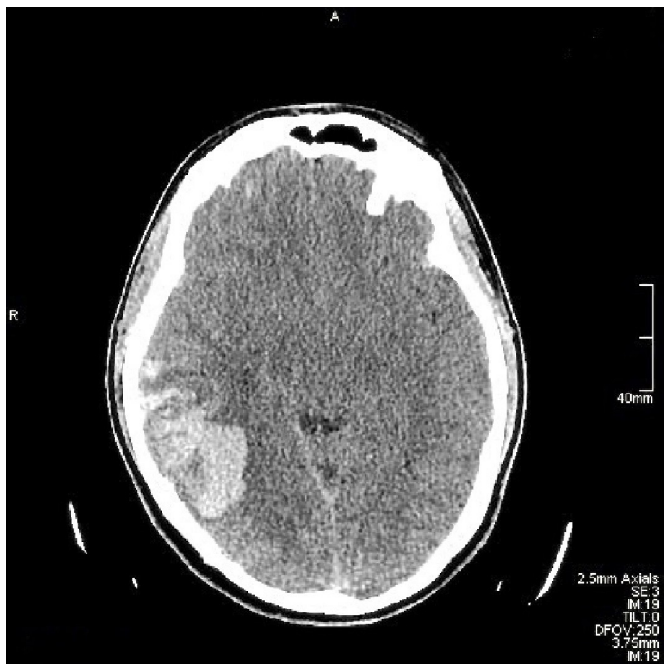


Figure 3 CT of the head showing a 5.3×3.2 cm acute parenchymal haemorrhage in the right parietal lobe with mild perifocal oedema.

blurred vision, persistent headache, seizures, unexplained pinprick rash, persistent abdominal pain, and shortness of breath, leg swelling, confusion or bruising beyond injection site.

The European Medicines Agency (EMA) reviewed 62 cases of CVST and 24 cases of splanchnic vein thrombosis, 18 of which were fatal and advised that 'benefits outweigh any risks of side effects' in relation to the vaccine. There has not been any direct link between vaccination and thrombocytopenia but only a possible hypothesis of a condition similar to heparin-induced thrombocytopenia. It is still vitally important that people come forward for their vaccination when invited to do so.<sup>5</sup>

### Learning points

- ▶ If a patient presents with headache 5–28 days post ChAdOx1 nCoV-19 vaccine, kindly investigate for D-dimer, platelets and fibrinogen.
- ▶ If no clinical and haematological features for ChAdOx1 nCoV-19 vaccine-induced immune thrombocytopenia (VITT), headache should be managed via usual headache guidelines with neuroimaging only if clinically appropriate.
- ▶ For patient with VITT and headache symptoms, dedicated cerebral venous imaging is appropriate. Non-contrast CT of the brain combined with contrast-enhanced CT cerebral venography has a very high diagnostic accuracy.
- ▶ If there is a suspicion/confirmed VITT, kindly liaise with the haematology team immediately and request ELISA testing for platelets factor 4-heparin antibodies.

**Acknowledgements** We would like to thank Dr Rachel Darrah (Consultant Radiologist) for her input on CT images.

**Contributors** PS is the first author of this case report. PS identified and managed the case. Case report approved by WP.

**Funding** The authors have not declared a specific grant for this research from any funding agency in the public, commercial or not-for-profit sectors.

**Competing interests** None declared.

**Patient consent for publication** Obtained.

**Provenance and peer review** Not commissioned; externally peer reviewed.

This article is made freely available for use in accordance with BMJ's website terms and conditions for the duration of the covid-19 pandemic or until otherwise determined by BMJ. You may use, download and print the article for any lawful, non-commercial purpose (including text and data mining) provided that all copyright notices and trade marks are retained.

### REFERENCES

- 1 Greinacher A, Thiele T, Warkentin TE, *et al*. Thrombotic thrombocytopenia after ChAdOx1 nCoV-19 vaccination. *N Engl J Med* 2021. doi:10.1056/NEJMoa2104840. [Epub ahead of print: 09 Apr 2021].
- 2 Schultz NH, Sørvoll IH, Michelsen AE, *et al*. Thrombosis and thrombocytopenia after ChAdOx1 nCoV-19 vaccination. *N Engl J Med* 2021. doi:10.1056/NEJMoa2104882. [Epub ahead of print: 09 Apr 2021].
- 3 Guidance produced from the expert haematology panel focused on covid-19 vaccine induced thrombosis and thrombocytopenia. Available: [https://b-s-h.org.uk/media/19530/guidance-version-13-on-mngmt-of-thrombosis-with-thrombocytopenia-occurring-after-c-19-vaccine\\_20210407.pdf](https://b-s-h.org.uk/media/19530/guidance-version-13-on-mngmt-of-thrombosis-with-thrombocytopenia-occurring-after-c-19-vaccine_20210407.pdf) [Accessed 7 Apr 2021].
- 4 Medicines & Healthcare products Regulatory Agency. MHRA (2006) healthcare professional reporting of suspected adverse drug reactions. Available: <http://www.mhra.gov.uk>
- 5 Mahase E. AstraZeneca vaccine: Blood clots are "extremely rare" and benefits outweigh risks, regulators conclude. *BMJ* 2021;373. doi:10.1136/bmj.n931

Copyright 2021 BMJ Publishing Group. All rights reserved. For permission to reuse any of this content visit <https://www.bmj.com/company/products-services/rights-and-licensing/permissions/>  
BMJ Case Report Fellows may re-use this article for personal use and teaching without any further permission.

Become a Fellow of BMJ Case Reports today and you can:

- ▶ Submit as many cases as you like
- ▶ Enjoy fast sympathetic peer review and rapid publication of accepted articles
- ▶ Access all the published articles
- ▶ Re-use any of the published material for personal use and teaching without further permission

### Customer Service

If you have any further queries about your subscription, please contact our customer services team on +44 (0) 207111 1105 or via email at [support@bmj.com](mailto:support@bmj.com).

Visit [casereports.bmj.com](http://casereports.bmj.com) for more articles like this and to become a Fellow