

# Neurocysticercosis and Pure Motor Hemiparesis

Fernando Barinagarrementeria, MD, and Oscar H. Del Brutto, MD

**A 49-year-old man with meningeal cysticercosis presented with a pure motor hemiparesis. Computed tomography and magnetic resonance imaging showed a capsular infarction and a suprasellar cyst with surrounding arachnoiditis. Cerebrospinal fluid analysis confirmed the diagnosis as it showed positive immunologic reactions to cysticerci. This is the first reported case of pure motor hemiparesis due to a parasitic disease of the central nervous system. (*Stroke* 1988;19:1156–1158)**

**P**ure motor hemiparesis (PMH) is one of the most common lacunar syndromes,<sup>1</sup> accounting for up to 60% of lacunar strokes.<sup>2</sup> It is usually caused by a small infarction in the internal capsule,<sup>3</sup> basis pontis,<sup>3,4</sup> cerebral peduncle,<sup>5</sup> or medullary pyramid.<sup>6</sup> In addition, several causes of PMH other than lacunar infarction have been reported. Among these are intracerebral hemorrhage,<sup>7</sup> brainstem glioma,<sup>8</sup> metastatic tumor,<sup>9</sup> subdural hematoma,<sup>9</sup> multiple sclerosis,<sup>9</sup> nocardial abscess,<sup>10</sup> and meningovascular syphilis.<sup>11</sup> Parasitic diseases of the central nervous system could also cause PMH, but they have not been described in this setting. We report a patient with cysticercosis and PMH.

## Case Report

A 49-year-old right-handed man with a history of taeniasis was evaluated 1 week after the acute onset of right motor deficit and an inability to speak. On admission, his blood pressure was 110/70 mm Hg and his general physical examination was normal. Neurologic examination showed an alert patient with motor dysphasia. Cranial nerve functions including pupillary responses, ocular movements, and facial sensation were normal. There was a right hemiparesis with crural dominance. Muscle stretch reflexes were ++ throughout, and the rest of the findings, including those from the sensory evaluation, were unremarkable. Computed tomography (CT) showed a cystic suprasellar lesion and a small area of decreased attenuation in the posterior limb of the left internal capsule (Figure 1). Magnetic resonance imaging (MRI) confirmed the left capsular infarction as well as the

suprasellar cyst and revealed heterogeneous changes in the signal intensity of the suprasellar cistern, consistent with arachnoiditis (Figure 2). Extracranial Doppler ultrasonography did not detect lesions in the neck vessels. Lumbar puncture yielded a clear cerebrospinal fluid (CSF) under normal pressure with 187 mononuclear cells/mm<sup>3</sup>, 9 mg proteins/dl, and 50 mg glucose/dl; immunologic reactions to cysticerci (enzyme-linked immunosorbent assay and complement fixation test) were positive. The patient spontaneously improved, and a repeat neurologic examination 2 months after the event revealed minimal right leg paresis.

## Discussion

PMH is a heterogeneous syndrome caused by a variety of pathologic processes affecting the pyramidal motor pathway at both the supratentorial and infratentorial levels.<sup>1–11</sup> While in some cases PMH has been the result of a space-occupying mass,<sup>7–10</sup> in most patients PMH is caused by a small infarction due to the occlusion of a terminal vessel.<sup>1–6</sup> Such occlusion may be secondary to atherosclerosis<sup>3</sup> or chronic meningitis, inducing inflammatory arteriopathies.<sup>11</sup>

Meningeal cysticercosis is a well-recognized cause of ischemic cerebrovascular disease.<sup>12</sup> In these cases, abnormal thickening of leptomeninges at the base of the skull accounts for inflammatory changes in the wall of blood vessels around the circle of Willis. Those vessels show thickening of the adventitia with fibrosis of the media and endothelial hyperplasia<sup>13</sup>; in some instances this process of endarteritis leads to complete occlusion of a blood vessel, with subsequent brain infarction.<sup>13–15</sup>

In our patient the diagnosis of cysticercosis was made on the basis of CT findings and positive immunologic reactions in the CSF.<sup>16,17</sup> In addition, MRI provided direct evidence of arachnoiditis in the suprasellar cistern, which could account for the

From the Division de Neurologia, Instituto Nacional de Neurologia y Neurocirugia, Mexico City, Mexico.

Address for correspondence: Fernando Barinagarrementeria, MD, Instituto Nacional de Neurologia y Neurocirugia, Insurgentes Sur 3877, 14410, Mexico 22, DF, Mexico.

Received February 22, 1988; accepted March 31, 1988.

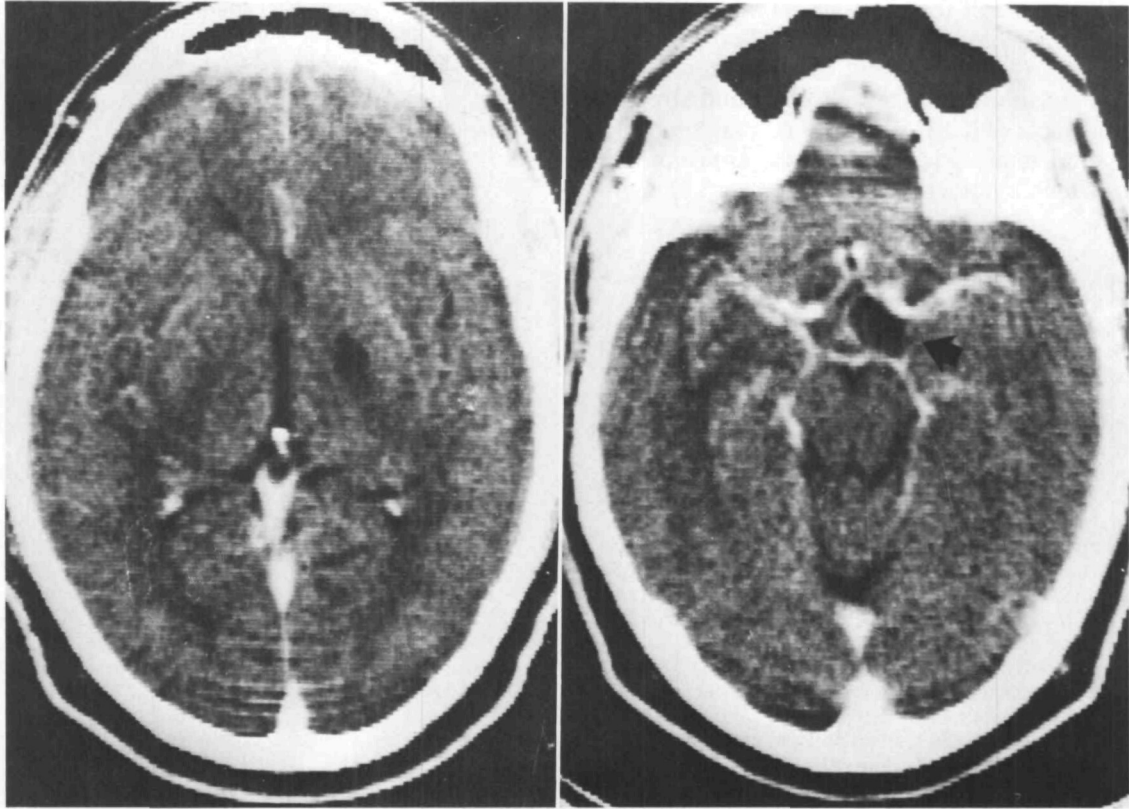


FIGURE 1. Contrast-enhanced computed tomogram showing (left) small infarction in posterior limb of left internal capsule and (right) cystic suprasellar lesion consistent with cysticercus (arrow).

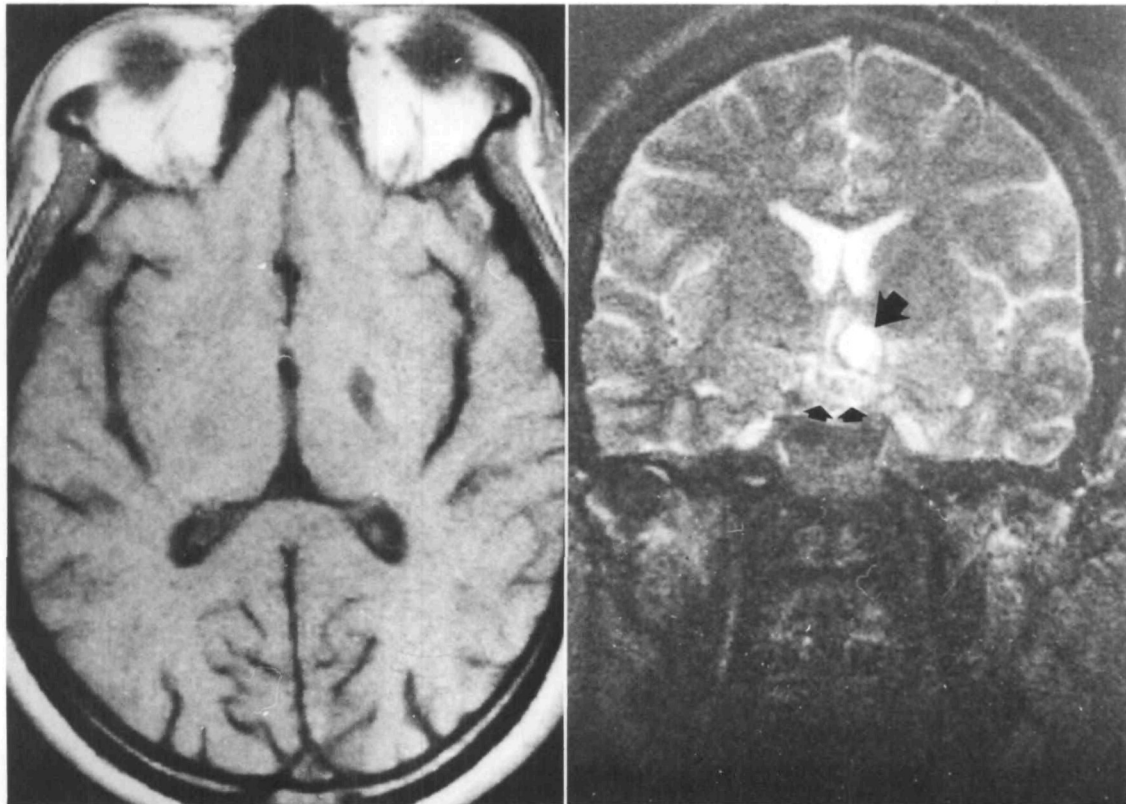


FIGURE 2. Left: T1-weighted (echo time 520 msec, repetition time 21 msec) magnetic resonance image showing left capsular infarction. Right: T2-weighted (echo time 2000 msec, repetition time 50 msec) magnetic resonance image showing suprasellar cysticercus (large arrow) with surrounding arachnoiditis (small arrows).

occlusion of a small terminal vessel supplying the left internal capsule. This case, together with previous reports,<sup>12,14,15</sup> points out that cysticercosis is a possible cause of cerebral infarction and stresses the importance of CSF analysis in patients with lacunar syndromes who come from areas of the world in which cysticercosis is endemic.<sup>18-20</sup>

### References

1. Fisher CM: Lacunar strokes and infarcts: A review. *Neurology* 1982;32:871-876
2. Mohr JP: Lacunes, in Barnett HJM (ed): *Stroke: Pathophysiology, Diagnosis, and Management*. New York, Churchill Livingstone, 1986, vol 1, pp 475-496
3. Fisher CM, Curry HB: Pure motor hemiplegia of vascular origin. *Arch Neurol* 1965;13:30-44
4. Stiller J, Shanzer S, Yang W: Brainstem lesions with pure motor hemiparesis. *Arch Neurol* 1982;39:660-661
5. Ho KL: Pure motor hemiplegia due to infarction of the cerebral peduncle. *Arch Neurol* 1982;39:524-526
6. Ropper AH, Fisher CM, Kleinman GM: Pyramidal infarction in the medulla: A cause of pure motor hemiplegia sparing the face. *Neurology* 1979;29:91-95
7. Mori E, Tabuchi M, Yamadori A: Lacunar syndrome due to intracerebral hemorrhage. *Stroke* 1985;16:454-459
8. Levitt LP, Selkoe DJ, Frankenfield B, Schoene W: Pure motor hemiplegia secondary to brain-stem tumour. *J Neurol Neurosurg Psychiatry* 1975;38:1240-1243
9. Weisberg LA: Computed tomography and pure motor hemiparesis. *Neurology* 1979;29:490-495
10. Weintraub MI, Glaser GH: Nocardial brain abscess and pure motor hemiplegia. *NY State J Med* 1970;70:2717-2721
11. Johns DR, Tierney M, Parker SW: Pure motor hemiplegia due to meningovascular neurosyphilis. *Arch Neurol* 1987;44:1062-1065
12. Sotelo J, Guerrero V, Rubio F: Neurocysticercosis: A new classification based on active and inactive forms. *Arch Intern Med* 1985;145:442-445
13. Escobar A: The pathology of neurocysticercosis, in Palacios E, Rodriguez-Carbajal J, Taveras JM (eds): *Cysticercosis of the Central Nervous System*. Springfield, Ill, Charles C Thomas, 1983, pp 27-54
14. McCormick GF, Giannotta S, Zee CS, Fisher M: Carotid occlusion in cysticercosis. *Neurology* 1983;33:1078-1080
15. Barinagarrementeria F, Del Brutto OH, Otero E: Ataxic hemiparesis from cysticercosis. *Arch Neurol* 1988;45:246
16. Rodriguez-Carbajal J, Palacios E, Zee CS: Neuroradiology of cysticercosis of the central nervous system, in Palacios E, Rodriguez-Carbajal J, Taveras JM (eds): *Cysticercosis of the Central Nervous System*. Springfield, Ill, Charles C Thomas, 1983, pp 101-143
17. Rosas N, Sotelo J, Nieto D: ELISA in the diagnosis of neurocysticercosis. *Arch Neurol* 1986;43:353-356
18. Richards FO, Schantz PM, Ruiz-Tiben E, Sorvillo FJ: Cysticercosis in Los Angeles County. *JAMA* 1986;254:3444-3448
19. McCormick GF, Zee CS, Heiden J: Cysticercosis cerebri: Review of 127 cases. *Arch Neurol* 1982;39:534-539
20. Sotelo J, Del Brutto OH: Neurocysticercosis, in Román GC (ed): *Tropical Neurology: An Overview*. Boca Raton, Fla, CRC Press (in press)

KEY WORDS • cerebral infarction • cysticercosis • hemiplegia