

## PHONAGNOSIA: A DISSOCIATION BETWEEN FAMILIAR AND UNFAMILIAR VOICES

Diana Roupas Van Lancker<sup>1</sup>, Jeffrey L. Cummings<sup>2</sup>, Jody Kreiman<sup>3</sup> and Bruce H. Dobkin<sup>4</sup>

(<sup>1</sup>Neuropsychology Program, Neuropsychiatric Institute, the Department of Psychiatry and Biobehavioral Sciences, and <sup>1,3</sup>The Department of Linguistics, University of California at Los Angeles; <sup>2,4</sup>The Neurobehavioral Unit, West Los Angeles VAMC Neurology, School of Medicine; <sup>4</sup>University of California, Los Angeles, California, and Daniel Freeman Hospital, Inglewood, CA)

In prosopagnosia, patients lose the ability to recognize familiar faces such as those of close friends, family members, and famous personalities (Meadows, 1974), whereas their ability to discriminate between two unfamiliar faces may remain unimpaired (Benton, 1980; Benton and Van Allen, 1968; malone, Morris, Kay and Levin, 1982; Warrington and James, 1967). No similar dissociation between familiar and unfamiliar sensory stimuli in the auditory modality has been reported. A selective deficit in recognition of familiar voices might well go undetected because, in person, the face is available for recognition and, on the telephone, other identification strategies may be employed (Schegloff, 1979). Disturbances in recognition of non-voice auditory patterns have previously been described, including deficits of recognition and discrimination of environmental sounds (Spinnler and Vignolo, 1966; Vignolo, 1969; Barbizet, Duizabo, Enos and Fuchs, 1969; Faglioni, Spinnler and Vignolo, 1969), animal cries (Assal and Aubert, 1979) and music (Kimura, 1964; Milner, 1962). It seems likely that voice perception, with its potential parallel to face recognition and discrimination, might also fall victim to selective impairment in brain damage.

The speech signal carries information about personal identity along with the linguistic content of the utterance. Although processing of speech and language information has long been associated with left specialization in most right-handed people, a recent study found that a deficit in familiar voice recognition was significantly correlated with right, but not with left hemisphere lesions (Van Lancker and Canter, 1982). The only other study of voice perception abilities in brain-injured patients found a nonsignificant trend for right-brain damaged (RBD) subjects to be more impaired than left-brain damaged (LBD) patients in a task involving unfamiliar voice discrimination (Assal, Zander, Kremin and Buttet, 1976). Several questions are raised by these findings. If voice discrimination abilities were impaired, would recognition necessarily also be deficient? Are these aspects of voice perception mediated differently by the two hemisphere? What anatomic regions serve to mediate these capacities?

We report five patients who showed large discrepancies between familiar

voice recognition and unfamiliar voice discrimination, and a sixth who has abnormalities on both tasks. Tentative anatomic correlates of these deficits are presented.

## CASE REPORTS

### *Case 1*

This 61-years-old black male was brought to the emergency room in a confused state with a fluent aphasia. Computerized tomography (CT) of the head revealed hemorrhagic areas in both temporal lobes. The right-sided hemorrhage was surgically evacuated and gradual improvement ensued. The patient had 17 years of formal education and had worked as an engineer, psychologist, and draftsman, and had published several poems. He had a history of excessive use of alcohol but had been abstinent for 7 years prior to his cerebral insult. The patient had been hypertensive for several years and was treated with propranolol hydrochloride (40 mg/d) and clonidine hydrochloride (0.2 mg/d).

The patient was referred for evaluation of his language deficit 7 months after its onset. At that time, he exhibited a fluent paraphasic verbal output with a predominance of phonemic paraphasias. He was able to comprehend yes/no questions, point sequentially to 3 objects in the room, and decipher complex sentences. Repetition was impaired; he could repeat no more than 2 multisyllabic words at a time. Naming was intact for all but a few low-frequency words, and he was able to generate a word list of 12 animals in one minute. He was able to read aloud and with comprehension, and his writing contained errors similar to those exhibited in his spontaneous speech. The aphasic syndrome was characteristic of that of conduction aphasia and his profile on the Boston Diagnostic Aphasia Examination (Goodglass and Kaplan, 1972) was consistent with that diagnosis.

Other aspects of this patient's mental status examination were intact. He was alert and fully oriented. Recent and remote memory were unimpaired, and he was able to perform complex mathematical operations and abstract difficulty proverbs. He could copy complex figures including 3-dimensional representations and the Rey-Osterrieth figure. He could distinguish right from left and had no finger agnosia. There was a tendency to substitute a body part for an imagined object (comb, toothbrush) when limb praxis was assessed. He was fully aware of his language deficit and was frustrated by his errors. His mood was moderately elevated, and he was demanding and easily irritated.

The patient exhibited a mild dysarthria with imprecise articulation and a "breathy" voice quality. A mild right-sided hemiparesis (4/5 strength) was also present. Tone in the right upper and lower extremity was increased, and he tended to extinguish right-sided tactile stimuli during double simultaneous stimulation. Muscle stretch reflexes were more brisk on the right than the left, and a right-sided Babinski sign was present.

A CT scan (Figure 1) obtained at the time of the examination revealed a lucency in the anterior and middle portion of the right temporal lobe and lucencies in the mid- and posterior temporal and temporo-parietal junction regions of the left hemisphere.

### *Case 2*

The patient, a 52-year-old-right-handed white man, suffered the acute onset of speechlessness and right hemiplegia. He soon recovered the ability to make sounds but was unable to comprehend or speak normally. The patient had several seizures immediately

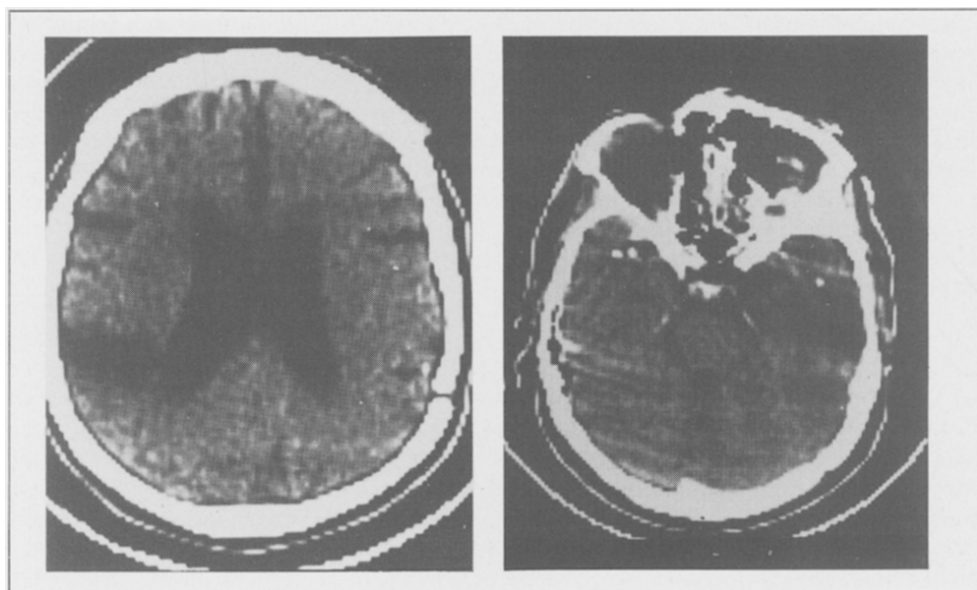


Fig. 1 — CT scans of Case 1 reveal a right-sided temporal lesion (left image) and left-sided temporo-parietal lesion (right image).

after the cerebral insult and was treated with phenobarbital, atenodol, dipyridamole, and aspirin. He had a long history of poorly controlled hypertension and had an episode of amaurosis fugax and a left carotid endarterectomy 2 years after his stroke.

He was referred for evaluation 4 years after his initial cerebrovascular accident. At that time he manifested a severe global aphasia with sparse output, frequent use of expletives, impaired comprehension, poor repetition, and anomia. He was unable to read aloud or

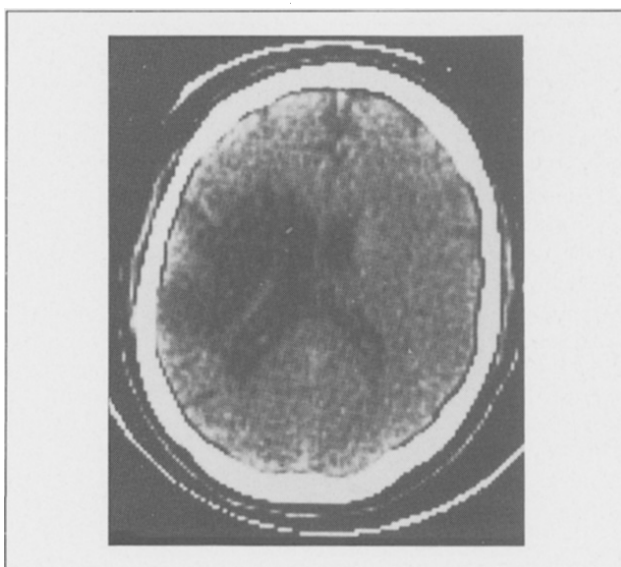


Fig. 2 — CT scan of Case 2 shows bilateral parietal lesions.

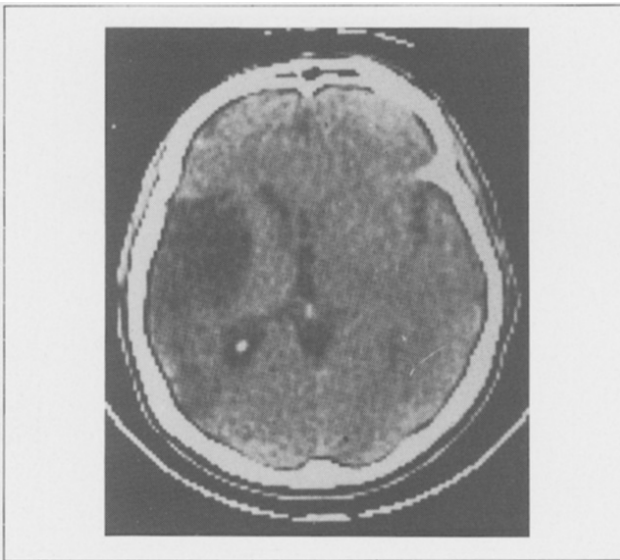
with comprehension and could write only a few words. Automatic speech (counting, reciting the alphabet) was partially preserved and he could sing with a recognizable melody. Nonlinguistic functions were preserved to the extent that his aphasia allowed them to be tested. He was able to reproduce complex constructions and demonstrated intact memory functions for everyday activities. He had a severe right hemiplegia, right homonymous hemianopia, and right hemisensory deficit.

CT scan obtained at the time of evaluation demonstrated an infarction in the territory of the left-middle cerebral artery, including lateral frontal, temporal, and parietal lobes (Figure 2). An electroencephalogram (EEG) had 1-3 Hz low voltage slow waves in the left frontotemporal regions.

### *Case 3*

This patient, a healthy, 54-year-old white man with 5 years' college education, had a successful business career and an active life as tennis player and yachtsman until suffering a stroke manifested by left-frontal headache, right-sided weakness and aphasia. Two months after the insult he exhibited severe nonfluent aphasia with moderately to severely impaired auditory comprehension, reading comprehension, and writing skills. He had a right hemiparesis with greater involvement of arm than leg, right facial weakness, right homonymous hemianopia, and a right hemisensory syndrome with diminished sensitivity to light touch and pin prick. Ultrasound images of the carotids showed no stenosis or occlusion. Three years after the stroke, he began to have simple partial seizures, secondarily generalized, with 1-2 minute auras, loss of consciousness, and incontinence. Post-ictal headaches were reported. He was given dipyridamole, phenytoin (serum level 8.4 mcg/ml) and phenobarbital (serum level 20.3 mcg/ml).

His spontaneous speech consisted almost entirely of "no", occasional expletives and 1 two-syllable recurrent utterance produced fluently and with normal inflection. Efforts to teach him to articulate useful phrases, such as "good-bye", were not successful despite his high motivation and cooperation. Speech comprehension improved considerably since the



*Fig. 3 — CT scan of Case 3 demonstrates a large left temporal lucency.*

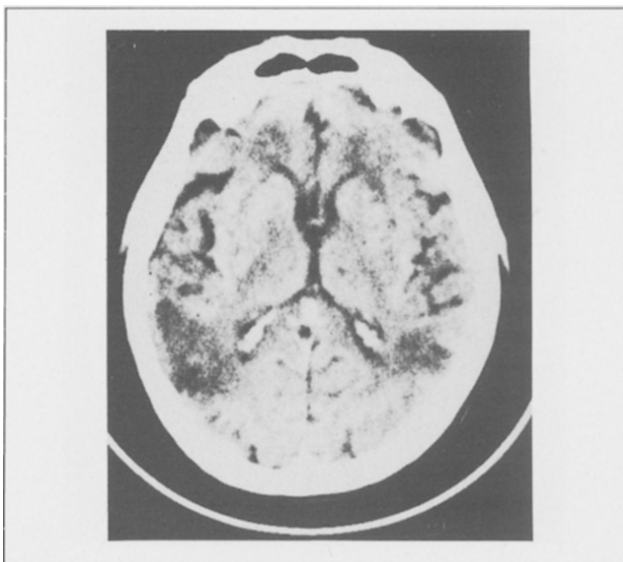
original insult. The first Porch Index of Communicative Ability (PICA) given 6 months after aphasia onset yielded an overall score of 7.72, on a 15 point scale. When administered for the fifth time 33 months post onset, he obtained an overall score of 10.53, placing him in the 45%ile of individuals with left hemisphere involvement. Verbal output remained the most severely deficient, with only 10% accuracy in naming, and a total inability to complete sentences or to imitate the examiner. Gestural abilities were mildly impaired, with good ability to demonstrate the requested function. Writing was markedly impaired. The patient was able to read simple printed material in terms of objects function with 100% accuracy, but he was unable to understand written prepositions.

At the time of study years after the CVA, the patient continued to exhibit severely impaired verbal output. Some individual phoneme sequencing in single word responses occurred, and performance in writing single words has improved. He continues to have a right hemiparesis, right hemisensory impairment, and right superior quadrantanopia. A pure tone audiogram demonstrated normal hearing to 4000 Hz with a 10 dB loss at 4000 Hz and a 60 dB loss at 6000 Hz.

Repeat CT scan in July, 1985, demonstrated a left hemisphere lesion involving the entire temporal lobe including the insula and posterior inferior region of the frontal lobe (Figure 3).

#### *Case 4*

This 74-year-old, white man, educated to the 10th grade, presented with an acute onset of language difficulty, diagnosed as moderate Wernicke's aphasia. Medical history was notable for atrial fibrillation, congestive heart failure, hypertension, chronic obstructive pulmonary disease, and peptic ulcer. A language evaluation completed one month after the insult noted clear articulation and fluent, generally intelligible speech with occasional neologisms and paraphasias, naming difficulty, and poor repetition of phrases and sentences. His comprehension was limited to single words. Gesture and two-dimensional



*Fig. 4 — CT scan of Case 4 shows bilateral parietal lesions.*

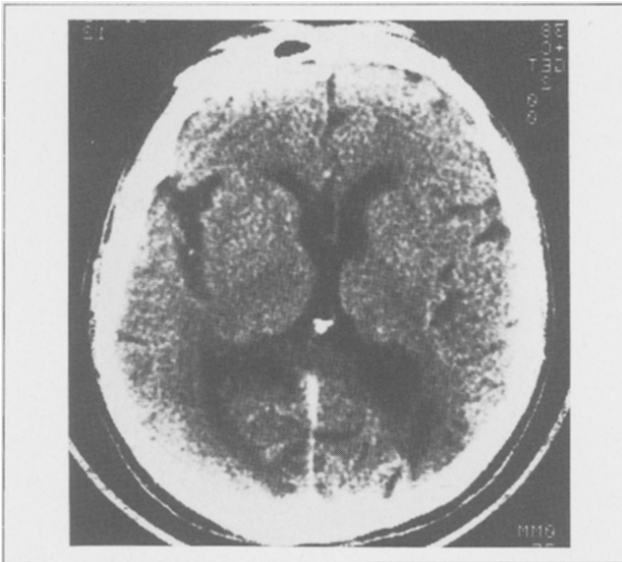drawings were not abnormal but more complex drawings were incomplete. Voice perception testing was completed within a year following the onset.

CT (Figure 4) revealed a lesion of the superior portion of the angular gyrus and the posterior portion of the supramarginal gyrus of the inferior parietal lobe of the left hemisphere. There was also a smaller lesion in the inferior parietal region of the right hemisphere. No clinical findings had been associated with the right hemisphere lesion which was viewed as clinically "silent" until the perception voice protocol were administered.

### *Case 5*

The patient, an 82-year-old, white man, experienced a sudden onset of confusion and headache. He was admitted to the hospital where he was noted to be alert and attentive, but unconcerned about his deficits. He had a fluent verbal output with intact comprehension and repetition. He was anomie in confrontation naming and could generate the names of only 5 animals in 1 minute. He could read single letters but no words or sentences. He wrote without difficulty. His anomia and alexia without agraphia were accompanied by a deficit in copying constructional models, abnormal limb praxis, and difficulty performing complex calculations. Abstraction, right-left orientation, and finger recognition were intact. Basic neurologic examination revealed a right homonymous hemianopia, right-sided hemiparesis, and right-sided hyper-reflexia. Voice perception testing was conducted 2 weeks following the cerebral insult.

CT scan (Figure 5) revealed an extensive lucent region in the territory of the left posterior cerebral artery, involving the medial occipital and lateral temporo-parieto-occipital junction regions. In addition, a smaller lucency was visible in the right parietal region.



*Fig. 5 — CT scan of Case 5 shows lesions in the right parietal and the left occipital areas.*

## Case 6

This patient was a healthy, well developed 68-year-old retired aerospace executive with 7 years of college education, and no history of any prior transient neurologic dysfunction or amaurosis, who experienced a sudden onset of left-sided weakness. Past medical history was pertinent for coronary artery bypass surgery 7 years previously and atrial fibrillation since. He had been on digoxin and 4 aspirin tablets daily and used nitroglycerin for rare episodes of chest pain. On the day of hospital admission, he had awakened, tried to walk, and fallen to the ground, noting weakness on his left side. On examination, he had a left hemiparesis, left hemianopia, and left hemi-inattention syndrome. Facial sensation was diminished on the left, and he extinguished the left-sided stimulus during double simultaneous stimulation. There was marked left facial paresis, the tongue protruded to the left, and the palate did not rise well on the left. Motor examination revealed mild increase in tone in the left upper extremity and slightly hyperactive left-sided muscle stretch reflexes. He was well-oriented with excellent immediate, recent, and past memory and no aphasia.

During the following weeks of rehabilitation, he had left neglect, emotional lability, impulsivity, swallowing difficulty, slight dressing disturbance, and inattention to his left side. He regained the ability to walk with a cane. No language deficit was observed, and he was able to read to the right of midline with little problem, but often missed written material presented on the left side of the paper and needed intermittent reminders to maintain eye contact during conversation. He was tested for voice perception abilities 9 months following onset of the illness.

CT scan (Figure 6) showed a well demarcated area of low attenuation in the right temporoparietal region corresponding to the distribution of the right middle cerebral artery and compatible with an area of infarction. The lesion included almost complete destruction of Heschl's gyrus and the posterior 2/3 of the superior temporal gyrus surface,

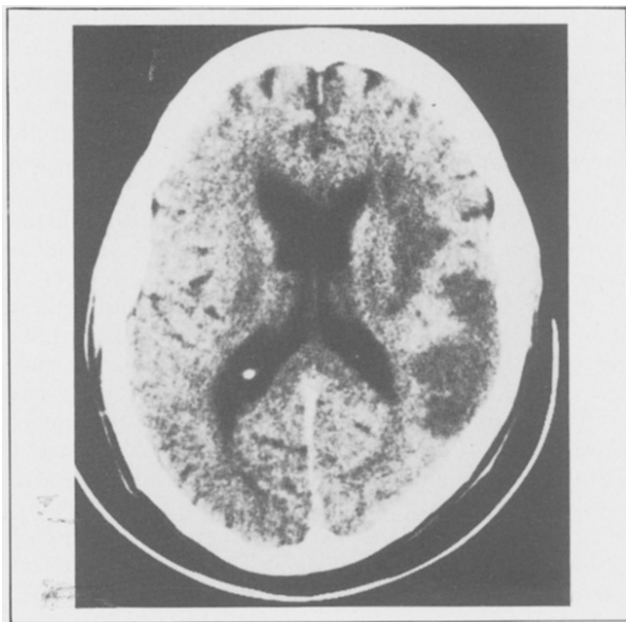


Fig. 6 — CT scan of Case 6 demonstrates right-sided lesions involving the insular region, anterior and posterior temporal lobe, and anterior parietal lobe.

extending into the insula, extreme capsule, claustrum, and external capsule region with sparing of most of the putamen. There was an additional lesion present in the anterior and inferior temporal lobe, and the middle and inferior temporal gyrus areas including both surface and deep regions. The lesion had a large superior extension into the lobe in involving supramarginal and angular gyrus areas. It extended below the surface towards the lateral border of the posterior portion of the body of the lateral ventricle. Another lesion was observed anterolateral to the right frontal horn deep to the middle frontal gyrus, extending superiorly into the white matter deep to the lower motor and sensory areas.

Audiological examination revealed bilateral normal pure tone thresholds at 500-2000 Hz, with moderate sensorineural loss at 3000-8000 Hz and good speech discrimination.

## EXPERIMENTAL INVESTIGATIONS

### *Methodology*

From 50 voice samples of persons well-known in politics and entertainment and developed in previous studies of familiar voice recognition by normal subjects (Van Lancker, Kreiman and Emmorey, 1985; Van Lancker, Kreiman and Wickens, 1985), 25 voices familiar to most older subjects were chosen for presentation. The stimuli had been prepared using a speech-wave editing program on a PDP 11/23 computer to comprise four-second samples of each target speaker without pauses or background noise. A written pretest ensured that the correct answer was not available on the basis of content. Response sheets consisting of vertically aligned photographs of the target and 3 foils, randomly ordered, with written names next each photograph were prepared. Foils were selected carefully to challenge the listener to actually recognize the target voice and discourage alternate strategies for voice recognition.

In the testing situation, patients were presented with a response card containing photographs and written names. They were told they would hear someone talking on tape, and that it would be the voice of one of the famous persons represented on the response card. The names were also read aloud by the examiner, so that the patient had access to the written name, spoken name, and a corresponding photograph in making a response. This ensured that a deficit extraneous to voice recognition (alexia, comprehension deficit, prosopagnosia, or visual deficits) would have minimal effect on the response. In particular, the written and spoken names were included to provide a response mode for any patients who might have difficulty recognizing faces. The vertical display on each response card compensated for visual neglect. To respond, the patient pointed to one of four choices. Three practice items were presented, and the practice session was repeated until it was clear that the patient understood the task.

Following the familiar voice recognition testing, a survey was administered to each patient, identifying which of the target voices the patient felt he/she would normally recognize. Only voices of personalities known to the subjects were scored. In this way, the test assessed recognition of familiar voices only, as determined by self-report.

For the discrimination task, unfamiliar voice stimuli were drawn from those used in a previous study (Kreiman and Papcun, 1985). Utterances excerpted from tape-recording of 10 male Southern Californians with similar dialects and in the same age group (20-31 years old) were arranged into a same/different task. Twenty-six tape-recorded sentence pairs were prepared, such that the two utterances within each pair were spoken by the same person or by 2 different people. In 13 pairs the two voices represented a single speaker; in the other 13 pairs, they represented 2 different speakers. Within a pair of voices the speakers always said the same thing: when speakers were the same, utterances were taken



from recordings made on different dates, so listeners never compared two identical utterances. The patients was told to say whether the pair of utterances were said by the same person or by two different people. Patients with a severe speech production impairment were given cards with the written words "same" or "1" (for one person) and "different" or "2" (for two people) for a pointing response. Three practice items were presented with feedback, and repeated until the task was understood. The set of discrimination pairs had been determined to match the familiar voice set in task difficulty by testing normal subjects in a larger population (Kreiman and Papcum, 1985).

## RESULTS

Normal-control performance values on discrimination and recognition tasks were obtained from testing 30 healthy subjects ages 50-85 on the familiar-recognition protocol and the unfamiliar-discrimination protocol. Performance by brain damaged subjects was compared with means and standard deviations derived from this populations. Chance value for the discrimination task is fixed at 50%; for the familiar recognition task, chance "floats" between 25 and 50%, varying with the familiarity of the foils (wrong choices) to the individual subject, but for this study chance value was placed conservatively at 50%. The age-matched normal control group achieved a mean of 85.1% in voice discrimination (SD = 10.44) and 83.1% (SD = 9.09) in voice recognition. Normal means vary slightly as a function of age, and we report age-adjusted normal-control mean scores for comparison of each case described here.

In the normal group, the mean difference between scores on the two tasks was 8.45 percentage point (SD = 7.21). The differences in performance scores reported for the 6 clinical cases below range between 26 and 57 percentage points, values more than 2 standard deviations beyond the normal mean.

TABLE I

*Performance on Tasks of Voice Discrimination and Recognition (deficits highlighted) (L = Left; R = Right; BI = Bilateral)*

Case	Age	Score		Lesion	
		Discrimination	Recognition	Side	Site
1	61	50%	92%	BI	R temporal L temporo parietal
2	62	58%	84%	L	Frontal-temporo-parietal
3	59	69%	92%	L	Temporal
4	74	73%	16%	BI	R parietal L parietal
5	82	89%	50%	BI	R parietal L occipital
6	69	58%	41%	R	Temporoparietal

Results on voice recognition and voice discrimination tasks for the 6 cases are shown in Table I. In all cases, attention and motivation appeared constant across the two tests. Practice items ensured that each patient understood both tasks; a minimum of verbal instruction was required. All 6 patients exhibited awareness of the task demands, alertness, and full cooperation. Note that response options included the photographed face, the written name, and the spoken name of each of the four choices. Thus no subject should fail the recognition task due to selective prosopagnosia, auditory comprehension deficit, or alexia.

Case 1 performed at chance (50%) on voice discrimination, but achieved 92% correct on voice recognition; normal-control means for his age group (61-70) were 80.5% for discrimination, and 80% for recognition.

Case 2 scored 58% on voice discrimination and 84% on voice recognition (normal means are the same as for Case 1).

Case 3 scored 69% on voice discrimination (normal = 90%), 92% on recognition (normal = 89%).

Case 4 showed the opposite pattern, with a score of 73% on voice discrimination (normal = 73%), but severe impairment (16%) on voice recognition (normal = 77%). The familiar voice recognition test was administered after a 2 week interval for a second time, with similar results. He expressed doubt and uncertainty about the target voices during both testing sessions, even though he demonstrated familiarity with the personalities.

Case 5 scored 89% on discrimination (compared to normal mean of 73%) while his recognition score was 50% (normal means = 77%).

Case 6 performed at 58% on discrimination, and 41% on recognition, representing near-chance performance on both protocols. This intelligent and cooperative patient appeared "agnosic" in voice recognition, in that he demonstrated good familiarity with all of the target voice personalities and responded to the questions with confidence (although incorrectly).

## DISCUSSION

We present these six cases as suggestive that voice perception follows a pattern similar to that described for face perception (Malone et al., 1982). Three patients performed at chance on voice discrimination and normally on voice recognition, 2 showed the converse pattern, and one performed at chance on both tasks. In 5 cases, the discrepancy was more than two standard deviations away from the mean difference in scores on the two tasks observed in 30 age-matched normal-control subjects. A sixth patient was severely deficient in both tasks. Although statistical analysis cannot be applied to confirm these findings, we feel that the 6 well-studied cases suggest that recognition of familiar voice and discrimination of unfamiliar voices are separable neuropsychologic abilities, can be differentially affected by cerebral injuries, and may be mediated by different anatomic structures. Besides the observation that discrimination of unfamiliar voices and recognition of familiar voices are separable abilities, these findings demonstrate that, in a given patient, discrimination can be severely deficient, while familiar voice recognition is intact. This finding indicates that recognition

is not dependent on discrimination. It follows that discrimination between voices, or "telling one voice from another", is not merely a basic step in a process leading to recognition, but that the two are different and separate neuropsychological abilities.

Anatomic correlations with the identified deficits in the two voice perception tasks must be tentative given the small number of patients studied and the multiplicity of their lesions. Nevertheless, the pattern of cerebral insults suggests a potential clinicoanatomic correlation. All patients with deficits in voice recognition had lesions involving the right parietal region. One patient (Case 6) had a lesion limited to the right temporoparietal cortex, whereas Cases 3 and 5 had additional left occipital and left parietal lesions, respectively. Patients with impairments in voice discrimination had lesions involving either the right or left temporal lobe; no patient with temporal lobe damage was seen to perform normally on discrimination. Although one patient (Case 1) with abnormal discrimination had bilateral lesions, Cases 2 and 3 had single lesions involving the left temporal lobe and Case 6 had a single lesion involving the right temporal lobe. To the extent that anatomic conclusions can be derived from radiologic studies, it appears that recognition of familiar voices is dependent on right, lateral, parietal integrity, whereas discrimination of two unfamiliar voices may be disrupted by temporal lobe lesions of either hemisphere. Figure 7 and 8 summarize CT-scan data from the 6 patients.

One possible explanation for the observed dissociation between voice recognition and discrimination is that recognizing a familiar voice involves recognition of a complex auditory pattern followed by association with stored knowledge,

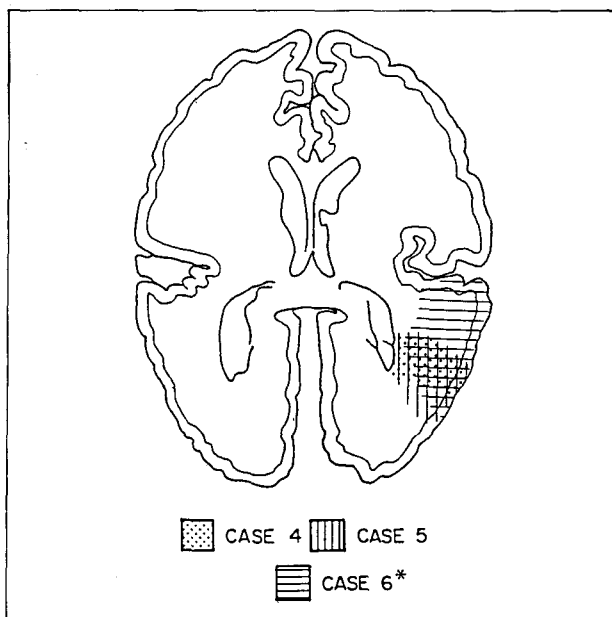


Fig. 7 — Inferior right-side parietal lesion site common to all patients (Cases 4, 5, 6) with voice recognition defects. Case 6 exhibited deficits in both voice recognition and discrimination.

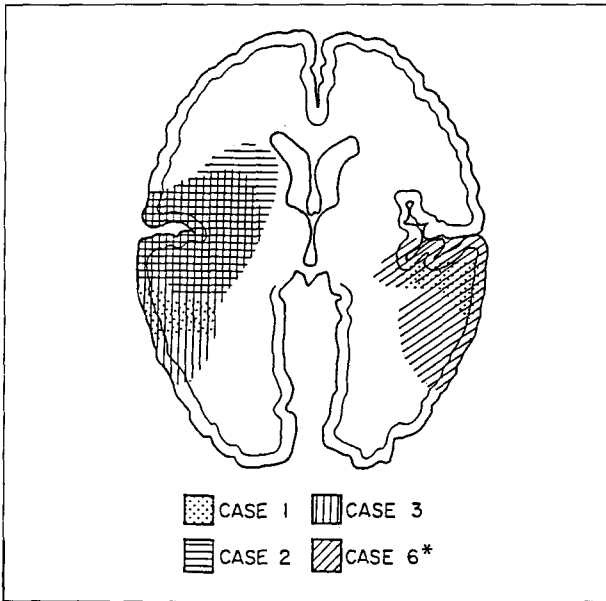


Fig. 8 — Temporal lobe lesion sites demonstrated in patients with voice discrimination abnormalities (Cases 1, 2, 3, 6). Case 6 had deficit in both voice recognition and discrimination.

whereas discriminating between two unfamiliar voices demands, besides overall pattern recognition, analysis of auditory detail, without further association. Special pattern recognition and association abilities have previously been attributed to posterior areas of the right hemisphere (Bogen, 1969; Bradshaw and Nettleton, 1983; Levy, 1974) and perception of auditory features is known to be represented in the temporal lobes on both sides (Neff, 1961). Dichotic listening results suggest that complex auditory patterns are better recognized in the right than the left hemisphere (Bryden, 1982). Dichotically presented nonverbal sounds of all kinds such as chordal stimuli (Gordon, 1970; Sidtis, 1981), nonverbal vocalizations (King and Kimura, 1972; Carmon and Nachshon, 1973), chamber music melodies (Kimura, 1967), sonar signals (Chaney and Webster, 1966), environmental sounds (Curry, 1967), emotional tone in music (Bryden, Ley and Sugarman 1982), and intonation contours (Blumstein and Cooper, 1974) are recognized better in the left ear, implying a right hemisphere superiority. Clinical studies also support the view that the right hemisphere excels at recognition of auditory patterns including components of music (Milner, 1962), familiar melodies (McFarland and Fortin, 1982), emotional tone (Heilman, Scholes and Watson, 1975), and animal cries (Assal and Aubert, 1979).

One study (Faglioni, Spinnler and Vignolo, 1969) contradicting this general view reports that familiar sound *recognition*, in a picture matching task similar to that used in our voice recognition protocol, was impaired only in LBD subjects who were also aphasic but not in RBD subjects, whereas sound *discrimination*, using a same/different task similar to our voice discrimination protocol, was impaired only in RBD subjects. No information on lesion sites within the hemisphere was provided. The discrimination results would agree with ours if there were many fewer subjects with temporal lobe damage in the LBD than in the

RBD groups. The findings for sound recognition are discrepant, and further studies are necessary to explain these differences.

Lack of recognition of familiar voices may be closely related to the deficits in affective comprehension noted in patients with right-sided hemispheric lesions (Heilman, Scholes and Watson, 1975; Heilman, Bowers, Speedie and Coslett, 1984; Ross, 1981). Acoustic information for both mood and voice identity is inextricably embedded in the prosodic component of the speech signal (Van Lancker, 1980). Furthermore, nuances of mood and attitude are most detectable by those familiar with the speaker's voice and loss of this familiarity recognition capacity would disrupt these subtle aspects of communication.

Auditory agnosia refers to loss of the ability to recognize an auditory stimulus despite an intact ability to perceive the target sound (Teuber, 1968). Studies of individual patients suggest that there are several varieties of auditory agnosia with impairment of perception of different aspects of sound. Focal cerebral lesions may impair the recognition of verbal signals in pure word deafness (Coslett, Brashea and Heilman, 1984), of nonverbal sounds in environmental sound agnosia, or of affective information in speech (Heilman, Scholes and Watson, 1975; Spreen, Benton and Finchan, 1965). The present communication replicates a previous finding of deficient familiar voice recognition in RBD patients (Van Lancker and Canter, 1982) and reveals another dimension of defective auditory evaluation in hearing patients - the inability to discriminate between two similar voices. As in the previous study of familiar voice recognition, we propose, by analogy with deficits in facial recognition (prosopagnosia), that disturbances of familiar voice recognition be termed "phonagnosia."

#### ABSTRACT

A dissociation between facial recognition and facial discrimination is well known, but investigations of "phonagnosia" (impairment of voice recognition and discrimination) have not been pursued. Using familiar and unfamiliar voices as stimuli, a marked difference between the ability to recognize familiar voice and the ability to discriminate between unfamiliar voices was identified in five patients, and a sixth showed a severe impairment in both tasks. Clinical and radiologic findings in these cases suggest that recognition of familiar voices is impaired by damage to inferior and lateral parietal regions of the right hemisphere, whereas impairment of voice discrimination abilities is associated with temporal lobe damage of either hemisphere. This dissociation of recognition and discrimination of the human voice suggests that these two functions are mediated by different brain structures and may contribute differentially to clinical syndromes.

*Acknowledgments.* We wish to express special appreciation to Dr. Margaret Naeser, who kindly undertook a detailed analysis of one of the CT-scans. Dr. W. Burgess assisted in preparing stimulus materials. Patient scheduling and testing was facilitated by the cooperation of D. Frank Benson, M.D., Bruce Gerratt, Ph.D., Bette Hadler, M.A., David Keith, M.A., Daniel Kempler, Ph.D., Jeffrey Metter, M.D., Bruce Miller, M.D., Gail Monahan, M.A., and Adam Wechsler, M.D.

This project was supported in part by the Veterans Administration.

## REFERENCES

- ASSAL, G. and AUBERT C. La reconnaissance des onomatopées et des cris d'animaux lors de lésions focalisées du cortex cérébral. *Revue Neurologique*, 135: 65-73, 1979.
- ASSAL, G., ZANDER, E., KREMIN, H., and BUTTET, J. Discrimination des voix lors des lésions du cortex cérébral. *Archives Suisses de Neurologie, Neurochirurgie, ed de Psychiatrie*, 119: 307-315, 1976.
- BARBIZET, J., DUIZABO, P., ENOS, G., and FUCHS, C. Reconnaissance de messages sonores: bruits familiers et airs musicaux familiers lors des lésions cérébrales unilatérales. *Revue Neurologique*, 121: 624-630, 1969.
- BENTON, A. The neuropsychology of facial recognition. *American Psychologist*, 40: 176-186, 1980.
- BENTON, A., and VAN ALLEN, M.W. Impairment in facial recognition in patients with cerebral disease. *Cortex*, 4: 344-358, 1968.
- BLUMSTEIN, S., and COOPER, W.E. Hemispheric processing of intonation contours. *Cortex*, 10: 146-158, 1974.
- BOGEN, J.E. The other side of the brain. II: An appositional mind. *Bulletin of the Los Angeles Neurological Societies*, 34: 135-162, 1969.
- BRADSHAW, J.L., and NETTLETON, N.C. *Human Cerebral Asymmetry*. Englewood Cliffs, New Jersey: Prentice-Hall, 1983.
- BRYDEN, M.P. *Lateralità: Functional Asymmetry in the Intact Brain*. New York: Academic Press, 1982.
- BRYDEN, M.P., LEY, R.C. and SUGARMAN, J.H. A left-ear advantage for identifying the emotional quality of tonal sequences. *Neuropsychologia*, 20: 83-87, 1982.
- CARMON, A., and NACHSHON, I. Ear asymmetry in perception of emotional nonverbal stimuli. *Acta Psychologica*, 37: 351-357, 1973.
- CHANEY, R.E., and WEBSTER, J.C. Information in certain multidimensional sounds. *Journal of the Acoustical Society of America*, 40: 447-455, 1966.
- COSLETT, H.B., BRASHEA, H.F., and HEILMAN, K.M. Pure word deafness after bilateral primary auditory cortex infarcts. *Neurology*, 34: 347-352, 1984.
- CURRY, F.K.W. A comparison of left-handed and right-handed subjects on verbal and non-verbal dichotic listening tasks. *Cortex*, 3: 343-352, 1967.
- FAGLIONI, P., SPINNLER, H., and VIGNOLO, L. Contrasting behavior of right and left hemisphere-damaged patients on a discriminative and a semantic task of auditory recognition. *Cortex*, 5: 366-389, 1969.
- GOODGLASS, H., and KAPLAN, E. *The Assessment of Aphasia and Related Disorders*. Philadelphia: Lea and Febiger, 1972.
- GORDON, H.W. Hemispheric asymmetries in the perception of musical chords. *Cortex*, 6: 387-398, 1970.
- HEILMAN, K.M., BOWERS, D., SPEEDIE, L., and COSLETT, H.B. Comprehension of affective and nonaffective prosody. *Neurology*, 34: 917-921, 1984.
- HEILMAN, K.M., SCHOLES, R., and WATSON, R.T. Auditory affective agnosia: disturbed comprehension of affective speech. *Journal of Neurology, Neurosurgery, and Psychiatry*, 38: 69-72, 1975.
- KIMURA, D. Left-right differences in the perception of melodies. *Quarterly Journal of Experimental Psychology*, 16: 355, 1964.
- KIMURA, D. Functional asymmetry of the brain in dichotic listening. *Cortex*, 3: 163-178, 1967.
- KING, L.F., and KIMURA, D. Left-ear superiority in dichotic perception of nonverbal sounds. *Canadian Journal of Psychology*, 26: 111-116, 1972.
- KREIMAN, J., and PAPCUN, G. Voice discrimination by two listener populations. *UCLA Working Papers in Phonetics*, 61: 45-60, 1985.
- LEVY, J. Psychobiological implications of bilateral asymmetry. In S.J. Dimond and J.G. Beaumont (Eds.), *Hemispheric Function in the Human Brain*. New York: John Wiley and Sons, 1974.
- MALONE, D., MORRIS, H., KAY, M., and LEVIN, H. Prosopagnosia: A double dissociation between the recognition of familiar and unfamiliar faces. *Journal of Neurology, Neurosurgery, and Psychiatry*, 45: 820-822, 1982.
- McFARLAND, H.R., and FORTIN, D. Amusia due to right temporo-parietal infarct. *Archives of Neurology*, 39: 725-727, 1982.
- MEADOWS, J.C. The anatomical basis of prosopagnosia. *Journal of Neurology, Neurosurgery, and Psychiatry*, 37: 489-501, 1974.
- MILNER, B. Laterality effects in audition. In V.B. Mountcastle (Ed.), *Interhemispheric Relations and Cerebral Dominance*. Baltimore: Johns Hopkins Press, 1962.
- NEFF, W. Neural mechanisms of auditory discrimination. In W.A. Rosenblith (Ed.), *Sensory Discrimination*. New York: John Wiley and Sons, 1961.
- ROSS, E.D. The aprosodias. *Archives of Neurology*, 38: 561-569, 1981.

- SCHEGLOFF, E.A. Identification and recognition in telephone conversation openings. In G. Psathas (Ed.), *Everyday Language: Studies in Ethnomethodology*. New York: Irvington Publishers, 1979, pp. 23-78.
- SIDTIS, J.J. The complex tone test: Implications for the assessment of auditory laterality effects. *Neuropsychologia*, 19: 103-111, 1981.
- SPINNLER, H., and VIGNOLO, L. Impaired recognition of meaningful sounds in aphasia. *Cortex*, 2: 337-348, 1966.
- SPREEN, O., BENTON, A.L., and FINCHAM, R.W. Auditory agnosia without aphasia. *Archives of Neurology*, 13: 84-92, 1965.
- TEUBER, H.L. Alteration of perception and memory in man. In L. Weistkerantz (Ed.), *Analysis of Behavioral Change*. New York: Harper and Row, 1968.
- VAN LANCKER, D. Cerebral lateralization of pitch cues in the linguistic signal. *Papers in Linguistics: International Journal of Human Communication*, 13: 201-277, 1980.
- VAN LANCKER, D., and CANTER, G.J., Impairment of voice and face recognition in patients with hemispheric damage. *Brain and Cognition*, 1: 185-195, 1982.
- VAN LANCKER, D., KREIMAN, J., and EMMOREY, K. Familiar voice recognition: Patterns and parameters. I: Recognition of backward voices. *Journal of Phonetics*, 13: 19-38, 1985.
- VAN LANCKER, D., KREIMAN, J., and WICHENS, T. Familiar voice recognition: Patterns and parameters. II: Perception of rate-altered voices. *Journal of Phonetics*, 13: 39-52, 1985.
- VIGNOLO, L. Auditory agnosia: A review and report of recent evidence. In A. Benton (Ed.), *Contributions to Clinical Neuropsychology*. Chicago: Aldine, 1969.
- WARRINGTON, E., and JAMES, M. An experimental investigation of facial recognition in patients with unilateral cerebral lesions. *Cortex*, 3: 317-326, 1967

Diana Van Lancker, Ph.D., 1615 S. Crescent Heights Blvd., Los Angeles, CA. 90035, U.S.A.