

Case Report

A fatal case of *Exophiala dermatitidis* meningoencephalitis in an immunocompetent host: A case report and literature reviewHai-Ying Yu, Ting-Ting Qu, Qing Yang, Jian-Hua Hu, Ji-Fang Sheng^{*}

State Key Laboratory for Diagnosis and Treatment of Infectious Disease, The First Affiliated Hospital, Zhejiang University School of Medicine, 79 Qingchun Rd, Shangcheng District, Hangzhou, Zhejiang, China- 310003



ARTICLE INFO

Keywords:

Exophiala dermatitidis
Central nervous system infection
Antifungal therapy
Immunodeficiency

ABSTRACT

Background: Central nervous system (CNS) infection due to *Exophiala dermatitidis* is rare and fatal, and primarily reported in immunocompromised patients or those with caspase recruitment domain-containing protein 9 deficiency. Herein, we describe a case of an otherwise healthy person (without underlying disease or gene deficiency) diagnosed with *Exophiala dermatitidis* meningoencephalitis. The patient achieved clinical remission under high-dose antifungal therapy in the first 14 months but died after 2 years of the therapy.

Case presentation: A 15-year-old student with headache and fever was admitted to our department. Lumbar puncture showed increased cerebrospinal fluid (CSF) pressure, moderately high CSF protein levels and cell counts, and a remarkable decrease in CSF glucose and chloride. Magnetic resonance imaging of the brain revealed multiple lesions and cerebral pia mater enhancement. CSF culture confirmed *E. dermatitidis* infection. We administered 4-week antifungal therapy of amphotericin B, but his CSF culture remained positive. After receiving the 12-week standard dose of voriconazole (200 mg q12h), the patient's CSF culture became negative, but his condition deteriorated with intracranial lesion enlargement. We administered a high-dose voriconazole therapy (600–800 mg per day) for 12 months, which led to clinical remission. The voriconazole dose was reduced due to adverse effects including hepatic dysfunction and hypokalemia, and the disease progressed with high intracranial pressure and epileptic seizures.

Conclusions: CNS infection caused by *E. dermatitidis* is fatal and the most serious form of fungal infection. Initially, high-dose and long-term antifungal therapy could be effective. Gene defect and related antifungal immunodeficiency may be the most important pathogenic and lethal factor.

1. Introduction

Central nervous system (CNS) infection caused by *Exophiala dermatitidis* is rare and frequently fatal, and mainly reported in immunocompromised patients or people with caspase recruitment domain-containing protein 9 (CARD-9) deficiency. To date, a total of 22 cases, in such patients, have been reported. Among them, 17 patients without risk factors including deficiency or underlying conditions such as contaminated steroid use, continuous ambulatory peritoneal dialysis, acute lymphoblastic leukemia, and acquired immune deficiency syndrome, had poor clinical outcomes, and the other 5 cases with underlying diseases had relatively fair prognoses, suggesting that the

mortality rate was higher in patients without known risk factors than in patients with underlying diseases. Recent studies have found that CARD-9 deficiency is an autosomal-recessive primary immunodeficiency that could increase susceptibility to candidiasis, especially CNS candidiasis in healthy individuals [1]. We here describe the case of an otherwise healthy patient with *E. dermatitidis* meningoencephalitis who achieved clinical remission with high-dose long-term antifungal therapy in the first 14 months. We performed a chromosome study of this patient and his parents but found no CARD-9 deficiency.

Abbreviations: MR, magnetic resonance; CARD-9, caspase recruitment domain-containing protein 9; CSF, cerebrospinal fluid; ITS, internal transcribed spacer; AIDS, acquired immune deficiency syndrome; IGRAs, interferon- γ release assays; TB, tuberculosis; MIC, minimum inhibitory concentration.

^{*} Corresponding author.

E-mail addresses: yuhaiying@zju.edu.cn (H.-Y. Yu), qutingting@zju.edu.cn (T.-T. Qu), yq726226@163.com (Q. Yang), hjianhua0825@zju.edu.cn (J.-H. Hu), jifang_sheng@zju.edu.cn (J.-F. Sheng).

<https://doi.org/10.1016/j.jiac.2021.06.014>

Received 20 April 2021; Received in revised form 8 June 2021; Accepted 14 June 2021

Available online 30 June 2021

1341-321X/© 2021 Japanese Society of Chemotherapy and The Japanese Association for Infectious Diseases. Published by Elsevier Ltd. This is an open access

article under the CC BY-NC-ND license (<http://creativecommons.org/licenses/by-nc-nd/4.0/>).

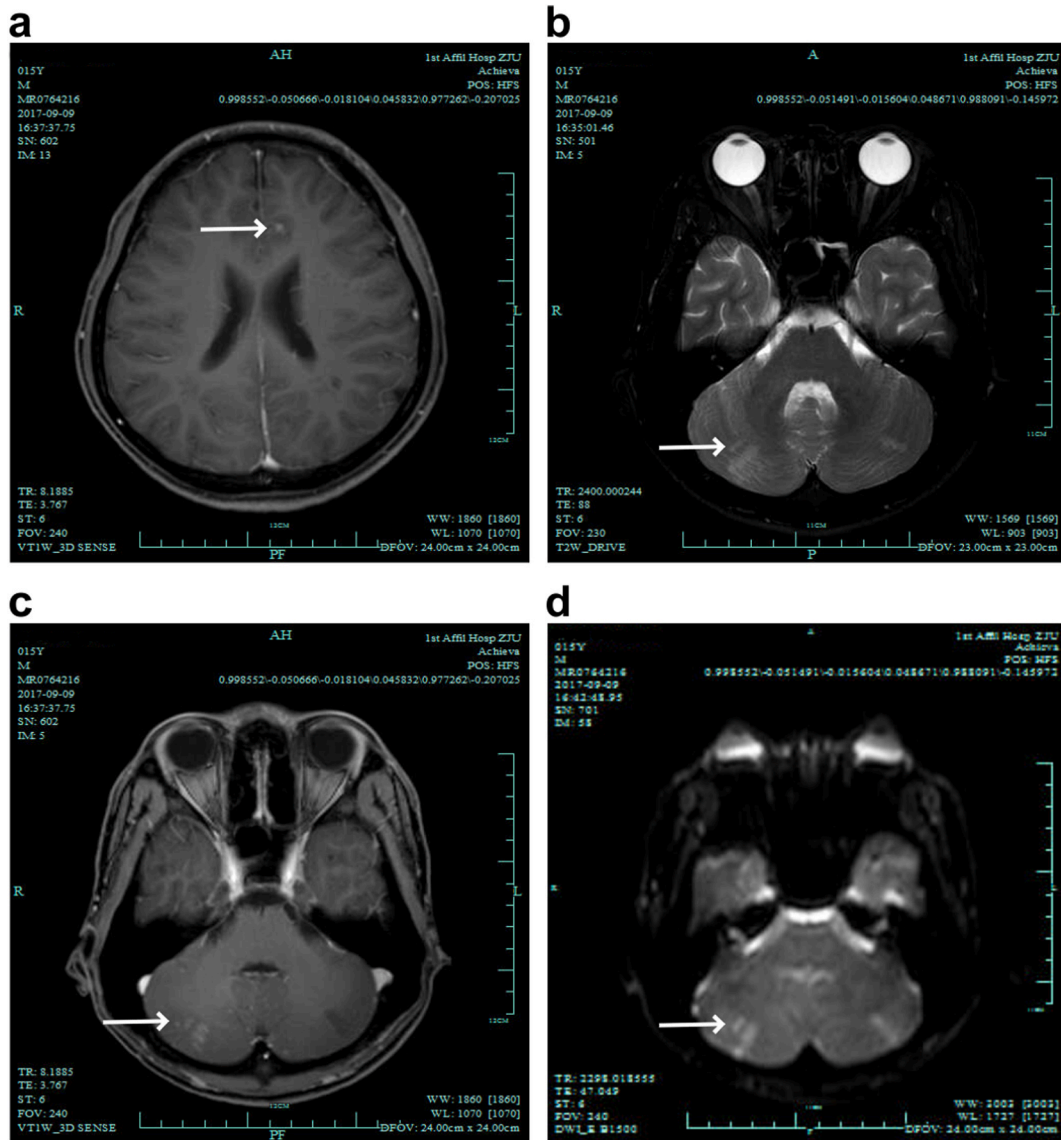


Fig. 1. Brain magnetic resonance imaging showing cerebral pia mater enhancement and multiple lesions. A. Enhanced nodule in the left frontal region. B-D. Multiple bilateral lesions in the cerebellum in T2WI and DWI phase, lesion enhancement of the left cerebellum in enhanced phase. T2WI: T2 weighted image; DWI: Diffusion-weighted image.

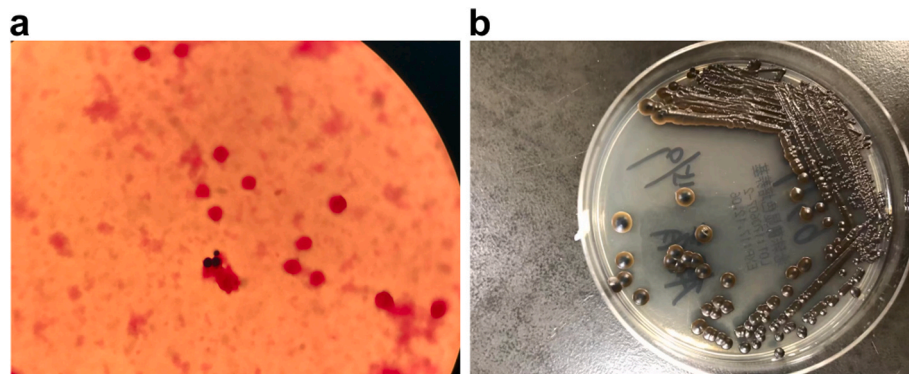


Fig. 2. CSF smear and culture. A. CSF smear and hematoxylin-eosin staining revealing black fungal cells (original magnification $\times 400$). B. CSF culture showing dark fungal colonies of *E. dermatitidis* growing on Sabouraud Dextrose agar at 37 °C.

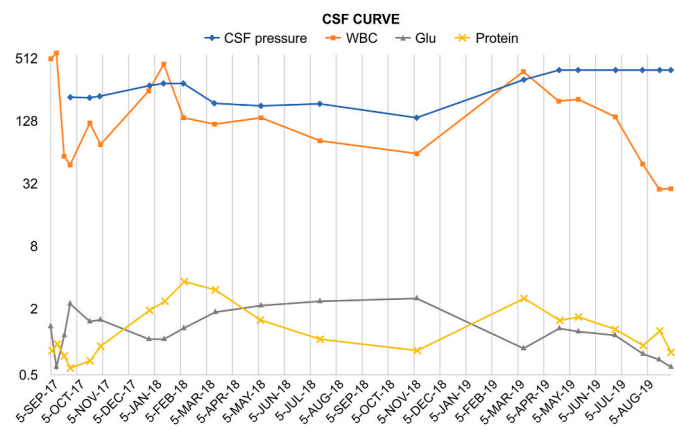


Fig. 3. Change curve of cerebrospinal fluid (CSF) pressure, cell counts, protein, and glucose levels of the patient from September 5, 2017 to August 5, 2019.

2. Case report

A 15-year-old Chinese patient presented with chief complaints of headache for 24 days and intermittent fever for 21 days before he was admitted to our hospital. His body temperature ranged between 38 °C and 39.5 °C, and he complained of headache and dizziness without vomiting and physical tics. Magnetic resonance imaging (MRI) of the brain revealed cerebral pia mater enhancement and multiple lesions in the regions of basal ganglia and parencephalon (Fig. 1). The first lumbar puncture showed a cerebrospinal fluid (CSF) pressure of 220 mmH₂O, and cerebrospinal fluid examination revealed moderate increases in CSF protein levels and cell counts (mainly neutrophils initially and lymphocytes after therapy) and remarkable decreases in CSF glucose and chloride levels (Table S1). He was first diagnosed with tuberculosis meningitis and subsequently received empirical treatment (rifampin 0.45g, isoniazide 0.3g, pyrazinamide 1.5g, ethambutol 0.75g) for tuberculosis meningoencephalitis with 10 mg dexamethasone per day. However, his fever and headache worsened, and his interferon-γ release assays for TB were negative. Moreover, he had high plasma and CSF levels of [1–3]-β-glucan (302 pg/mL and 192 pg/mL, respectively). CSF smear and hematoxylin-eosin staining revealed fungal cells, and the CSF culture revealed the presence of a fungus that was different from *Cryptococcus* and *Candida* (Fig. 2). It was identified as *E. dermatitidis* based on its phenotype, and this was confirmed by internal transcribed spacer (ITS) sequencing [2], the ITS region of 18S ribosomal DNA (rDNA) gene was amplified with the general primer, and the sequence was compared with known ITS gene sequences in the GenBank which referred to *Exophiala dermatitidis*. The anti-tuberculosis treatment was stopped on the 6th day, and he received amphotericin B (0.7 mg/kg) for 4 weeks. However, the CSF culture continued to be positive. Further antifungal susceptibility test showed sensitivity to voriconazole and posaconazole and tolerance to fluconazole (voriconazole minimum inhibitory concentration [MIC] 0.25 mg/L, posaconazole MIC 0.25 mg/L, itraconazole MIC 0.25 mg/L, amphotericin B MIC 1 mg/L, and fluconazole MIC 64 mg/L). We subsequently adjusted the treatment and administered 200 mg q12h voriconazole intravenously. After 12 weeks, his CSF culture became negative, but his body temperature remained abnormal. MRI examination revealed the development of new lesions in the basal ganglia region. We administered high-dose voriconazole (300 mg q12h) for another 12 weeks, and the CSF concentration of voriconazole ranged from 4.1 μg/mL to 7.3 μg/mL. His body temperature gradually became normal, and his headache and dizziness remitted. MRI examination revealed disappearance of the lesions. However, his CSF examination results remained abnormal, and the therapy was continued. After 14 months, he experienced adverse effects of the drug, such as obstinate hypokalemia and liver dysfunction, and the therapy was adjusted to a normal dose of voriconazole, then changed to posaconazole and

Table 1

Comparison of demographics and clinical outcomes of patients with CNS *E. dermatitidis* infection in previous studies and in the present case.

Characteristic	Age, Y (Sex)	Outcome (time from diagnosis to death, months)	CARD-9 deficiency	Reference
Patients without known risk factors				
Country of origin				
China	15 (M)	Death (24)	no	This report
China	8 (M)	Death (17)	NA	[21]
China	3 (M)	Death (3)	NA	[17]
China	23 (M)	Death (1)	YES	[20]
China	30 (F)	Death (0.1)	NA	[16]
China	19 (F)	Death (5)	NA	[16]
China	3 (F)	Death (6)	NA	[16]
Angola	5 (F)	Relapse	Yes	[7]
Korea	28 (M)	Death (0.5)	NA	[12]
India	21 (M)	Cure (12)	NA	[13]
Japan	17 (M)	Death (48)	NA	[14]
Japan	30 (F)	Death (3)	NA	[14]
Japan	5 (F)	Death (1)	NA	[14]
Japan	26 (F)	Death (9)	NA	[14]
Japan	19 (M)	Death (2)	NA	[14]
Japan	10 (M)	Death (11)	NA	[14]
Japan	20 (M)	Death (NA)	NA	[14]
Pakistan	70 (M)	Death (0.5)	NA	[15]
Immunocompromised patients with predisposing factors				
Chronic granulomatous disease	21 (F)	Cure	NA	[19]
Hematopoietic stem cell transplant	Adult (M)	Death	NA	[18]
Long-term steroid use	77 (F)	Death	NA	[22]
Long-term steroid use	61 (F)	Cure	NA	[22]
Long-term steroid use	71 (F)	ND	NA	[22]

NA: not applicable; ND: not done.

amphotericin B, and eventually discontinued. During his last 2 months, his condition worsened with slow reactions and intermittent seizures. His intracranial pressure was more than 400 mmH₂O, and MRI examination revealed hydrocephalus. The change curve of cerebrospinal fluid pressure, cell counts, protein, and glucose levels are shown in Fig. 3. He died after 2 years of therapy.

3. Discussion

Exophiala dermatitidis, (a type of black yeast) is an opportunistic pathogen primarily responsible for skin infections [3]. It colonizes the respiratory tract in approximately 6% of cystic fibrosis patients. Invasive *E. dermatitidis* disease involves the lungs, peritoneum, blood, liver, lymph nodes, and brain [4]. It is a rare and fatal infection that has predominantly been reported in patients with predisposing factors such as contaminated steroid use, continuous ambulatory peritoneal dialysis, acute lymphoblastic leukemia, and acquired immune deficiency syndrome [5–7]. In contrast, CNS infection caused by *E. dermatitidis* is extremely rare and primarily affects otherwise healthy people without known risk factors. Most of the patients die despite receiving active treatment [8]. Since 1980, 22 cases of *E. dermatitidis* meningoencephalitis have been reported worldwide (Table 1); among them 17 cases were associated with no known risk factors. All 17 patients died or showed relapse despite receiving active antifungal treatment, which indicate specific gene defect maybe the pathogenesis.

Recent studies have shown that most patients with invasive *E. dermatitidis* disease, which were not associated with any known risk factors were of Asian descent (China, Japan, South Korea, Turkey, and Pakistan) [12–17], and some of them were diagnosed with CARD-9 deficiency [8,20]. The latter is an autosomal-recessive primary

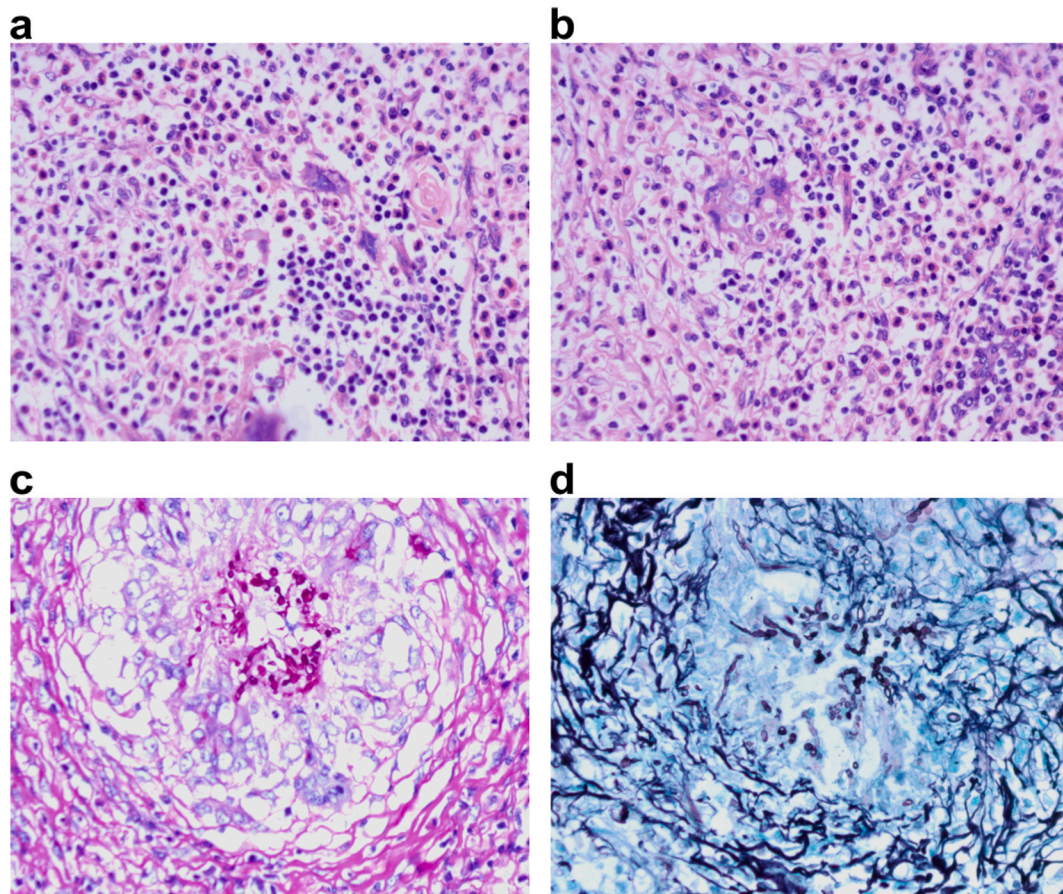


Fig. 4. Histological features of cervical lymph node biopsy specimen carried out by hematoxylin-eosin, Periodic acid-Schiff, and Gomori methenamine silver staining techniques. Arrows indicate fungal agents. A-B. hematoxylin-eosin (HE) staining showing fungi surrounded by epithelioid and giant cell granuloma (original magnification $\times 400$). C. Periodic acid-Schiff (PAS) staining of the fungi (original magnification $\times 400$). D. Gomori methenamine silver (GMS) staining of this area of fungi (original magnification $\times 400$).

immunodeficiency, which could increase susceptibility to candidiasis, especially CNS candidiasis. Inherited CARD-9 deficiency was recently reported in otherwise healthy persons with severe invasive fungal infections caused by *Candida*, *Phialophora*, *Exophiala*, and *Trichophyton*, including meningoencephalitis [9].

CARD-9 is an adaptor molecule that mediates intracellular signaling downstream of innate pattern recognition receptors involved in antifungal immunity [10]. Despite treatment with strong antifungal agents, the infection may not be controlled. Most of the patients had disease relapse or even died. Therefore, we sequenced CARD-9 gene by Exome Sequencing of the patient and his parents in the present case, but found no mutants.

The patient was otherwise healthy without systemic diseases. However, 5 years ago, when he was 10 years old; he had recurrent fever and multiple cervical lymphadenectasis for 2 months, and marked persistent eosinophilia with up to 60% eosinophils in his peripheral blood without parasitic infection. High levels of plasma [1–3]- β -glucan (890 pg/mL) were observed, and fungal infection was identified by cervical lymph node biopsy. Pathological examination revealed fungal hyphae in the slice (Fig. 4). He subsequently underwent treatment with 400 mg fluconazole per day for 1 year, and his body temperature and eosinophil count gradually returned to normal. The relationship between the two invasive fungal infections in this case remains unknown, which implies a specific deficiency in the antifungal immune response of this otherwise healthy patient. Gene deficiency is the most probable explanation in most cases, and CARD-9 deficiency may have enabled a severe, invasive, and fatal fungal infection; although this was not the case with our patient. Patients with CARD-9 deficiency have defective neutrophils,

which are involved in the intracellular killing of the yeast *Candida*, and severely reduced levels of circulating Th17 cells and TNF- α [1]. The patient in the present case recovered from lymph node fungal infection but not from CNS *E. dermatitidis* infection; different outcomes were observed due to different infection sites and fungal species [11]. Despite the *in vitro* susceptibility to antifungal agents, the infection may relapse and can be potentially fatal. Optimal treatment needs to be defined for *E. dermatitidis* meningoencephalitis.

Ethics approval

This study obtained approval from the Ethics Committee of the First Affiliated Hospital, Zhejiang University.

Funding source

The funding source had no involvement in study design; in the collection, analysis and interpretation of data; in the writing of the report; and in the decision to submit the article for publication.

Authorship statement

Hai-Ying Yu was responsible for the patient's treatment and consulting literature. Ji-Fang Sheng was the chief investigator and was responsible for the treatment. Ting-Ting Qu and Qing Yang were specialists in pathogen culturing and identification. Jian-Hua Hu was responsible for patient follow-up. All authors contributed to the writing of the final manuscript.

Informed consent

The patient provided signed informed consent for his data to be analyzed and reported.

Declaration of competing interest

None.

Acknowledgements

This work was supported by a research grant from the Chinese National Thirteenth Five Years Project in Science and Technology (2017ZX10202201).

Appendix A. Supplementary data

Supplementary data to this article can be found online at <https://doi.org/10.1016/j.jiac.2021.06.014>.

References

- [1] Gavino C, Cotter A, Lichtenstein D, Lejtenyi D, Fortin C, Legault C, et al. CARD9 deficiency and spontaneous central nervous system candidiasis: complete clinical remission with GM-CSF therapy. *Clin Infect Dis* 2014;59:81–4. <https://doi.org/10.1093/cid/ciu215>.
- [2] Lau SK, Woo PC, Chiu SK, Leung KW, Yung RW, Yuen KY. Early diagnosis of *Exophiala* CAPD peritonitis by 18S ribosomal RNA gene sequencing and its clinical significance. *Diagnostic Microbiol Infect Dis* 2003;46:95–102. [https://doi.org/10.1016/s0732-8893\(03\)00014-2](https://doi.org/10.1016/s0732-8893(03)00014-2).
- [3] Sudhadham M, Prakitsin S, Sivichai S, Chaiyarat R, Dorresteim GM, Menken SB, et al. The neurotropic black yeast *Exophiala dermatitidis* has a possible origin in the tropical rain forest. *Stud Mycol* 2008;61:145–55. <https://doi.org/10.3114/sim.2008.61.15>.
- [4] Blasi B, Tafer H, Tesei D, Sterflinger K. From glacier to sauna: RNA-seq of the human pathogen black fungus *Exophiala dermatitidis* under varying temperature conditions exhibits common and novel fungal response. *PLoS One* 2015;10:e0127103. <https://doi.org/10.1371/journal.pone.0127103>.
- [5] Homa M, Manikandan P, Saravanan V, Revathi R, Anita R, Narendran V, et al. *Exophiala dermatitidis* endophthalmitis: case report and literature review. *Mycopathologia* 2018;183:603–9. <https://doi.org/10.1007/s11046-017-0235-4>.
- [6] Berger JS, Cusumano LR, Derose JJ, Sarwar UN. *Exophiala* (*wangiella*) *dermatitidis* prosthetic aortic valve endocarditis and prosthetic graft infection in an immune competent patient. *Case Rep Infect Dis* 2017;2017:4839314. <https://doi.org/10.1155/2017/4839314>.
- [7] Klasinc R, Riesenhuber M, Bacher A, Willinger B. Invasive fungal infection caused by *Exophiala dermatitidis* in a patient after lung transplantation: case report and literature review. *Mycopathologia* 2019;184:107–13. <https://doi.org/10.1007/s11046-018-0275-4>.
- [8] Lanterrier F, Barbati E, Meinzer U, Liu L, Pedergnana V, Migaud M, et al. Inherited CARD9 deficiency in 2 unrelated patients with invasive *Exophiala* infection. *J Infect Dis* 2015;211:1241–50. <https://doi.org/10.1093/infdis/jiu412>.
- [9] Lanterrier F, Mahdavi SA, Barbati E, Chaussade H, Koumar Y, Levy R, et al. Inherited CARD9 deficiency in otherwise healthy children and adults with *Candida* species-induced meningoencephalitis, colitis, or both. *J Allergy Clin Immunol* 2015;135:1558–68. <https://doi.org/10.1016/j.jaci.2014.12.1930>.
- [10] Alves de Medeiros AK, Lodewick E, Bogaert DJ, Haerynck F, Van Daele S, Lambrecht B, et al. Chronic and invasive fungal infections in a family with CARD9 deficiency. *J Clin Immunol* 2016;36:204–9. <https://doi.org/10.1007/s10875-016-0255-8>.
- [11] Mukai Y, Nureki S, Hata M, Shigenaga T, Tokimatsu I, Miyazaki E, et al. *Exophiala dermatitidis* pneumonia successfully treated with long-term itraconazole therapy. *J Infect Chemother* 2014;20:446–9. <https://doi.org/10.1016/j.jiac.2014.02.006>.
- [12] Chang CL, Kim DS, Park DJ, Kim HJ, Lee CH, Shin JH. Acute cerebral phaeohyphomycosis due to *wangiella dermatitidis* accompanied by cerebrospinal fluid eosinophilia. *J Clin Microbiol* 2000;38:1965–6. <https://doi.org/10.1128/JCM.38.5.1965-1966.2000>.
- [13] Sood S, Vaid VK, Sharma M, Bhartiya H. Cerebral phaeohyphomycosis by *Exophiala dermatitidis*. *Indian J Med Microbiol* 2014;32:188–90. <https://doi.org/10.4103/0255-0857.129830>.
- [14] Hiruma M, Kawada A, Ohata H, Ohnishi Y, Takahashi H, Yamazaki M, et al. Systemic phaeohyphomycosis caused by *Exophiala dermatitidis*. *Mycoses* 1993;36:1–7. <https://doi.org/10.1111/j.1439-0507.1993.tb00679.x>.
- [15] Ajanee N, Alam M, Holmberg K, Khan J. Brain abscess caused by *Wangiella dermatitidis*: case report. *Clin Infect Dis* 1996;23:197–8. <https://doi.org/10.1093/clinfid/23.1.197>.
- [16] Li DM, Li RY, de Hoog GS, Sudhadham M, Wang DL. Fatal *Exophiala* infections in China, with a report of seven cases. *Mycoses* 2011;54:136–42. <https://doi.org/10.1111/j.1439-0507.2010.01859.x>.
- [17] Chang X1, Li R, Yu J, Bao X, Qin J. Phaeohyphomycosis of the central nervous system caused by *Exophiala dermatitidis* in a 3-year-old immunocompetent host. *J Child Neurol* 2009;24:342–5. <https://doi.org/10.1177/0883073808323524>.
- [18] Hagiya H1, Maeda T2, Kusakabe S2, Kawasaki K3, Hori Y3, Kimura K, et al. A fatal case of *Exophiala dermatitidis* disseminated infection in an allogeneic hematopoietic stem cell transplant recipient during micafungin therapy. *J Infect Chemother* 2019;25:463–6. <https://doi.org/10.1016/j.jiac.2018.12.009>.
- [19] Kenney RT1, Kwon-Chung KJ, Waytes AT, Melnick DA, Pass HI, Merino MJ, et al. Successful treatment of systemic *Exophiala dermatitidis* infection in a patient with chronic granulomatous disease. *Clin Infect Dis* 1992;14:23542. <https://doi.org/10.1093/clinfid/14.1.235>.
- [20] Wang C, Xing H, Jiang X, Zeng J, Liu Z, Chen J, et al. Cerebral phaeohyphomycosis caused by *Exophiala dermatitidis* in a Chinese CARD9-deficient patient: a case report and literature review. *Front Neurol* 2019;10:938. <https://doi.org/10.3389/fneur.2019.00938>.
- [21] Hu Bing, Li Shaoying, Hu Huili, Chen Tianming, Guo Xin, Zhang Zhixiao, et al. Central nervous system infection caused by *Exophiala dermatitidis* in a case and literature review. *Chin J Pediatr* 2014;52:620–4. <https://doi.org/10.3760/cma.j.issn.0578-1310.2014.08.01>.
- [22] Patel AK, Patel KK, Darji P, Singh R, Shivaprakash MR, Chakrabarti A. *Exophiala dermatitidis* endocarditis on native aortic valve in a postrenal transplant patient and review of literature on *E. dermatitidis* infections. *Mycoses* 2013;56:365–72. <https://doi.org/10.1111/myc.12009>.