



Stroke-like episodes with cerebellar ataxia as presenting manifestation of adult-onset anti-*N*-methyl *D*-aspartate receptor encephalitis: an unusual presentation

Rohan Mahale¹ · M. K. Farsana · Anitha Mahadevan² · Joydeep Mukherjee¹ · Vathsala Lakshmi¹ · M. Sandeep¹ · Hansashree Padmanabha¹ · Pooja Mailankody¹ · Mathuranath Pavagada¹

Received: 15 April 2021 / Accepted: 21 June 2021 / Published online: 3 July 2021
© Belgian Neurological Society 2021

Keywords Cerebellum · Ataxia · Stroke · NMDAR · Encephalitis

Dear Sir,

Anti-*N*-methyl *D*-aspartate (NMDA) receptor (anti-NMDAR) encephalitis is an autoimmune encephalitis which was first described in 2007 [1]. Memory deficits are the most common clinical manifestation in patients with anti-NMDAR encephalitis ≥ 45 years [2]. Cerebellar ataxia and stroke-like episodes as presenting manifestation in late-onset anti-NMDAR encephalitis is rare. Hereby, we report a 46-year-old male patient who presented with acute onset cerebellar ataxia of 10-h duration. He had history of acute onset left hemiparesis 15 days prior to present symptoms and improved within 72 h. Brain magnetic resonance imaging (MRI) showed right striato–thalamo–capsular lesion with contrast enhancement, multiple T2 hyperintense ovoid subcortical white matter non-enhancing lesions. Angiography was normal. Cerebrospinal fluid (CSF) analysis showed eight lymphocytes with normal protein and glucose. CSF NMDAR antibodies were strongly positive. He was treated with intravenous methylprednisolone and had complete recovery.

A 46-year-old male patient had history of acute onset holocranial headache 1 month prior to present admission that lasted for 1–2 h with vomiting and blurred vision and improved with analgesics. His blood pressure was normal

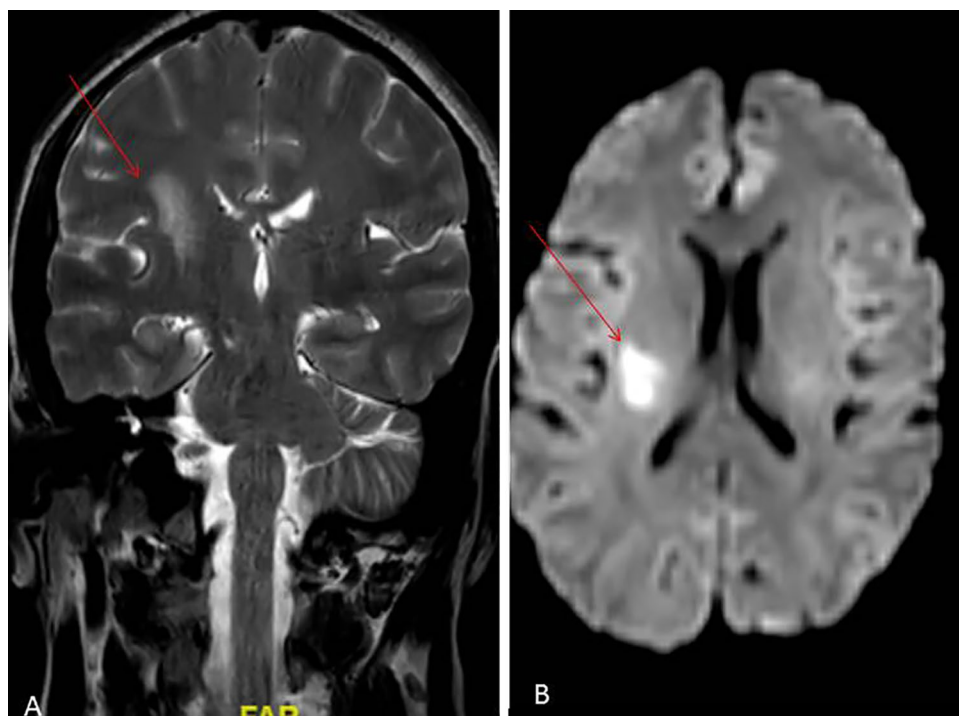
and was evaluated at local hospital with no specific diagnosis. He developed sudden onset left hemiparesis 15 days later without sensory symptoms. His muscle power was 3/5 according to Medical Research Council grading. The hemiparesis lasted for 72 h and improved completely. He was evaluated with brain MRI at local hospital and had right striato-thalamocapsular lesion isointense on T1 and hyperintense on T2 with diffusion restriction suggestive of acute infarct (Fig. 1). Time-of flight magnetic resonance angiography was normal. He was started on aspirin 150 mg with atorvastatin 20 mg per day. 15 days later he developed acute onset unsteadiness in walking with vertigo. It was continuous, required two persons to walk. He was having incoordination in both upper limbs. There was no speech disturbance. He presented to us with above symptoms. Systemic examination was unremarkable. He was conscious, oriented to time, place. Speech was normal. Fundus examination was normal. Extraocular movements were normal with no nystagmus. Other cranial nerves were normal. Motor examination showed normal tone, power and reflexes. Sensory examination was normal. He had bilateral finger-nose incoordination, dysdiadochokinesia and wide-based ataxic gait. A possibility of cerebellar stroke was considered. Brain MRI showed right striato-thalamo-capsular and corona radiata lesion with contrast enhancement, multiple T2 hyperintense ovoid subcortical white matter non-enhancing lesions (Fig. 2). There was no brainstem or cerebellar lesions. Angiography was normal. Complete blood counts, renal, hepatic and thyroid function tests were normal. CSF analysis showed eight lymphocytes with normal protein and glucose. Serum and CSF anti-myelin oligodendrocyte glycoprotein and aquaporin-4 antibodies were negative. Varicella deoxyribonucleic acid polymerase chain reaction in CSF was negative. CSF NMDAR antibodies (cell based immunofluorescence

✉ Rohan Mahale
rohanmahale83@gmail.com

¹ Department of Neurology, National Institute of Mental Health and Neurosciences (NIMHANS), Bangalore 560029, India

² Department of Neuropathology, National Institute of Mental Health and Neurosciences (NIMHANS), Bangalore 560029, India

Fig. 1 Brain MRI T2 coronal image **A** showing hyperintense lesion in right striatothalamo-capsular lesion (red arrow); **B** axial diffusion-weighted image shows diffusion restriction (red arrow) (color figure online)



assay) were strongly positive. Scrotal ultrasonography did not show testicular teratoma. Electroencephalography was normal. He was treated with intravenous methylprednisolone and had complete recovery. He was started on mycophenolate mofetil.

The common clinical manifestations of anti-NMDAR encephalitis include cognitive dysfunction, abnormal behaviour, language/speech dysfunction, seizures, movement disorders, dyskinesias, decreased level of consciousness, autonomic dysfunction and central hypoventilation. It varies with age of onset of the disease. It is more neurological in children and more psychiatric in adults [3]. The occurrence of cerebellar ataxia in patients with anti-NMDAR encephalitis is almost exclusively found in children, and most frequently, it appears later in the disease in combination with other symptoms.

Stroke-like episodes as a presenting manifestation of anti-NMDAR encephalitis has not been reported. There are few reports of cerebellar ataxia as presenting symptom in anti-NMDAR encephalitis. Poorthuis et al. reported a 32-year-old woman who had history of mature ovarian teratomas and depression presented with cerebellar dysarthria, nystagmus, limb incoordination and gait ataxia. Her CSF anti-NMDAR antibodies were positive and serum anti-NMDAR antibodies were negative. The patient was treated with steroids and

intravenous immunoglobulin with significant improvement at 6 months [4]. Similarly, Wang et al. reported a 45-year-old man with 2-week history of ataxia followed by behavioural change, cognitive impairment. He had predominant cerebellar ataxia. Brain MRI showed hyperintense lesions in cerebellum, positive CSF anti-NMDAR antibodies and negative serum anti-NMDAR antibodies. The patient was treated with steroids and intravenous immunoglobulin with significant improvement [5]. The cause for cerebellar ataxia in NMDAR-encephalitis is postulated to be due to altered NMDAR-mediated signalling [6].

Our patient had one episode of stroke involving right thalamocapsular region causing left hemiparesis which recovered within 3 days. Later he had sudden onset cerebellar ataxia with no lesions in cerebellum or brainstem. His serum anti-NMDAR antibodies were negative but CSF antibodies were positive. He had good improvement with intravenous methylprednisolone.

Anti-NMDAR encephalitis has varied presenting manifestation which varies with the age of onset of the disease. A possibility of anti-NMDAR encephalitis has to be considered in adult patients presenting with acute onset cerebellar ataxia. This case adds to the few reports of acute cerebellar ataxia as an initial manifestation of anti-NMDAR encephalitis. Stroke-like episodes has not been reported so far.

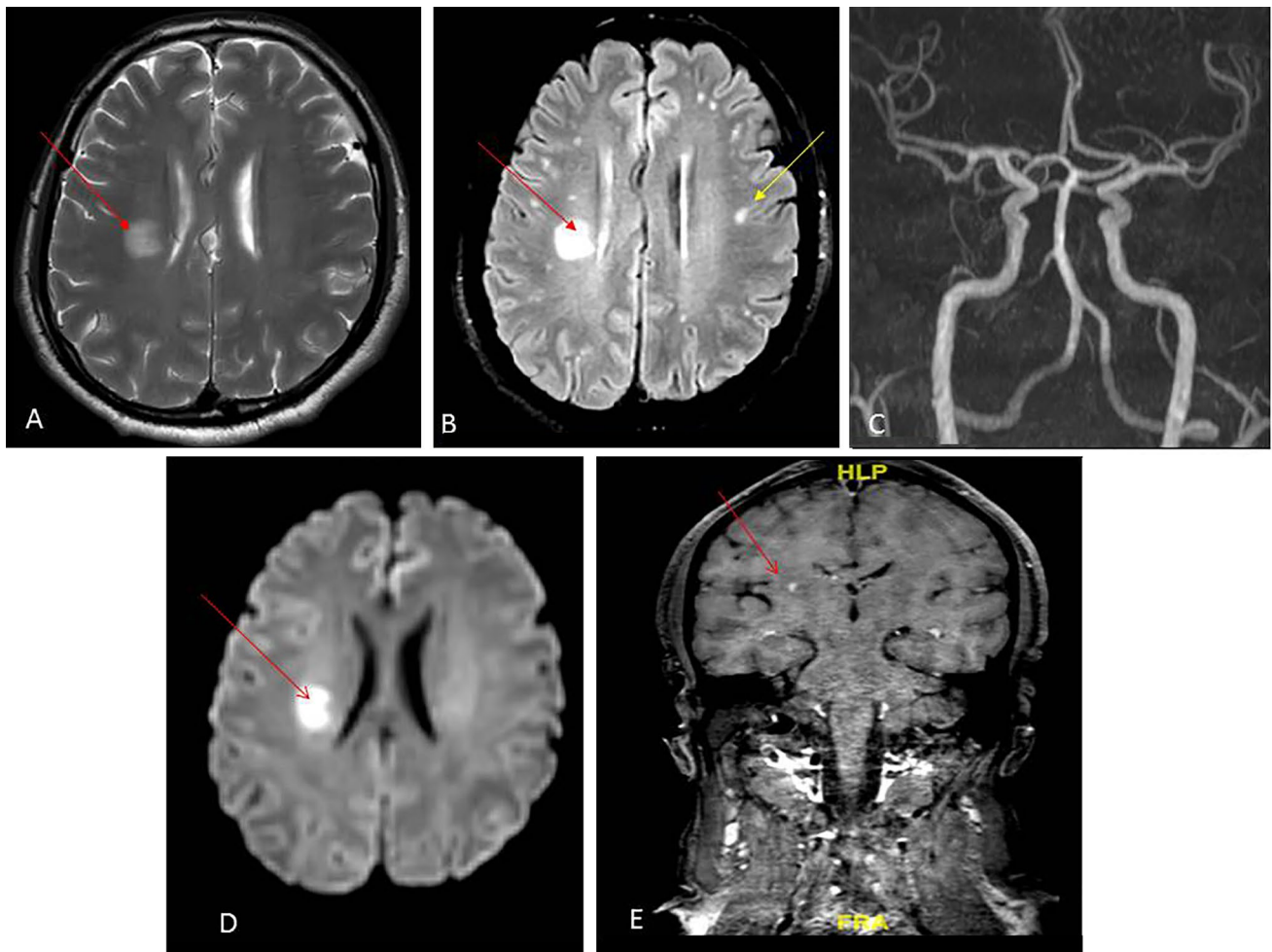


Fig. 2 Brain MRI T2 axial image **A** showing hyperintense lesion in right corona radiata (red arrow); **B** axial fluid-attenuated inversion recovery (FLAIR) image showing hyperintense lesion in right corona radiata (red arrow) with multiple small subcortical hyperintense

lesions (yellow arrow); **C** MR angiography showing no occlusion or stenosis; **D** axial diffusion-weighted image showing diffusion restriction (red arrow); **E** coronal t1-gadolinium enhanced image showing contrast enhancement (red arrow) (color figure online)

Funding Nil.

Declarations

Conflict of interest Nil.

References

- Dalmau J, Tüzün E, Wu HY, Masjuan J, Rossi JE, Voloschin A et al (2007) Paraneoplastic anti-*N*-methyl-D-aspartate receptor encephalitis associated with ovarian teratoma. *Ann Neurol* 61:25–36
- Zhang L, Liu X, Jiang XY, Wang YH, Li JM, Zhou D (2018) Late-onset anti-*N*-methyl-D-aspartate receptor encephalitis in China. *Epilepsy Behav* 84:22–28
- Titulaer MJ, McCracken L, Gabilondo I, Iizuka T, Kawachi I, Bataller L et al (2013) Late-onset anti-NMDA receptor encephalitis. *Neurology* 81:1058–1063
- Poorthuis MHF, van Rooij JLM, Koch AH, Verdonkschot AEM, Leembruggen MM, Titulaer MJ (2019) Cerebellar ataxia as a presenting symptom in a patient with anti-NMDA receptor encephalitis. *Neurol Neuroimmunol Neuroinflamm* 6(4):e579. <https://doi.org/10.1212/NXI.0000000000000579>
- Wang B, Wang C, Ren H, Guan H, Guo S (2020) Cerebellar ataxia as the initial symptom with lesions involving the cerebellum in patient with anti-NMDAR encephalitis: a rare case report and literature review. *J Neuroimmunol* 346:577293
- Llansola M, Sanchez-Perez A, Cauli O, Felipe V (2005) Modulation of NMDA receptors in the cerebellum. 1. Properties of the NMDA receptor that modulate its function. *Cerebellum* 4:154–161

Publisher's Note Springer Nature remains neutral with regard to jurisdictional claims in published maps and institutional affiliations.