

# Venous Cerebral Infarction Due to Thrombosis of an Isolated Intraventricular Cerebral Varix: A Case Report

Masaki Fujino, MD,<sup>a</sup> Shuko Fujiki, MD,<sup>a</sup> Hitomi Michizaki, MD,<sup>a</sup> Takeshi Bo, MD,<sup>a</sup>  
Jun Oyama, MD, PhD,<sup>b</sup> and Akira Machida, MD, PhD<sup>a</sup>

**Objectives:** An isolated intraventricular cerebral varix is a rare entity. Although it is generally asymptomatic, there have been reports of symptomatic cases. Here, we report a case of right hemiplegia and aphasia due to venous infarction caused by thrombosis of the intraventricular varix. **Case presentation:** A 79-year-old woman presented with right-sided hemiplegia and aphasia accompanied by conjugate eye deviation to the left. She had a history of hypertension, dyslipidemia, and asymptomatic isolated cerebral varix located in the left lateral ventricle. Blood analysis indicated no abnormalities in coagulation or fibrinolysis. Plain head computed tomography showed an intraventricular varix in the form of a high-density mass, indicating acute phase thrombosis, and contrast-enhanced computed tomography depicted a filling defect in the varix. In addition, fluid-attenuated inversion recovery imaging showed hyperintense lesions in the deep white matter of the frontal-parietal lobe, indicating venous infarction due to occlusion of the varix of the thalamostriate vein. Glycerol and prophylactic levetiracetam were administered, and she was transferred to another hospital for rehabilitation 23 days after treatment initiation. **Conclusion:** This is the first reported case in which a typically asymptomatic condition, intraventricular cerebral varix, caused venous infarction due to thrombosis and occlusion of the varix of the thalamostriate vein. Careful selection of the treatment strategy is required on a case-by-case basis because an intraventricular varix can cause both bleeding and infarction, which are treated differently.

**Key Words:** Intraventricular cerebral varix—Thrombosis—Venous infarction—Thalamostriate vein

© 2021 Elsevier Inc. All rights reserved.

## Introduction

Isolated cerebral varix is described as a focal dilatation of a single vein.<sup>1</sup> It is a rare clinical entity and typically found incidentally, but symptomatic cases with seizure,

hemorrhage due to rupture, thrombosis with acute clinical deterioration, and mass effect on neighboring structures have been reported.<sup>2-5</sup> It is generally located in the parenchyma or leptomeninges,<sup>4</sup> and symptomatic intraventricular cerebral varix is extremely rare. We herein report a case of right hemiplegia and aphasia due to venous infarction caused by thrombosis of the intraventricular varix.

## Case presentation

A 79-year-old woman was admitted to our hospital with right-sided hemiplegia and aphasia accompanied by conjugate eye deviation to the left. She had a history of hypertension, dyslipidemia, and an asymptomatic isolated cerebral varix located in the left lateral ventricle

From the <sup>a</sup>Department of Neurology, Tsuchiura Kyodo General Hospital, Ibaraki, Japan; and <sup>b</sup>Department of Diagnostic Radiology and Nuclear Medicine, Tokyo Medical and Dental University, Tokyo, Japan.

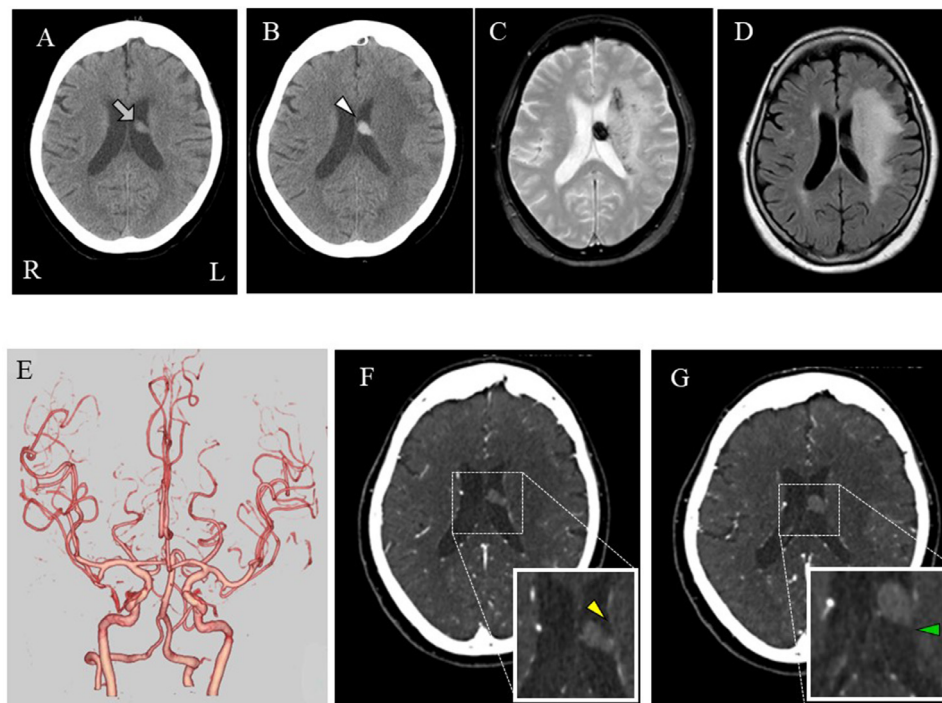
Received April 9, 2021; revision received June 9, 2021; accepted June 13, 2021.

Corresponding author at: Department of Neurology, Tsuchiura Kyodo General Hospital, 4-1-1 Otsuno, Tsuchiura-shi, Ibaraki, 300-0028, Japan. E-mail: [akinuro@tmd.ac.jp](mailto:akinuro@tmd.ac.jp).

1052-3057/\$ - see front matter

© 2021 Elsevier Inc. All rights reserved.

<https://doi.org/10.1016/j.jstrokecerebrovasdis.2021.105954>



**Fig. 1.** Temporal changes in brain images before (A) and after (B-F) hospitalization (A) Axial plain head computed tomography (CT) showed an isodense mass in the left ventricle (gray arrow). (B) Axial enhanced CT showed a hyperdense mass, indicating a thrombus in the varix (white arrowhead). (C) T2\*-weighted imaging showed hypointense lesions in the deep white matter of the frontal-parietal lobe, indicating venous congestion. (D) Fluid-attenuated inversion recovery imaging showed hyperintense lesions in the deep white matter of the frontal-parietal lobe, indicating venous infarction. (E) CT angiography showed no stenosis or occlusion. (F-G) Contrast-enhanced CT showed a filling defect of the varix and poor contrast effect in the left anterior caudate vein (yellow arrowhead) and thalamostriate vein (green arrowhead) compared to the contralateral side in the original venography image.

(Fig. 1A). On physical examination, her heart rate was within the normal range, at 75 bpm. Her blood pressure was 156/83 mmHg. Neurological examination showed consciousness disturbance (Glasgow Coma Scale score of 9), conjugate eye deviation to the left, aphasia, and right hemiplegia (manual muscle test grade of 3 in the right upper and lower extremities). She could not speak, stand, or walk. Blood analysis indicated a prothrombin time/international normalized ratio of 1.06, an activated partial thromboplastin time of 23.6 s, a d-dimer level of 3.9  $\mu\text{g}/\text{mL}$ , and an antithrombin III level of 97%. Plain head computed tomography (CT) revealed an intraventricular varix as a high-density mass, indicating acute thrombosis (Fig. 1B). Brain magnetic resonance imaging showed scattered hypointense lesions in the white matter around the left ventricle, indicative of venous congestion (T2\*-weighted imaging; Fig. 1C), and a hyperintense area throughout the left deep white matter, suggestive of vasogenic edema (fluid-attenuated inversion recovery; Fig. 1D). CT angiography showed no stenosis or occlusion (Fig. 1E). Contrast-enhanced CT depicted a filling defect in the varix and a poor contrast effect in the left thalamostriate vein (TSV) and its tributaries (e.g., the anterior caudate vein) compared to the contralateral side (the TSV and its tributaries drains into the medullary veins of the posterior frontal and anterior parietal lobes; Fig. 1F, G). These findings led to the conclusive diagnosis of cerebral

venous infarction caused by thrombosis of the varix and occlusion of the left TSV.

We administered glycerol (intravenously, 400 mg twice daily) and prophylactic levetiracetam (intravenously, 1000 mg twice daily). Intravenous heparin was not administered, because the ferritin levels were elevated in the cerebrospinal fluid (49 ng/mL, normal range 5-12 ng/mL) and the complication of subarachnoid hemorrhage could not be completely excluded. Two weeks later, she exhibited broken speech. At 3 weeks after admission, she was able to communicate verbally and walk using handrails. At 23 days after admission, she was transferred to another hospital for rehabilitation.

## Discussion

We present a case of right hemiplegia and aphasia due to venous infarction caused by thrombosis of the intraventricular varix. It should be noted that cerebral varix, which is typically asymptomatic,<sup>5</sup> manifested as neurological symptoms in our case. In addition, thrombosis of the intraventricular varix of the TSV resulted in a further rare condition, venous infarction.

When an asymptomatic intraventricular cerebral varix is discovered incidentally, the currently available literature is not sufficient to determine the risk of rupture, bleeding, and thrombosis in isolated cerebral varices.<sup>6</sup>

The following have been proposed as risk factors for cerebral venous thrombosis: thrombophilia, female health concerns (pregnancy, postpartum state, and hormonal contraceptive therapy), infection, chronic inflammatory diseases, cancer, hematologic disorders, trauma, and nephritic syndrome<sup>7</sup>; however, our patient had no risk factors. Therefore, we consider that it is difficult to predict and prevent a thrombosis of the varix.

Following symptom onset, the management of venous varices is controversial because they could be a potential cause of both thrombosis and hemorrhage.<sup>5</sup> Only one case of isolated intraventricular varix has been reported previously<sup>8</sup>. In that report, complete right hemiplegia developed after a varix was excised. Although the authors did not mention the causes of hemiplegia, TSV occlusion may have occurred due to varix excision. The TSV arises from the confluence of the anterior caudate vein and the terminal vein. It drains the medullary veins of the posterior frontal and anterior parietal lobes, the caudate nucleus, and the internal capsule<sup>9</sup>. Therefore, TSV occlusion causes venous congestion in these vascular territories and triggers hemiparesis<sup>3</sup>. It is considered that our case also developed venous infarction by a similar mechanism.

Although our patient presented with thrombosis of the varix, we did not opt to perform anticoagulation therapy because subarachnoid hemorrhage was also suspected from the elevation of ferritin levels in cerebrospinal fluid. According to the previous two reports of cerebral varix with thrombosis,<sup>2,10</sup> their clinical course was relatively good with conservative treatment without anticoagulation. Surgical or endovascular treatment is only considered in patients with severe symptoms arising from hemorrhage, thrombosis, or neurovascular compression. Otherwise, it is not suggested because the varix may drain to a healthy venous territory<sup>4</sup>. In cases of stroke associated with cerebral varix, more careful observation is important to select an appropriate treatment for each patient.

## Conclusion

This is the first report of a typically asymptomatic intraventricular cerebral varix caused venous infarction due to thrombosis of the varix of the TSV. In our case, conservative treatment improved the clinical symptoms, but further studies are needed to determine the optimal treatment strategy.

## Funding source

This report received no specific grant from any funding agency in the public, commercial, or not-for-profit sector.

## Consent for publication

The patient provided consent for the publication of this report.

## Grant Support

This report received no specific grant from any funding agency in the public, commercial, or not-for-profit sector.

## Declaration of interest

The authors declare no conflicts of interest associated with this manuscript.

**Acknowledgments:** We would like to thank Editage for English language editing.

## References

1. Tan ZG, Zhou Q, Cui Y, et al. Extra-axial isolated cerebral varix misdiagnosed as convexity meningioma: a case report and review of literatures. *Medicine (Baltimore)* 2016;95:e4047.
2. Ozturk M, Aslan S, Ceyhan Bilgici M, et al. Spontaneous thrombosis of a giant cerebral varix in a pediatric patient. *Childs Nerv Syst* 2017;33:2193-2195.
3. Kamo H, Ueno Y, Sugiyama M, et al. Temporal profile of CT and T2\*-weighted gradient-echo MRI in a patient with unilateral thalamostriate vein thrombosis. *J Stroke Cerebrovasc Dis* 2019;28:389-391.
4. Inoue T, Shima A, Hirai H, et al. Trigeminal neuralgia due to an isolated cerebral varix: Case report. *J Neurol Surg Rep* 2014;75:e206-e209.
5. Kim HS, Park SC, Ha EJ, et al. Clinical outcome of nonfistulous cerebral varices: The analysis of 39 lesions. *J Korean Neurosurg Soc* 2018;61:485-493.
6. Gomez DF, Mejia JA, Murcia DJ, et al. Isolated giant cerebral varix - A diagnostic and therapeutic challenge: A case report. *Surg Neurol Int* 2016;7:S156-S159.
7. Piazza G. Cerebral venous thrombosis. *Circulation* 2012;125:1704-1709.
8. Roda JM, Bencosme J, Isla A, et al. Intraventricular varix causing hemorrhage. Case report. *J Neurosurg* 1988;68:472-473.
9. Byrne JV. Cranial venous anatomy. *Tutorials in endovascular neurosurgery and interventional neuroradiology*. Cham: Springer; 2017. p. 57-75.
10. Kondo T, Mori Y, Kida Y, et al. Isolated cerebral varix developing sudden deterioration of neurological status because of thrombosis: A case report. *Surg Neurol* 2004;62:76-78. discussion 8-9.