













## ARTICLE



# Novel *CLTC* variants cause new brain and kidney phenotypes

Toshiyuki Itai <sup>1</sup>, Satoko Miyatake <sup>1,2</sup>, Naomi Tsuchida <sup>1,3</sup>, Ken Saida <sup>1</sup>, Sho Narahara<sup>4</sup>, Yu Tsuyusaki <sup>5</sup>,  
Matheus Augusto Araujo Castro <sup>6</sup>, Chong Ae Kim <sup>6</sup>, Nobuhiko Okamoto <sup>7</sup>, Yuri Uchiyama <sup>1,3</sup>, Eriko Koshimizu<sup>1</sup>,  
Kohei Hamanaka <sup>1</sup>, Atsushi Fujita<sup>1</sup>, Takeshi Mizuguchi <sup>1</sup> and Naomichi Matsumoto <sup>1</sup>✉

© The Author(s), under exclusive licence to The Japan Society of Human Genetics 2021

Heterozygous variants in *CLTC*, which encode the clathrin heavy chain protein, cause neurodevelopmental delay of varying severity, and often accompanied by dysmorphic features, seizures, hypotonia, and ataxia. To date, 28 affected individuals with *CLTC* variants have been reported, although their phenotypes have not been fully elucidated. Here, we report three novel de novo *CLTC* (NM\_001288653.1) variants in three individuals with previously unreported clinical symptoms: c.3662\_3664del:p.(Leu1221del) in individual 1, c.2878T>C:p.(Trp960Arg) in individual 2, and c.2430+1G>T:p.(Glu769\_Lys810del) in individual 3. Consistent with previous reports, individuals with missense or small in-frame variants were more severely affected. Unreported symptoms included a brain defect (cystic lesions along the lateral ventricles of the brain in individuals 1 and 3), kidney findings (high-echogenic kidneys in individual 1 and agenesis of the left kidney and right vesicoureteral reflux in individual 3), respiratory abnormality (recurrent pneumonia in individual 1), and abnormal hematological findings (anemia in individual 1 and pancytopenia in individual 3). Of note, individual 1 even exhibited prenatal abnormality (fetal growth restriction, cystic brain lesions, high-echogenic kidneys, and a heart defect), suggesting that *CLTC* variants should be considered when abnormal prenatal findings in multiple organs are detected.

*Journal of Human Genetics*; <https://doi.org/10.1038/s10038-021-00957-3>

## INTRODUCTION

Clathrin is a self-assembling vesicle coat protein involved in multiple processes, including protein sorting, intracellular trafficking, receptor-mediated endocytosis, synaptic vesicle recycling, and interactions with the actin/tubulin cytoskeleton. Clathrin coat is composed of triskelions (three-legged structure) of clathrin heavy chains (CHCs). In humans and most other vertebrates, there are two types of CHC, namely CHC17 and CHC22 [1–3]. *CLTC* (NM\_001288653.1, MIM 118955) encodes CHC17 (alternative name: CHC1), which is expressed ubiquitously and highly intolerant to both missense and null variants [2, 4]. Several clinical whole exome sequencing studies have suggested that heterozygous pathogenic *CLTC* variants result in a range of neurodevelopmental disorders, with possibly full penetrance (MIM 617854), although its underlying pathophysiology remains unclear [5–8].

To date, 28 individuals with *CLTC* variants have been reported, exhibiting a wide variety of clinical symptoms and severities [5–13]. All of these individuals had motor and/or intellectual developmental delays. Major symptoms included behavioral abnormalities (e.g., attention deficit hyperactivity disorder and autistic features), hypotonia, and noncharacteristic dysmorphic features (e.g., long face, midface hypoplasia, and various dental abnormalities). Other less common complications included epilepsy, ophthalmologic features, such as strabismus and gastrointestinal abnormalities (e.g., feeding difficulties and

gastrointestinal reflux) [5, 6]. Some rare complications were also reported (e.g., cerebral hemorrhage, mediastinal neuroblastoma [7], and parkinsonism [8]). Regarding genotype–phenotype correlations, missense/in-frame variants in *CLTC* tend to result in more severe phenotypes than loss-of-function variants [5–8]. Nonetheless, the clinical consequences of *CLTC* variants have not been fully uncovered, such as information on relatively uncommon complications and long-term prognosis.

Here, we report three novel de novo *CLTC* variants in three sporadic individuals. Unreported clinical features including prenatal findings are described.

## MATERIALS AND METHODS

### Study participants

Three individuals from three respective families were included in this study. Informed consent was obtained from all guardians of the individuals. Clinical information was obtained from clinical doctors and their medical records. All experimental protocols were approved by the Institutional Review Board of Yokohama City University School of Medicine (Yokohama City, Japan).

### Genetic analysis

Whole exome sequencing was performed as previously described [14]. In brief, genomic DNA obtained from peripheral blood leukocytes using

<sup>1</sup>Department of Human Genetics, Yokohama City University Graduate School of Medicine, Yokohama, Kanagawa, Japan. <sup>2</sup>Clinical Genetics Department, Yokohama City University Hospital, Yokohama, Kanagawa, Japan. <sup>3</sup>Department of Rare Disease Genomics, Yokohama City University Hospital, Yokohama, Kanagawa, Japan. <sup>4</sup>Department of Pediatrics, Anjo Kosei Hospital, Anjo, Aichi, Japan. <sup>5</sup>Division of Neurology, Kanagawa Children's Medical Center, Yokohama, Kanagawa, Japan. <sup>6</sup>Clinical Genetics Unit, Instituto da Criança, Hospital das Clínicas HCFMUSP, Faculdade de Medicina, Universidade de São Paulo, São Paulo, Brazil. <sup>7</sup>Department of Medical Genetics, Osaka Women's and Children's Hospital, Izumi, Japan. ✉email: naomat@yokohama-cu.ac.jp

Received: 21 April 2021 Revised: 12 June 2021 Accepted: 21 June 2021

Published online: 07 July 2021

QuickGene 610L (Wako, Osaka, Japan) was captured using SureSelect Human All Exon V5 or V6 (Agilent Technologies, Santa Clara, CA, USA). Captured libraries were sequenced on an Illumina HiSeq 2500 with 101-bp paired-end reads or an Illumina NovaSeq with 151-bp paired-end reads (Illumina, San Diego, CA, USA). Image analysis and base calling were performed using sequence control software with real-time analysis and CASAVA software (Illumina). Sequence reads were aligned to GRCh37 using Novoalign (<http://www.novocraft.com/>). Local realignments around indels and base quality score recalibration were performed using Picard (<http://picard.sourceforge.net/>) and the Genome Analysis Toolkit (GATK; <https://www.broadinstitute.org/gatk/index.php>). Variants were called by GATK UnifiedGenotyper and filtered according to GATK Best Practices V3 (<https://software.broadinstitute.org/gatk/>). Included variants were annotated using ANNOVAR software (<http://annovar.openbioinformatics.org/>) after excluding common variants registered in the common dbSNP135 data (minor allele frequency > 0.01). Detected variants were confirmed by Sanger sequencing. To evaluate the effect of a splice site variant c.2430+1G>T in individual 3, reverse transcription polymerase chain reaction was performed using the individual's lymphoblastoid cell line.

## RESULTS

### Genetic analysis

Trio-based whole exome sequencing identified three novel *CLTC* variants occurring de novo in three families (Table 1). All individuals are sporadic cases (Fig. 1a, b). None of the identified variants were registered in public control databases including gnomAD (<https://gnomad.broadinstitute.org/>).

There are two non-truncating variants (missense and in-frame) and one canonical splice site variant: c.3662\_3664del:p.(Leu1221del) in individual 1, c.2878T>C:p.(Trp960Arg) in individual 2, and c.2430+1G>T in individual 3. The former two variants are found at amino acids that are highly conserved through vertebrates (Fig. 1c). The c.2430+1G>T variant is located at the splice donor site of intron 15 of 31, resulting in exon 15 skipping and an in-frame 42 amino acid deletion (Fig. 1d, Supplementary Fig. 1). The c.3662\_3664del:p.(Leu1221del) is located in the proximal leg region (Fig. 1e). Near this variant, a de novo in-frame deletion, p.(Asp1211del), was identified from an individual with developmental and epileptic encephalopathy [6]. The c.2878T>C:p.(Trp960Arg) missense variant in the distal leg region (Fig. 1e) is predicted to be disease-causing by multiple in silico tools (SIFT, 0; PolyPhen2 HDIV/HVAR, 0.999/0.999; MutationTaster score/prediction, 1/disease causing; and CADD phred, 29.8). The c.2430+1G>T:p.(Glu769\_Lys810del) variant occurred within the ankle domain.

### Clinical studies

Individual 1 was a 2-year- and 3-month-old girl born to healthy Japanese parents with no remarkable family history (Fig. 2a, b). She and her brother were a pair of dichorionic diamniotic twins. From 18 weeks of gestation, she had been diagnosed with fetal growth restriction. At 26 weeks of gestation, ultrasonography revealed a suspected atrioventricular septal defect, right lateral ventriculomegaly, and multiple cystic lesions along the left lateral ventricle of the brain. Since 30 weeks of gestation, her growth was severely delayed. At 33 weeks of gestation, fetal magnetic resonance imaging (MRI) was performed, confirming the brain abnormality (multiple cysts) as well as abnormal lesions in bilateral kidneys (Fig. 2e–g). At 34 weeks and 1 day of gestation, she was delivered by cesarean section because of a non-reassuring fetal status. Her birth weight was 968 g (−3.85 SD), length was 33.5 cm (−3.7 SD), and head circumference was 25.8 cm (−2.8 SD). Soon after birth, and because of her immaturity, she had transient tachypnea that required mechanical ventilation until day 26. Furthermore, anemia (Hb 10.2 g/dL, mean corpuscular volume 83.9 fL, and ferritin 372 µg/L), probably due to her immaturity, was observed on day 3, and she received erythropoietin and subsequent red blood cell transfusion. She was diagnosed with multiple cystic lesions along bilateral ventricles in the brain (Fig. 2h), an atrial septal defect, and enlargement of the ascending

aorta and pulmonary trunk. Bilateral high-echogenic kidneys were also identified but with no oliguria, proteinuria, hematuria, or hypertension. She suffered from meconium ileus, which were treated by a gastrografin enema. At the age of 5 weeks, she started to frequently exhibit segmental myoclonus. At the age of 2 months, she exhibited a cluster of focal behavior arrest seizures (Fig. 3a) and received phenobarbital. The seizures became well-controlled by 4 months of age. At 7 months of age, she had a series of epileptic spasms with a diagnosis of West syndrome (Fig. 3b), which were controlled using valproate. At the age of 10 months, she had repeated respiratory infections, including possible aspiration pneumonia and human metapneumovirus infection, which subsequently led to respiratory failures that required mechanical ventilation several times. During the infections, she suffered from anemia (Hb 9.1 g/dL and mean corpuscular volume 82.0 fL) and underwent red blood cell transfusion. After the recurrent respiratory infections, she began nasal tube feeding. She has never received red blood cell transfusion afterward. At the age of 1 year and 2 months, she had a surgical repair of the atrial septal defect, and a left superior vena cava remnant and bicuspid aortic valve were also noted. The high echogenicity in bilateral kidneys had disappeared. After discharge from hospital, she was administered high-flow nasal cannula oxygen therapy and medications for diuretic and pulmonary hypertension. Afterwards, she stopped phenobarbital and valproate because of adverse effects, pulmonary hypertension, and low platelets, respectively. At the age of 2 years and 1 month, she had another cluster of focal behavior arrest seizures and started taking levetiracetam. At the age of 2 years and 3 months, her developmental milestones have been severely delayed. She has not gained eye-tracking or head control; she could not speak any meaningful words or even communicate nonverbally.

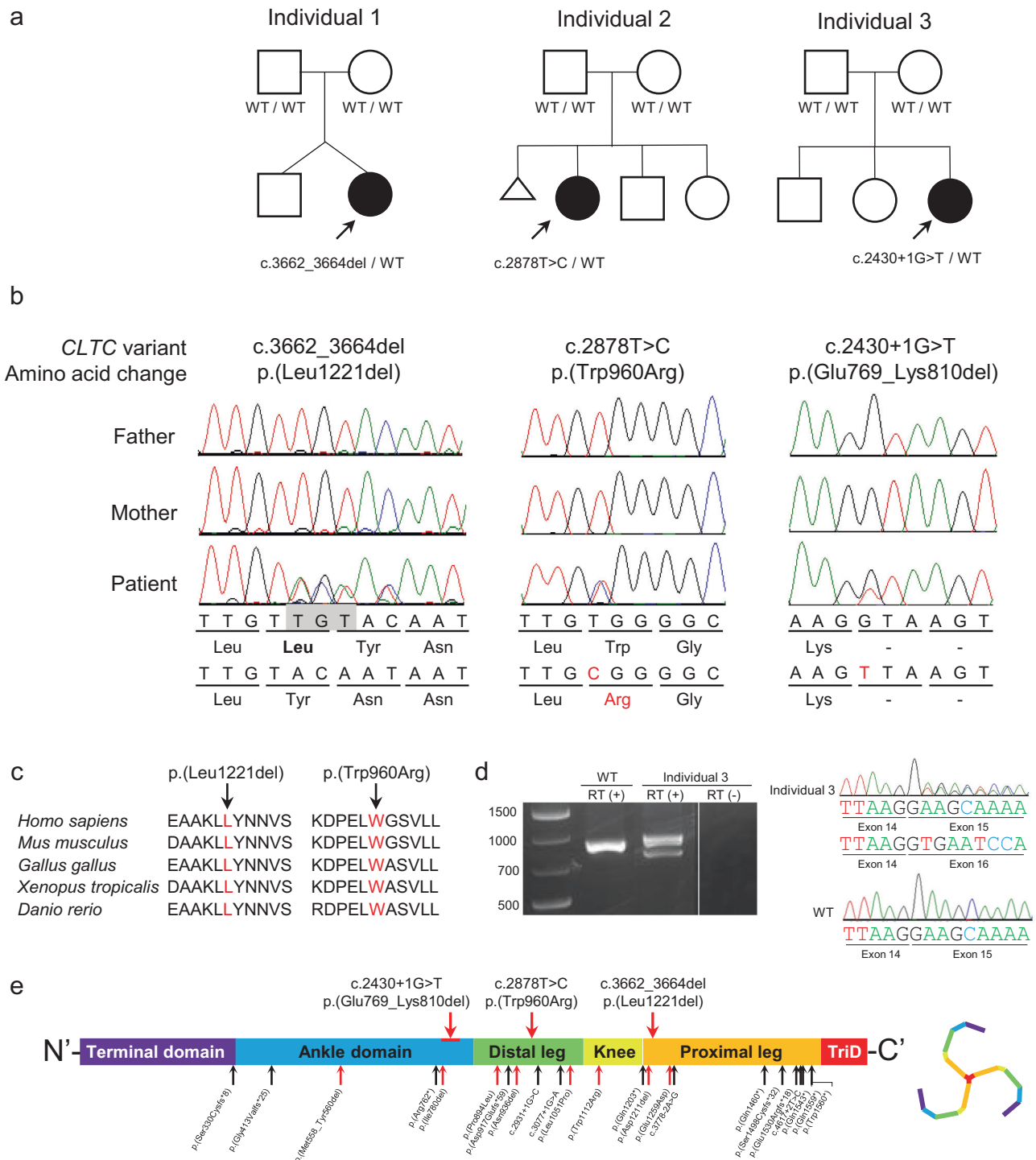
Individual 2 is an 8-year- and 5-month-old girl, the first child to healthy Japanese parents. There were no prenatal problems. At 41 weeks and 1 day of gestation, she was vaginally delivered: her birth weight was 2444 g (−2.19 SD), length was 45 cm (−2.73 SD), and head circumference was 30 cm (−2.86 SD). Six hours after birth, she presented with frequent apnea, horizontal nystagmus, subtle seizures of gagging, and clonic convulsions of the upper limbs, and was admitted to a neonatal intensive care unit. The seizures were alleviated under phenobarbital treatment but recurred at 6 days after birth. Increased dosage of phenobarbital was effective and enabled her to be discharged from hospital. At the age of 5 months, she was referred to a tertiary medical center for a thorough evaluation. Upon examination, she made no eye contact, presented with microcephaly (but with no precise record), had characteristic facial features (epicanthus, a coarse face, and flat nasal bridge), syndactyly of the third and fourth fingers, and generalized weak muscular tonus with trunk dominance. She had abnormal behavior with raising hands and shrieking. An interictal EEG did not show any obvious abnormal wave patterns. Brain MRI showed periventricular cysts, hypoplasia of the corpus callosum, hyperintensities along bilateral lateral ventricles, and volume loss of the white matter (Fig. 2i, j). Phenobarbital was stopped at the age of 9 months. At around 10 months, seizures started with a few seconds of eye-rolling and twitching of the limbs. EEG showed spikes and spike-and-wave complexes in the left frontal and posterior temporal regions, and spikes and waves spreading throughout the right hemisphere (Fig. 3c, d). She was diagnosed with focal seizures and myoclonic seizures. Her epilepsy was refractory and treated with lamotrigine, levetiracetam, and clobazam. After the addition of clobazam, her seizures decreased significantly. She had no seizures at all for about 2 years, but from the age of 7 years, she exhibited myoclonic seizures once or twice a week. She spoke no meaningful words with no verbal communication. Her developmental milestones have been severely delayed with no head control. Microarray test was negative.

**Table 1.** Clinical information of the three individuals harboring *CLTC* variants

Clinical information	Individual 1	Individual 2	Individual 3
Inheritance	De novo	De novo	De novo
Nucleotide change (NM_001288653.1)	c.3662_3664del	c.2878T>C	c.2430+1G>T
Amino acid change	p.(Leu1221del)	p.(Trp960Arg)	p.(Glu769_Lys810del)
Sex	Female	Female	Female
Age at onset	Prenatal	At birth	3 months
Age at examination	3 months	3 years and 8 months	15 years
Current age	2 years and 3 months	8 years and 5 months	18 years
Initial symptoms	Fetal growth restriction	Seizure	Developmental delay
Developmental milestones			
Eye tracking	Not acquired	Not acquired	8 months
Social smile	Not acquired	Not acquired	5 months
Use of a single meaningful word	Not acquired	Not acquired	3 years
Two-word sentence	Not acquired	Not acquired	4 years
Head control	Not acquired	Not acquired	8 months
Rolling over	Not acquired	Not acquired	Unavailable
Crawling	Not acquired	Not acquired	1 year
Sitting independently	Not acquired	Not acquired	2 years
Walking without assistance	Not acquired	Not acquired	2 years and 5 months
Intellectual disability	Severe	Severe	Moderate
Epilepsy	Focal epilepsy, West syndrome	Partial seizures, myoclonic seizures	Generalized tonic-clonic seizures
Dysmorphology	Mildly asymmetric face, thick eyebrows, epicanthus, low-set ears, down-turned corners of the mouth, microcephaly, brachycephaly	Epicanthus, flat nasal root, right 3rd and 4th digit syndactyly, pinky toe inflection, microcephaly	Microcephaly, mildly asymmetric face, thick eyebrows, epicanthus, long philtrum, maxillar protrusion, micrognathia, dental malocclusion
Craniofacial/Neck features	None	Otitis media	Left convergent strabismus, palpebral telangiectasias
Cardiac defects	Atrial septal defect, enlargement of ascending aorta and pulmonary artery	None	None
Abdominal/Pelvic features	High-echogenic kidneys	None	Agenesis of the left kidney, right vesicoureteral reflux, small bladder with reduced compliance, bladder sphincter dyssynergia
Motor/Neurological findings	Segmental myoclonus	Abnormal muscular tonus, stereotyped movement (hand-flapping)	Ataxia
Other symptoms	Anemia	None	Pancytopenia

Individual 3 was a 18-year-old Brazilian woman, the third child to non-consanguineous parents (Fig. 2c, d). She was born normally at 40 weeks of gestation with a weight of 2150 g (−3.04 SD), length of 44.5 cm (−2.61 SD), and occipital-frontal circumference (OFC) of 30.5 cm (−3.05 SD). She presented with global developmental delay (Table 1), but no regression. At 1 year and 5 months, she presented with generalized tonic-clonic seizures. She was referred to a pediatric neurology department and received valproate. Neurological examination detected ataxia. EEG showed paroxysmal spikes, sharp waves, and slow irregular waves of multifocal projections with predominance in bilateral anterior regions. At 2 years and 6 months, she had her last seizure, and valproate treatment was stopped for 3 years. She was referred to our clinical genetics service at the age of 3 years and 5 months. Physical examination showed normal weight (14.0 kg, −0.45 SD) and height (101.5 cm, +1.02 SD), but microcephaly (OFC of 45 cm, −2.5 SD) and dysmorphic features. Left convergent strabismus

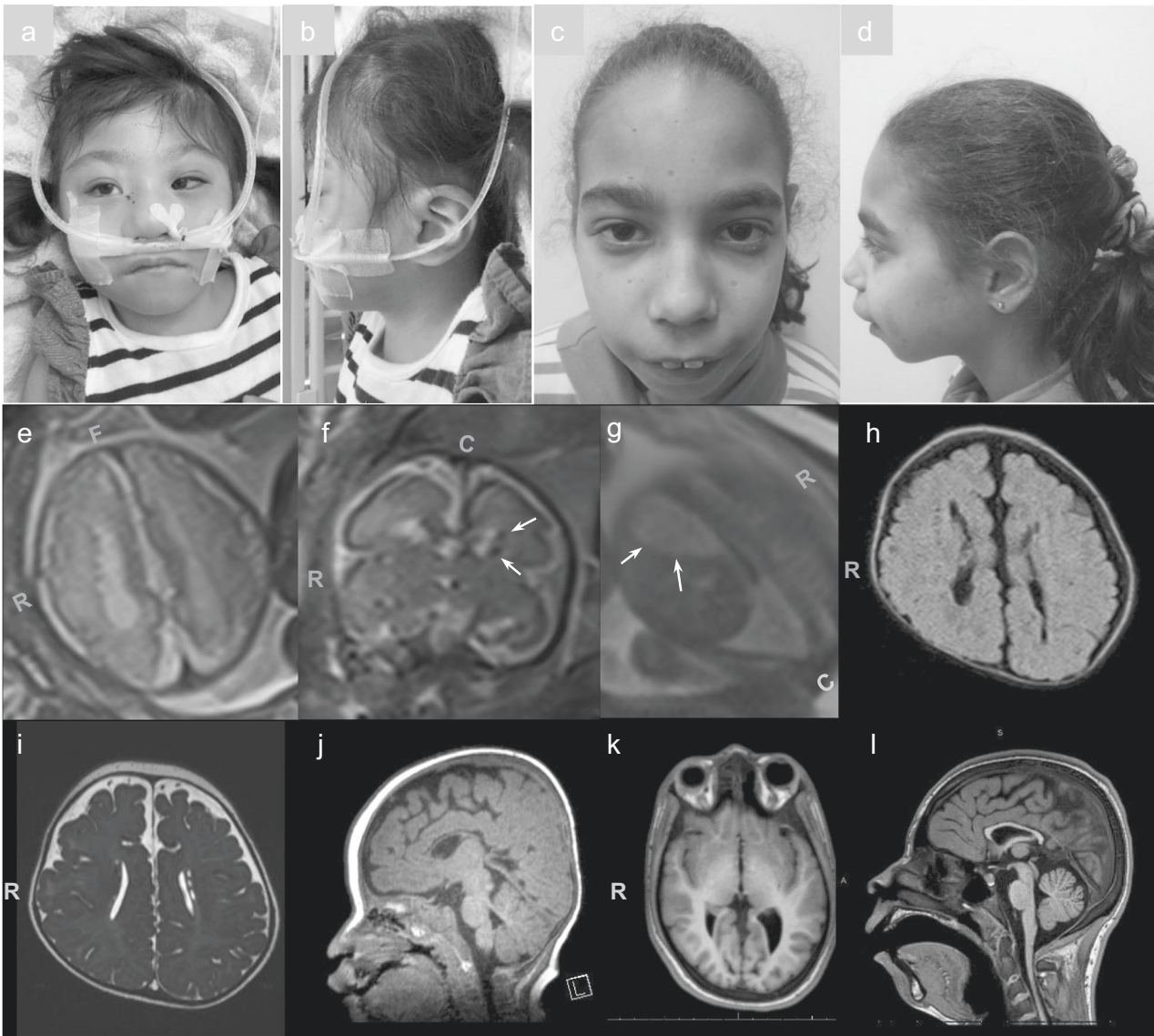
was recognized. Echocardiogram was normal. Ultrasonography revealed splenomegaly and a retroperitoneal cystic image in the left kidney topography which was suspected of a polycystic kidney at 5 and 6 years. However, the serial follow-up ultrasonographic examinations could not find the cystic finding or even the left kidney itself, finally diagnosed it as agenesis of the left kidney. In all studies, the right kidney was normal. Urodynamic testing showed grade II vesicoureteral reflux on the right side, a small bladder with reduced compliance, and bladder sphincter dyssynergia. Computed tomography scan confirmed no spine abnormality. G-banded karyotype was 46XX, and microarray test was normal. At 11 years, she was referred to the hospital because of mild non-progressive pancytopenia. Myelodysplastic syndrome was suspected based on a normal diepoxybutane test. Bone marrow biopsy identified small megakaryocytes, increased blast cells (CD34+), and a grade 2 reticulin staining. At the age of 13 years, brain MRI showed a thin corpus callosum and asymmetry of



**Fig. 1** Genetic analysis of three individuals harboring *CLTC* variants. **a** Familial pedigrees and *CLTC* variants. **b** Electropherograms of the variants. In individual 1, deleted nucleotides are highlighted in the gray box, and a deleted amino acid is shown in bold. In individuals 2 and 3, altered nucleotides and an amino acid are shown in red. **c** Evolutional conservation of amino acids harboring variants within vertebrates. **d** Agarose gel electrophoresis (left) of RT-PCR products shows an aberrant band in individual 3 arising from pathogenic exon 15 skipping (electropherograms, right). **e** Schematic presentation of *CLTC* functional domains and variants (left) and its triskelion structure (right). Variants identified in this study and previously reported variants are displayed above and below the *CLTC* protein, respectively. Missense/in-frame variants are shown in red arrows, and loss-of-function variants, and canonical and splice site variants without functional validation in black. RT (+) with reverse transcriptase, RT (-) without reverse transcriptase as a negative control, TriD trimerization domain, WT wild-type

the lateral ventricles (Fig. 2k, l). At 15 years of age, her bone age was normal despite scoliosis and accentuated thoracic kyphosis and lumbar lordosis, shortening of the right ulna, and cubitus valgus. At the age of 18 years, she could not read or write and was

dependent on others for certain daily activities. Her height was normal (160 cm), but microcephaly (OFC of 51.8 cm, -2.4 SD), a low BMI (16.9), and joint hypermobility (Beighton score of 6) were observed.



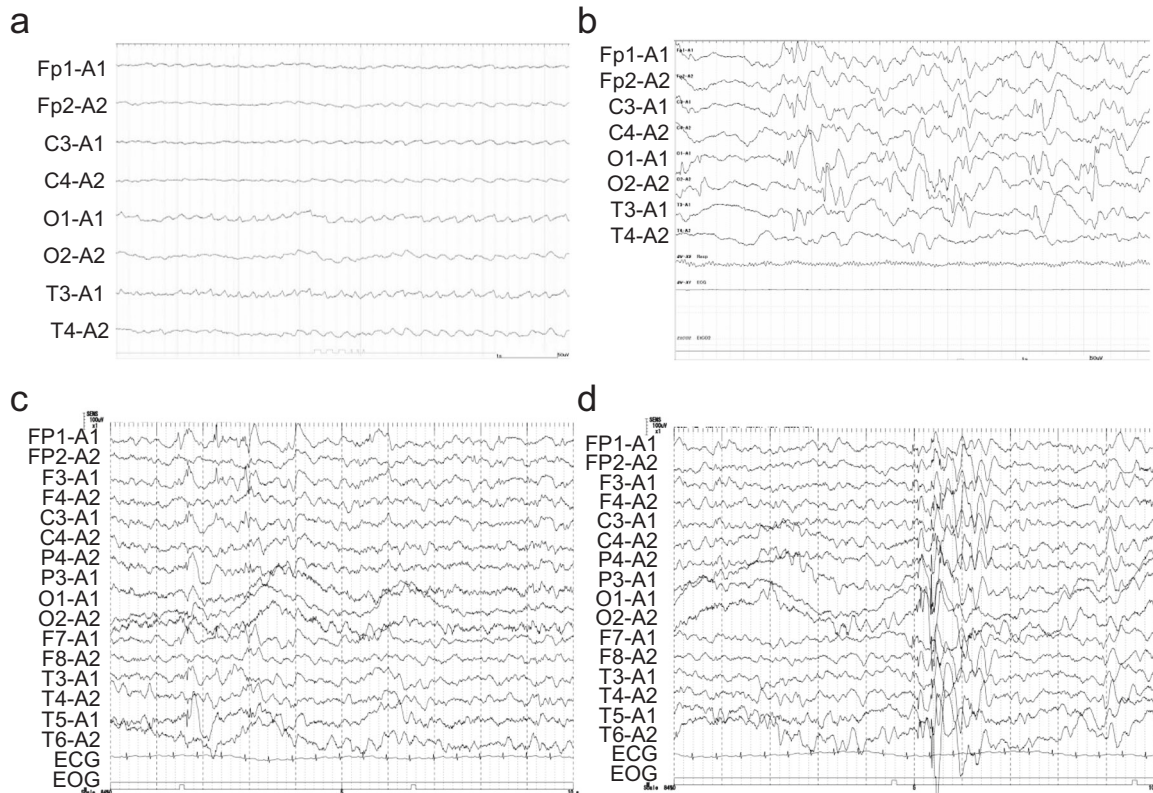
**Fig. 2** Clinical features of individuals. **a, b** Facial photographs of individual 1 at the age of 2 years and 3 months showing a mild asymmetric face, thick eyebrows, epicanthus, low-set ears, down-turned corners of the mouth, microcephaly, and brachycephaly. **c, d** Photographs of individual 3 at the age of 9 years, showing slightly dysmorphic features with a mild asymmetric face, thick eyebrows, epicanthus, long philtrum, maxillary protrusion, micrognathia, and dental malocclusion. **e–g** Fetal magnetic resonance imaging (MRI) images in individual 1 at 33 weeks of gestation. Half-Fourier single-shot turbo spin echo MRI shows bilateral ventriculomegaly (**e**) and cystic brain defects along the left lateral ventricle (arrows, **f**). True fast imaging with steady-state free precession MRI showing an abnormal high-intensity signal in the left kidney (arrows, **g**). **h** Fluid-attenuated inversion recovery MRI in individual 1 at 4 months shows multicystic brain defects in the white matter along the bilateral ventricles in individual 1. **i** Constructive interference in steady-state MRI at the age of 5 months shows bilateral periventricular cysts in individual 2. **j** T1-weighted MRI at the age of 5 months shows thinning of the corpus callosum in individual 2. T1-weighted MRI in individual 3 at the age of 13 years and 10 months shows the left ventriculomegaly (**k**) and mild thinning of the corpus callosum (**l**). Gray-colored C, F, and R denotes cranial, front, and right orientations

## DISCUSSION

We have identified novel heterozygous *CLTC* variants occurring de novo in three individuals with neurodevelopmental disorder. The three individuals showed common features, such as noncharacteristic dysmorphic features and developmental delay, as previously reported with *CLTC* variants [5, 6], but unrecognized symptoms were observed in the brain, kidneys, and blood system, which expands the phenotypic spectrum of *CLTC* variants. *CLTC* internalizes polycystin-1 (which is associated with polycystic kidney disease) and neurogenic locus notch homolog protein 3 (which is related to cerebral arteriopathy) [15, 16].

Consistent with previous reports [5–8], all identified variants occurred de novo. The *CLTC* protein consists of six functional

domains. The variants identified in this study and previous reports are displayed in Fig. 1d: 11 missense/in-frame variants, including our 3 identified variants, are scattered through four domains not including the terminal domain or trimerization domain [5–13]. Structural consideration suggests that the variants may affect interactions with other CHCs or a clathrin light chain, which define the lattice formation of clathrin [5, 17]. Previous reports also suggest that individuals with missense/in-frame variants show more severe phenotypes compared with those with a loss-of-function variant. Consistent with this, individuals with missense/in-frame variants (Individuals 1 and 2) had severe phenotypes. Interestingly, individual 3 showed a relatively milder phenotype with a canonical splice variant resulting in an in-frame deletion of



**Fig. 3** **a, b** Electroencephalograms (EEGs) in individuals 1 and 2. **a** Ictal EEG at 3 months shows sharp waves in the left temporal region in individual 1. **b** Sleep EEG at 7 months shows hypsarrhythmia in individual 1. EEG in individual 2 at 13 months shows spikes, spike-and-wave complexes in the frontal and left posterior temporal regions (**c**) and diffuse high-voltage poly-spikes and waves in the right posterior temporal region predominantly (**d**)

42 amino acids, the longest *CLTC* in-frame deletion ever reported. Considering that loss-of-function *CLTC* variants tend to have milder phenotypes, its pathogenesis may involve protein instability or unknown pathomechanisms.

Several unreported clinical features were found in our individuals. Individual 1 showed abnormal prenatal ultrasound findings, with fetal growth restriction at 18 weeks of gestation; this is the earliest onset of the initial symptoms reported so far. This patient also had prenatal multisystem anomalies: cystic lesions and ventriculomegaly in the brain, high-echogenic kidneys, and heart defects. High-echogenic kidneys sometimes can be associated with renal dysplasia, polycystic kidneys, and other congenital kidney diseases [18]. There were high-echogenic kidneys in individual 1 and agenesis of the left kidney and right vesicoureteral reflux in individual 3. To our knowledge, this is the first report of urogenital anomalies associated with *CLTC* variants. Congenital anomalies of the kidney and urinary tract (CAKUT) are common causes of renal failure in children [19]. Our results indicate that *CLTC* variants could be one of the genetic causes in CAKUT, and periodic evaluation of the kidneys and urinary tract may be needed for those with *CLTC* variants. Other uncommon features included blood abnormalities (anemia and pancytopenia in individuals 1 and 3, respectively) and recurrent respiratory infections with unknown etiology, but possibly and partly due to dysphagia in individual 1, which could lead to serious health problems.

In conclusion, we report three novel *CLTC* variants occurring de novo in three individuals, thereby expanding the *CLTC*-related phenotypic spectrum. As prenatal and long-term clinical courses have not been fully elucidated, the accumulation of individuals with pathogenic *CLTC* variants is highly anticipated for a better understanding of their clinical consequences.

## REFERENCES

- Briant K, Redlingshofer L, Brodsky FM. Clathrin's life beyond 40: connecting biochemistry with physiology and disease. *Curr Opin Cell Biol.* 2020;65:141–9.
- Brodsky FM. Diversity of clathrin function: new tricks for an old protein. *Annu Rev Cell Dev Biol.* 2012;28:309–36.
- Kasprovicz J, Kuenen S, Miskiewicz K, Habets RL, Smits L, Verstreken P. Inactivation of clathrin heavy chain inhibits synaptic recycling but allows bulk membrane uptake. *J Cell Biol.* 2008;182:1007–16.
- Karczewski KJ, Francioli LC, Tiao G, Cummings BB, Alfoldi J, Wang Q, et al. The mutational constraint spectrum quantified from variation in 141,456 humans. *Nature.* 2020;581:434–43.
- Nabais Sá MJ, Venselaar H, Wiel L, Trimouille A, Lasseaux E, Naudion S, et al. De novo *CLTC* variants are associated with a variable phenotype from mild to severe intellectual disability, microcephaly, hypoplasia of the corpus callosum, and epilepsy. *Genet Med.* 2020;22:797–802.
- Hamdan FF, Myers CT, Cossette P, Lemay P, Spiegelman D, Laporte AD, et al. High rate of recurrent de novo mutations in developmental and epileptic encephalopathies. *Am J Hum Genet.* 2017;101:664–85.
- DeMari J, Mroske C, Tang S, Nimeh J, Miller R, Lebel RR. *CLTC* as a clinically novel gene associated with multiple malformations and developmental delay. *Am J Med Genet Part A.* 2016;170A:958–66.
- Manti F, Nardecchia F, Barresi S, Venditti M, Pizzi S, Hamdan FF, et al. Neurotransmitter trafficking defect in a patient with clathrin (*CLTC*) variation presenting with intellectual disability and early-onset parkinsonism. *Parkinsonism Relat Disord.* 2019;61:207–10.
- Schmitz-Abe K, Li Q, Rosen SM, Nori N, Madden JA, Genetti CA, et al. Unique bioinformatic approach and comprehensive reanalysis improve diagnostic yield of clinical exomes. *Eur J Hum Genet.* 2019;27:1398–405.
- Lecoquierre F, Duffourd Y, Vitobello A, Bruel AL, Urteaga B, Coubes C, et al. Variant recurrence in neurodevelopmental disorders: the use of publicly available genomic data identifies clinically relevant pathogenic missense variants. *Genet Med.* 2019;21:2504–11.
- Bruel AL, Nambot S, Quere V, Vitobello A, Thevenon J, Assoum M, et al. Increased diagnostic and new genes identification outcome using research reanalysis of singleton exome sequencing. *Eur J Hum Genet.* 2019;27:1519–31.

12. Lelieveld SH, Reijnders MR, Pfundt R, Yntema HG, Kamsteeg EJ, de Vries P, et al. Meta-analysis of 2,104 trios provides support for 10 new genes for intellectual disability. *Nat Neurosci*. 2016;19:1194–6.
13. Helbig KL, Farwell Hagman KD, Shinde DN, Mroske C, Powis Z, Li S, et al. Diagnostic exome sequencing provides a molecular diagnosis for a significant proportion of patients with epilepsy. *Genet Med*. 2016;18:898–905.
14. Aoi H, Mizuguchi T, Suzuki T, Makino S, Yamamoto Y, Takeda J, et al. Whole exome sequencing of fetal structural anomalies detected by ultrasonography. *J Hum Genet*. 2021;66:499–507.
15. Hosseini-Alghaderi S, Baron M. Notch3 in development, health and disease. *Biomolecules*. 2020;10:485.
16. Xu Y, Streets AJ, Hounslow AM, Tran U, Jean-Alphonse F, Needham AJ, et al. The polycystin-1, lipoxigenase, and  $\alpha$ -toxin domain regulates polycystin-1 trafficking. *J Am Soc Nephrol*. 2016;27:1159–73.
17. Wilbur JD, Hwang PK, Ybe JA, Lane M, Sellers BD, Jacobson MP, et al. Conformation switching of clathrin light chain regulates clathrin lattice assembly. *Dev Cell*. 2010;18:841–8.
18. Digby EL, Liauw J, Dionne J, Langlois S, Nikkel SM. Etiologies and outcomes of prenatally diagnosed hyperechogenic kidneys. *Prenat Diagn*. 2021;41:465–77.
19. Harambat J, van Stralen KJ, Kim JJ, Tizard EJ. Epidemiology of chronic kidney disease in children. *Pediatr Nephrol*. 2012;27:363–73.

## ACKNOWLEDGEMENTS

We thank all the participants in this study. We are grateful to Ms. M. Satoh, Mr. T. Miyama, Ms. K. Takabe, Ms. N. Watanabe, and Ms. S. Sugimoto from the Department of Human Genetics, Yokohama City University Graduate School of

Medicine for their technical assistance. This work was supported by the Agency for Medical Research and Development (AMED) under grant numbers JP21ek0109486, JP21ek0109549, JP21cm0106503, and JP21ek0109493 (NM); Japan Society for the Promotion of Science (JSPS) KAKENHI under grant numbers, JP20K07907 (SM), JP20K08164 (TM), JP20K17936 (AF), JP20K16932 (KH), JP19K17865 (YU), and JP20K17428 (NT); and the Takeda Science Foundation (TM and NM). We thank Rachel James, Ph.D., from Edanz Group (<https://en-author-services.edanz.com/ac>) for editing a draft of this manuscript.

## CONFLICT OF INTEREST

The authors declare no competing interests.

## ADDITIONAL INFORMATION

**Supplementary information** The online version contains supplementary material available at <https://doi.org/10.1038/s10038-021-00957-3>.

**Correspondence** and requests for materials should be addressed to N.M.

**Reprints and permission information** is available at <http://www.nature.com/reprints>

**Publisher's note** Springer Nature remains neutral with regard to jurisdictional claims in published maps and institutional affiliations.