

## Volume 208

September 2021

⬇️ Download full issue

[< Previous vol/issue](#)

[Next vol/issue >](#)

Receive an update when the latest issues in this journal are published

[🔔 Sign in to set up alerts](#)

● Full text access

### Editorial Board

Article 106927

⬇️ [Download PDF](#)

### Reviews

---

Review article ● Full text access

### Progressive encephalomyelitis with rigidity: A Taiwanese case and review of literature

Anna Chang, Kuan-yu Lin, Kai-Ju Chuang, Patrick Waters, ... Wei-Hung Chen

Article 106807

⬇️ [Download PDF](#)    [Article preview](#) [▼](#)

Review article ● Full text access

### Chronic subdural hematoma-induced parkinsonism: A systematic review

---



## review

Stefania Kalampokini, Artemios Artemiadis, Panagiotis Zis, Linos Hadjihannas, ... Georgios M. Hadjigeorgiou  
Article 106811

[Download PDF](#) Article preview [▼](#)

Review article ● Full text access

Possible inflammatory mechanisms and predictors of Parkinson's disease patients with fatigue (Brief Review)

Haili Wang, Yimin Liu, Jingyi Zhao, Xin Guo, ... Yingzhu Chen  
Article 106844

[Download PDF](#) Article preview [▼](#)

Review article ● Full text access

Whole-exome sequencing and human leukocyte antigen analysis in familial myasthenia gravis with thymoma:  
Case report and literature review

Yoshitsugu Nakamura, Hidenori Sato, Yuki Miyano, Ryoko Murakami, ... Shigeki Arawaka  
Article 106864

[Download PDF](#) Article preview [▼](#)

Review article ● Full text access

The contributions of William A. Hammond (1828–1900) to Civil War medicine & modern neurology

Cara Lescott, Fareed Jumah, Bharath Raju, Gaurav Gupta, Anil Nanda  
Article 106867

[Download PDF](#) Article preview [▼](#)

## Original articles

Research article ● Full text access

Primary visual cortex of the brain is associated with optic nerve head changes in neuromyelitis optica spectrum disorders

Qingkai Ma, Xiao Wu, Jianfei Pan, Quanwei Zhu, Xiang Mao  
Article 106822

[Download PDF](#) Article preview [▼](#)

Research article ● *Open access*

Angioplasty alone versus acute stenting for acute tandem occlusions due to internal carotid artery atherosclerotic

Wei Li, Chenhao Zhao, Min Zhang, Shu Yang, ... Zhibin Chen



Rie Yamawaki, Manabu Nankaku, Chinatsu Umaba, Masaya Ueda, ... Yoshiki Arakawa

Article 106824

[Download PDF](#) Article preview [▼](#)

Research article ● Full text access

Deep brain stimulation in patients with long history of drug resistant epilepsy and poor functional status: Outcomes based on the different targets

C. Passamonti, F. Mancini, E. Cesaroni, S. Bonifazi, ... R.A. Ricciuti

Article 106827

[Download PDF](#) Article preview [▼](#)

Research article ● Full text access

Cognitive recovery in people with relapsing/remitting multiple sclerosis: A randomized clinical trial on virtual reality-based neurorehabilitation

Simona Leonardi, Maria Grazia Maggio, Margherita Russo, Alessia Bramanti, ... Rosaria De Luca

Article 106828

[Download PDF](#) Article preview [▼](#)

Research article ● Full text access

Can dogs and cats really help our spinal cord stimulation patients?

Michelle Williams, Eleni N. Varelas, Zachary T. Olmsted, Breanna L. Sheldon, ... Julie G. Pilitsis

Article 106831

[Download PDF](#) Article preview [▼](#)

Research article ● Full text access

MYC, BCL2, and BCL6 expression as prognostic indicators in primary central nervous system lymphoma: A systematic review and meta-analysis

Le Ge, Shan Lu, Lixia Xu, Hua Yan

Article 106838

[Download PDF](#) Article preview [▼](#)

Research article ● Full text access

Diminishing returns with successive device passes in mechanical thrombectomy for stroke

Jennifer A. Kosty, Christopher P. Carroll, Sandeep Kandregula, Zachary Plummer, ... Andrew J. Ringer

Article 106780

[Download PDF](#) Article preview [▼](#)



 Download PDF  Article preview 

Research article  Full text access

## How neuropsychiatric comorbidity, modulatory indication, demographics, and other factors impact deep brain stimulation inpatient outcomes in the United States: A population-based study of 27,956 patients

Michael W. Kortz, Brian M. Kongs, Edwin McCray, Fabio Grassia, ... Steven G. Ojemann

Article 106842

 [Download PDF](#) Article preview 

Research article  Full text access

## Clinical outcomes for patients with lateral lumbar radiculopathy treated by percutaneous endoscopic transforaminal discectomy versus tubular microdiscectomy: A retrospective review

Guilherme B.F. Porto, Sarah E. Cisewski, Laura Wolgamott, Bruce M. Frankel

Article 106848

 [Download PDF](#) Article preview 

Research article  Full text access

## Age at sampling and sex distribution of AChRAb vs. MuSKAb myasthenia gravis in a large Greek population

Maria Belimezi, Antonios Kalliaropoulos, Juan Jiménez, Irene Garcia, ... George P. Chrousos

Article 106847

 [Download PDF](#) Article preview 

Research article  Full text access

## Frequency of actionable molecular drivers in lung cancer patients with precocious brain metastases

Benjamin Hanke, Stephanie T. Jünger, Elmar Kirches, Natalie Waldt, ... Christian Mawrin

Article 106841

 [Download PDF](#) Article preview 

Research article  Full text access

## Rapidly progressive dementia and Parkinsonism as the first symptoms of dural arteriovenous fistula. The Sapienza University experience and comprehensive literature review concerning the clinical course of 102 patients

Daniele Armocida, Mauro Palmieri, Francesco Paglia, Luigi Valentino Berra, ... Antonio Santoro

Article 106835

 [Download PDF](#) Article preview 



Research article ● Full text access

## A Chinese CADASIL family with p.R578C mutation at exon 11 of the NOTCH3 gene

XuLing Wu, AnNi Zhang, Ya Li, XiaoYang Lei, ... Dian He

Article 106833

[Download PDF](#) Article preview [▼](#)

Research article ● Full text access

## Daytime sleepiness and risk of stroke: A Mendelian randomization analysis

Yazhou Ma, Mengmeng Wang, Xin Chen, Wang Ruan, ... Xuegan Lian

Article 106857

[Download PDF](#) Article preview [▼](#)

Research article ● Full text access

## King's Parkinson's Disease Pain Scale (KPPS): Cross-cultural adaptation to Brazilian Portuguese and content validity

Márcia Regina Coimbra, Camila Megale Almeida-Leite, Iza de Faria-Fortini, Paulo Pereira Christo, Paula Luciana Scalzo

Article 106815

[Download PDF](#) Article preview [▼](#)

Research article ● Full text access

## Contribution of factor VII polymorphisms to coagulopathy in patients with isolated traumatic brain injury

Jiang Fang, Qiang Yuan, Zhuoying Du, Chaobo Liu, ... Xing Wu

Article 106836

[Download PDF](#) Article preview [▼](#)

Research article ● Full text access

## Blind exchange technique to facilitate large-bore aspiration catheter navigation during stroke thrombectomy

Alhamza R. Al-Bayati, Diogo C. Haussen, Mahmoud H. Mohammaden, Leonardo Pisani, ... Raul G. Nogueira

Article 106873

[Download PDF](#) Article preview [▼](#)

Research article ● Full text access

## The risks factor of recurrence after skull base hemangiopericytoma management: A retrospective case series and review of literature

Subhas Konar, Mini Jayan, Dhaval Shukla, Dhanjaya I. Bhat, ... B. Indira Devi



Xiaofan Yu, Liang Wu, Yunwei Ou, Long Xu, ... Weiming Liu

Article 106817

[Download PDF](#) Article preview [▼](#)

Research article ● Full text access

## Bilateral epileptogenesis in temporal lobe epilepsy due to unilateral hippocampal sclerosis: A case series

Addolorata Mascia, Sara Casciato, Marco De Risi, Pier Paolo Quarato, ... Giancarlo Di Gennaro

Article 106868

[Download PDF](#) Article preview [▼](#)

Research article ● Full text access

## The outcomes of mechanical thrombectomy in nonagenarians and octogenarians in a majority hispanic population

Nura Salhadar, Mahmoud Dibas, Amrou Sarraj, Wondwossen Tekle, Ameer E. Hassan

Article 106872

[Download PDF](#) Article preview [▼](#)

Research article ● Full text access

## Admission glycemic gap in the assessment of patients with intracerebral hemorrhage

Amber Y. Dorn, Philip Y. Sun, Nerses Sanossian, Peggy L. Nguyen, ... Sebina F. Bulic

Article 106871

[Download PDF](#) Article preview [▼](#)

Research article ● Full text access

## Operative nuances and surgical limits of the endoscopic approach to clival chordomas and chondrosarcomas: A single-center experience of 72 patients

Savas Ceylan, Atakan Emengen, Melih Caklili, Anil Ergen, ... Ihsan Anik

Article 106875

[Download PDF](#) Article preview [▼](#)

Research article ● Full text access

## Impact of preoperative opioid use disorder on outcomes following lumbar-spine surgery

Briana Lui, Roniel Weinberg, Andrew R. Milewski, Xiaoyue Ma, ... Robert S. White

Article 106865

[Download PDF](#) Article preview [▼](#)



Research article ● Full text access

## Polymorphisms of Nav1.6 sodium channel, Brain-derived Neurotrophic Factor, Catechol-O-methyltransferase and Guanosine Triphosphate Cyclohydrolase 1 genes in trigeminal neuralgia

JGAJ Romero, Grazielle Mara Ferreira Costa, Luiz Paulo Carvalho Rocha, SRDT Siqueira, ... Camila Megale Almeida-Leite  
Article 106880

[Download PDF](#) Article preview [▼](#)

Research article ● Open access

## The stability of the metabolic turnover of arachidonic acid in human unruptured intracranial aneurysmal walls is sustained

Ririko Takeda, Ariful Islam, Tomohito Sato, Hiroki Kurita, ... Mitsutoshi Setou  
Article 106881

[Download PDF](#) Article preview [▼](#)

Research article ● Full text access

## Mutation spectrum of the *NF1* gene and genotype–phenotype correlations in Turkish patients: Seventeen novel pathogenic variants

Asli Ece Solmaz, Esra Isik, Tahir Atik, Ferda Ozkinay, Huseyin Onay  
Article 106884

[Download PDF](#) Article preview [▼](#)

Research article ● Full text access

## Changes in endogenous daytime melatonin levels after aneurysmal subarachnoid hemorrhage – Preliminary findings from an observational cohort study

Felix Neumaier, Miriam Weiss, Michael Veldeman, Konstantin Kotliar, ... Walid Albanna  
Article 106870

[Download PDF](#) Article preview [▼](#)

Research article ● Full text access

## Preserved arachnoid membrane acts as a predictor of postoperative visual improvement in clinoidal meningioma

Yusuke Kimura, Masahiko Wanibuchi, Yukinori Akiyama, Takeshi Mikami, Nobuhiro Mikuni  
Article 106874

[Download PDF](#) Article preview [▼](#)



 Download PDF  Article preview

Research article  Full text access

## Using computerized spiral analysis to evaluate deep brain stimulation outcomes in Parkinson disease

Sara Radmard, Roberto A. Ortega, Blair Ford, Nora Vanegas-Arroyave, ... Seth L. Pullman

Article 106878

 Download PDF  Article preview

Research article  Full text access

## Idiopathic intracranial hypertension: Do we diagnose and manage it appropriately in the light of current data?

Buse Rahime Hasırcı Bayır, Ebru Nur Vanlı Yavuz, Betül Baykan

Article 106879

 Download PDF  Article preview

Research article  Full text access

## Mismatch repair proteins PMS2 and MLH1 can further refine molecular stratification of IDH-mutant lower grade astrocytomas

Rui Ryan Yang, Kay Ka-Wai Li, Zhen-Yu Zhang, Aden Ka-Yin Chan, ... Zhi-Feng Shi

Article 106882

 Download PDF  Article preview

Research article  Full text access

## Evaluation of combining Alberta Stroke Program Early CT Score (ASPECTS) with mean platelet volume, plateletcrit, and platelet count in predicting short- and long-term prognosis of patients with acute ischemic stroke

Hamidreza Ghodsi, Mohammad Ali Abouei Mehrizi, Ali Reza Khoshdel, Babak Shekarchi

Article 106830

 Download PDF  Article preview

Research article  Full text access

## Postoperative neovascularization, cerebral hemodynamics, and clinical prognosis between combined and indirect bypass revascularization procedures in hemorrhagic moyamoya disease

Jun Sun, Zhang-Yu Li, Chuan Chen, Cong Ling, ... Hui Wang

Article 106869

 Download PDF  Article preview





 Download PDF  Article preview 

Research article  Full text access

## Influence of operator experience on the technical and clinical results of Woven EndoBridge endovascular treatment for intracranial aneurysms

P. Daubé, F. Cagnazzo, X. Barreau, R. Morganti, ... G. Marnat

Article 106900

 [Download PDF](#) Article preview 

Research article  Full text access

## Long term outcome and fusion rate of transdiscal fixation for L5-S1 high grade spondylolisthesis

Juan Delgado-Fernández, Natalia Frade-Porto, Guillermo Blasco, Patricia González-Tarno, ... Rafael García de Sola

Article 106898

 [Download PDF](#) Article preview 

Research article  *Open access*

## Characterizing idiopathic intracranial hypertension socioeconomic disparities and clinical risk factors: A retrospective case-control study

Frances Tiffany Cava Morden, Charissa Tan, Enrique Carrazana, Jason Viereck, ... Arash Ghaffari-Rafi

Article 106894

 [Download PDF](#) Article preview 

Research article  Full text access

## Assessment of diagnostic potential of some circulating microRNAs in Amyotrophic Lateral Sclerosis Patients, an Egyptian study

Radwa Soliman, Nahla O. Mousa, Hebatallah R. Rashed, Ramez R. Moustafa, ... Nagia Fahmy

Article 106883

 [Download PDF](#) Article preview 

Research article  Full text access

## Aneurysmal and arteriovenous malformation hemorrhage during pregnancy: An update on the epidemiology, risk factors and prognosis

Oliver D. Mrowczynski, Sarah McNutt, Alexandre J. Bourcier, Ryan Jafrani, ... Elias B. Rizk

Article 106897

 [Download PDF](#) Article preview 

*Case reports*



Case report  Full text access

Oral and manual automatisms elicited by electrical stimulation of the pars opercularis cortex in a patient with frontal lobe epilepsy

Huanfa Li, Qiang Meng, Yong Liu, Shan Dong, Hua Zhang  
Article 106784

 [Download PDF](#)    Article preview 

Case report  Full text access

Characterization of a Portuguese family with Charcot-Marie-Tooth disease type 1E due to a novel point mutation in the *PMP22* gene

Marco Fernandes, André Caetano, Luís Castelhana, Luís Santos  
Article 106829

 [Download PDF](#)    Article preview 

Case report  Full text access

Visualization of hypermetabolism in the ventral visual pathway by FDG-PET in the Charles Bonnet syndrome

Hanako Sasaki, Yasunori Fujimoto, Hiroyuki Ima, Yu Kageyama  
Article 106832

 [Download PDF](#)    Article preview 

Case report  Full text access

Myasthenia gravis associated with novel coronavirus 2019 infection: A report of three cases

Narges Karimi, Ali Asghar Okhovat, Bentolhoda Ziaadini, Bahram Haghi Ashtiani, ... Farzad Fatehi  
Article 106834

 [Download PDF](#)    Article preview 

Case report  Full text access

Primary Nocardia brain abscesses and role of intraventricular antibiotic therapy

Marta Rico Pereira, Carlos Asencio Cortés  
Article 106846

 [Download PDF](#)    Article preview 

Case report  Full text access

Sagittal sinus dural arteriovenous fistula manifesting as unilateral vocal fold paresis

Lorenzo Rinaldo, Dale C. Ekbom, Giuseppe Lanzino



Shogo Shima, Shinsuke Sato, Tatsuki Motizuki, Yasunari Niimi

Article 106862

 [Download PDF](#)   Article preview 

Case report ● Full text access

Guillain-Barré syndrome after AstraZeneca COVID-19-vaccination: A causal or casual association?

Alessandro Introna, Francesca Caputo, Carlo Santoro, Tommaso Guerra, ... Maria Trojano

Article 106887

 [Download PDF](#)   Article preview 

Case report ● Full text access

Handwriting graphical parameters analysis in Posterior Cortical Atrophy: A case report

Alexandra Videt-Dussert, Alexandra Plonka, Alexandre Derreumaux, Valeria Manera, ... Auriane Gros

Article 106876

 [Download PDF](#)   Article preview 

Case report ● Full text access

Spastic gait, intellectual disability and seizures due to a rare mutation causing hyperargininemia

Christos Bakirtzis, Nikoletta Smyrni, Theodora Afrantou, Marina Kleopatra Boziki, Nikolaos Grigoriadis

Article 106895

 [Download PDF](#)   Article preview 

*Letters to editors*

Correspondence ● Full text access

Hemispheric hypoperfusion during a first attack of migraine accompagnée

Josef Finsterer, Ursula Cevese

Article 106837

 [Download PDF](#)

Correspondence ● Full text access

Response to "Letter to the editor concerning "High prevalence of cervical myelopathy in patients with idiopathic normal pressure hydrocephalus" by Naylor et al. (Clinical Neurology and Neurosurgery 2020; 197. /doi:10.1016/j.clineuro.2020.106099. e-pub: 2020 July 17)"

Ryan M. Naylor, Karina A. Lenartowicz, Jonathan Graff-Radford, David T. Jones, ... Benjamin D. Elder

Article 106820

# Clinical Neurology and Neurosurgery

Volume 208 (September 2021)

## Editor-in-Chief

Prof. Dr. P.P. De Deyn, Antwerp, Belgium

## Co-Editor-in-Chief

Prof. F. Roser, Abu Dhabi, United Arab Emirates

## Associate Editors

J. Burneo, Neurologist, University of Western Ontario, London Health Sciences Centre, Canada

P. W. Hitchon, Dept of Neurosurgery, University of Iowa College Of Medicine, 200 Hawkins Drive, Iowa, Iowa, 52242, USA

P. Jabbour, Stroke Neurosurgeon, Thomas Jefferson University Hospital, United States

M. Mondelli, Local Health Unit 7, Clinical Neurophysiology, EMG Service, Via Pian d'Ovile 9, 53100, Siena, Italy

M. Sughrue, Neurosurgeon, Prince of Wales Private Hospital, Australia

## Editorial Office Address

Prof. Dr. Peter P. De Deyn, c/o D. Norman, Elsevier, Stover Court, Bampfylde Street, Exeter, UK

## Advisory Editor

Prof. Dr. C.S. Raine, Department of Pathology, Albert Einstein College of Medicine, Bronx, NY, USA

## Editorial Board

J.M. Abdullah, Kelantan, Malaysia

F. Acerbi, Italy

D. Adamek, Poland

G. Albert, USA

G.A. Alexiou, Ioannina, Greece

F. Al Saiegh, USA

M. Ammirati, Columbus, OH, USA

A. Arboix Damunt, Spain

N. Arora, USA

J. Bogousslavsky, Epalinges, Switzerland

W. Boling, USA

D. Bednar, Canada

T. Brinker, Pawtucket, USA

R. Brouns, Brussels, Belgium

M. Bydon, Rochester, MN

P. Cappabianca, Naples, Italy

M. A de Carvalho, Portugal

N. Dahdaleh, Chicago, IL

A. Demetriades, Edinburgh, Scotland, UK

P. De Bonis, Rome, Italy

M. De Visser, Amsterdam, The Netherlands

J. Donahue, Providence, USA

S. Engelborghs, Antwerp, Belgium

M. Eksi, Turkey

J. Favre, Switzerland

K. Fountas, Terpsithea-Larisa, Greece

M. Fusco, USA

V. Gerganov, Hannover, Germany

A. Ghaffari-Rafi, UK

J.E. Greenlee, Salt Lake City, USA

L. Hacin-Bey, Sacramento, USA

M.L. Hlavin, USA

C. Igram, USA

Y. Izci, Ankara, Turkey

D. Jakimovski, USA

S. John, United Arab Emirates

M. Kasliwal, USA

S. Krieg, Germany

S. Linsler, Germany

Y.L. Lo, Singapore, Singapore

W. Luedemann, Hannover, Germany

L. Marshman, Townsville, Australia

D. Mathieu, Canada

A. Menezes, USA

A. Michotte, Brussels, Belgium

M.L.R. Monteiro, São Paulo, Brazil

Y. MOROFUJI, Japan

M. Nakamura, Hannover, Germany

R. Navarro, Australia

F. de Oliveira, Brazil

D. Papadopoulous, Greece

H.L. Rekate, Phoenix, USA

L. Rigante, Germany

Y. Rajabally, UK

A. Roman, Brazil

F.M. Santorelli, Italy

A. Seifi, USA

R. Sheorajpanday, Antwerp, Belgium

M. Socolovsky, Argentina

J. Sotelo, Mexico City, Mexico

S. Takahashi, Japan

D. Tafiadis, Greece

C. Ugas, United Arab Emirates

W. Versleger, Belgium

S.G. Waxman, New Haven, USA

E.F.M. Wijidicks, Rochester, USA

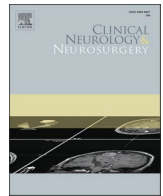
R. Xie, China

S. Yamaguchi, USA

B. Zhao, China



ELSEVIER



# Chronic subdural hematoma-induced parkinsonism: A systematic review

Achmad Fahmi<sup>a,b,\*</sup>, Heru Kustono<sup>a,b</sup>, Komang Sena Adhistira<sup>a,b</sup>, Heri Subianto<sup>a,b</sup>,  
Budi Utomo<sup>c</sup>, Agus Turchan<sup>a,b</sup>

<sup>a</sup> Department of Neurosurgery, Faculty of Medicine, Universitas Airlangga, Surabaya, Indonesia

<sup>b</sup> Dr. Soetomo General Academic Hospital, Surabaya, Indonesia

<sup>c</sup> Department of Public Health and Preventive Medicine, Faculty of Medicine, Universitas Airlangga, Surabaya, Indonesia

## ARTICLE INFO

### Keywords:

Chronic subdural hematoma  
Parkinsonism  
Parkinson's disease

## ABSTRACT

**Background:** Chronic subdural hematoma (CSDH) is one of the most common neurosurgical cases, especially in elderly individuals. Secondary parkinsonism due to CSDH is a rare entity. The mechanism of parkinsonism symptoms in chronic subdural hematoma has been suggested to include direct mechanical compression of the basal ganglia due to hematoma or indirectly through brain structure changes due to space lesions and vascular disorders. Surgery on the subdural hematoma provides a favorable outcome for parkinsonism symptoms.

**Objectives:** To systematically review the literature on CSDH-induced parkinsonism.

**Search methods:** This is a systematic review on case reports. Literature search was performed using the predefined keywords on PubMed, ProQuest, and Google Scholar. We also provided our own case report and compared it with published studies.

**Result:** Sixteen cases from 13 case reports/series were identified, predominantly consisting of male patients with the mean age of  $66.5 \pm 9.73$  years. The most common symptoms were rigidity, gait disturbance, and bradykinesia, observed in 12 (75%) cases each. The second and third most common symptoms were tremor (11; 68.75%) and facial masking (8; 50%), respectively. Other reported symptoms were dysphasia (3; 18.75%), dysarthria (3; 18.75%), and urinary incontinence (2; 12.5%). Time gap between the symptom onset and CSDH diagnosis and unilateral location seemed to influence the outcome.

**Conclusion:** Only 16 CSDH-induced parkinsonism were identified since the 1960s. This condition is thought to occur due to basal ganglia compression. Surgery on the subdural hematoma provides a favorable outcome for parkinsonism symptoms. Timely CSDH diagnosis might yield better outcome. However, further research on CSDH-induced parkinsonism is needed, especially in the mechanisms and treatment outcomes.

## 1. Introduction

Chronic subdural hematoma (CSDH) is a common neurosurgical diagnosis among elderly individuals [1]. This condition could occur following a trivial head trauma, and thus, patients usually cannot recall such event ever happening [2]. Various CSDH symptoms range from asymptomatic to the presence of neurological deficits, such as speech and motor [3].

CSDH could rarely cause parkinsonism [4]. The underlying mechanism of CSDH-induced parkinsonism has not been well understood. Mass effect on the basal ganglia [5] or the midbrain [6] might decrease the number of dopaminergic receptors and nigro-striatal dopaminergic pathway, respectively.

To date, this type of secondary parkinsonism has been described in the limited number of publications, predominantly in the form of case reports. Therefore, this study aimed to review the general characteristics, symptoms, onset, and outcomes of CSDH-induced parkinsonism based on the available published case reports.

## 2. Material and methods

### 2.1. General information and literature search strategy

Studies were selected using the Preferred Reporting Items for Systematic Review and Meta-Analysis Protocol method guideline. Data were collected from *PubMed*, *Scienccdirect*, *Springer*, and *Cochrane*.

\* Correspondence to: Faculty of Medicine Universitas Airlangga, Dr. Soetomo General Academic Hospital, Jalan Mayjend Prof. Dr. Moestopo No. 6 - 8, Surabaya 60286, Indonesia.

E-mail address: [achmad.fahmi@fk.unair.ac.id](mailto:achmad.fahmi@fk.unair.ac.id) (A. Fahmi).

<https://doi.org/10.1016/j.clineuro.2021.106826>

Received 12 October 2020; Received in revised form 29 June 2021; Accepted 18 July 2021

Available online 21 July 2021

0303-8467/© 2021 Elsevier B.V. All rights reserved.

**Table 1**  
Search strategy.

No	Keywords
1	Chronic Subdural Hematoma
2	Subdural Hematoma
3	"Hematoma, Subdural, Chronic" [Mesh]
4	"Hematoma, Subdural, Intracranial" [Mesh]
5	Parkinsonism
6	Parkinson Disease
7	"Parkinson Disease, Secondary" [Mesh]
8	"Parkinson Disease" [Mesh]
9	"Parkinsonian Disorders" [Mesh]
10	(#1 OR #2 OR #3 OR #4) AND (#5 OR #6 OR #7 OR #8 OR #9)

**2.2. Eligibility criteria**

Articles included in this review were case reports of patients without age or origin restriction who had CSDH with parkinsonism symptoms. Only articles written in English were accepted for this review. For inclusion, published articles must report CSDH, parkinsonism symptoms, surgery, outcomes, and follow-up patients.

All articles as well as reviews, editorials, commentaries, or publications not reporting patients outcome were excluded. Studies performing analysis without description of individual patients were excluded. All case reports and case series on patients with history of Parkinson's disease (PD) were further excluded.

**2.3. Information source and search strategy**

We conducted a systematic search on the literature to identify relevant articles using PubMed, ProQuest, and Google Scholar using the following keywords in Table 1.

**2.4. Study selection**

All potentially included articles were screened in two eligibility stages. In the first assessment stage, titles and abstracts of potentially pertinent articles were independently screened by two authors (HK and SA). For abstracts that met the inclusion criteria, the full text was retrieved and independently reviewed by the same authors in the second assessment stage. Contretemps and technical uncertainties were discussed and resolved among review authors (HK, SA, AF, HS, BU and AT).

**2.5. Data collection**

The data collection protocol was designated and agreed before starting the project. Bibliographic data, patient's management, outcome feature, and follow-up outcome were extracted. Two authors (HK and SA) independently extracted the data from selected studies. Data were jointly reconciled, and disputes and technical uncertainties were discussed and resolved among review authors (HK, SA, AF, HS, BU and AT).

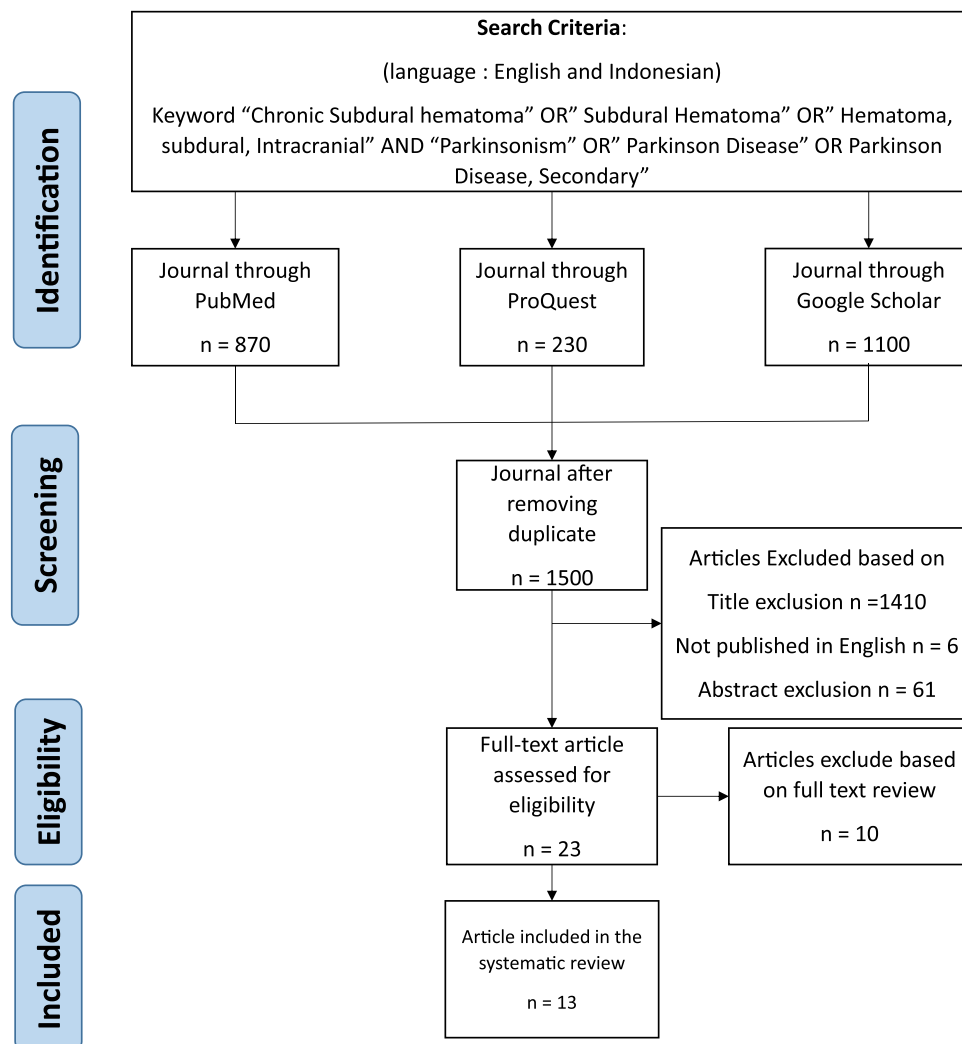


Fig. 1. PRISMA flow diagram of article search, screening, eligibility, and inclusion.

**Table 2**  
Participant characteristic of all included studies.

Mean age (years)	66.5 ± 9.73
Site of lesion n (%)	
Bilateral	7 (43.75)
Right-sided	5 (31.25)
Left-sided	4 (25)
Traumatic event n (%)	
Known	10 (62.5)
Denied	6 (37.5)
Symptoms	
Tremor	11 (68.75)
Rigidity	12 (75)
Gait disturbance	12 (75)
Dysphasia	3 (18.75)
Facial masking	8 (50)
Bradykinesia	12 (75)
Urinary incontinence	2 (12.5)
Dysarthria	3 (18.75)
Time to symptoms n (%)	
≤1 month	6 (37.5)
>1 month	4 (25)
Unreported	6 (37.5)
Symptoms to diagnosis n (%)	
≤1 month	10 (62.5)
>1 month	5 (31.25)
Unreported	1 (6.25)
Treatment n (%)	
Burr hole drainage	8 (50)
Craniotomy	3 (18.75)
Burr hole drainage + medication	2 (12.5)
Craniotomy + medication	1 (6.25)
Observation	1 (6.25)
Not reported	1 (6.25)
Outcome	
Minimally symptomatic/partial recovery	6 (37.5)
No symptoms	10 (62.5)
Duration of follow-up (median, range)	3 months (1 week–4 years)

### 3. Results

#### 3.1. Search result

Our search strategy yields 12 case reports and one case series published from 1963 to 2017. The detailed exclusion process of search results can be observed in Fig. 1.

#### 3.2. Summary of studies

The included studies comprised 16 cases of CSDH-induced parkinsonism, and 12 (75%) of which occurred in male. The youngest patient aged 38 years [7], whereas the oldest aged 83 years [8]. The mean age was 66.5 ± 9.73 years (Table 2). Hematoma in seven of these cases were bilateral, five were on the left side, and the rest were on the right side. In ten (62.5%) of 16 cases, the traumatic event leading to CSDH could be identified, whereas the other six (37.5%) could not recall such event.

The time gap between known traumatic event to the symptom onset ranged from 1 week to 6 months. Conversely, the CSDH diagnosis was known as early as 1 week to as late as 5 months since the symptom onset. Burr hole drainage and craniotomy were performed in eight (50%) and three (18.75%) studies, respectively. The presentation of CSDH can occur in patients with confirmed PD, that we did not include it in the CSDH-induced parkinsonism group [9,10]. One case had combined levodopa and craniotomy [11]. One case unfortunately did not specifically mention the performed surgical procedure [12], whereas the other one decided to only observe the patient without any intervention [13].

The most common symptoms were rigidity, gait disturbance, and bradykinesia, as reported in 12 (75%) of the cases each. The second and third most common symptoms were tremor (11; 68.75%) and facial masking (8; 50%), respectively. Other reported symptoms were dysphasia (3; 18.75%), dysarthria (3; 18.75%), and urinary

incontinence (2; 12.5%) (Table 3).

We tried to calculate the risk ratio of SDH location and its outcome. Bilateral CSDH resulted in minimally symptomatic outcome in two cases and free of symptoms in five cases. Unilateral CSDH resulted in minimally symptomatic outcome in four cases and free of symptoms in five cases. Risk ratio (RR) calculation showed that unilateral CSDH is 1.5, more likely to result in partial recovery.

We also tried to dichotomize the time gap of symptom onset to CSDH diagnosis into ≤1 month and >1 month. Three symptomatic patients were classified in the ≤1-month group and 7 patients who were asymptomatic upon follow-ups. In the >1-month group, three and two patients were symptomatic and asymptomatic, respectively. One patient did not mention the time gap between symptom onset and CSDH diagnosis. The RR calculation showed that longer time gap between symptoms and diagnosis doubled the risk of partial recovery.

### 4. Discussion

Parkinsonism due to CSDH quite rarely occurs. We had experienced treating such patient. A 76-year-old man presents with rigidity and tremors in both arms and legs for 1 month before admission. He also complained of sluggish movement of both arms and legs. Complaints are continuously getting worse. The Unified Parkinson Disease Rating Scale (UPDRS) shows a score of 100. In the last 1 month, the patient fell and hit his head; however, he did not remember the exact time of and frequency of occurrences. Other complaints such as headache, nausea, vomiting, seizures, and decreased consciousness were not observed. No history of parkinsonism was observed. Patient also had no history of Parkinson medication.

The patient then underwent a magnetic resonance imaging (MRI) of the head, revealing a bilateral chronic subdural hematoma (CSDH) (Fig. 2). We decided to perform bilateral burr-hole drainage craniotomy. Postoperative computed tomography (CT) scan evaluation shows decreased hematoma size (Fig. 3). Parkinson-like symptoms disappeared immediately after the surgery, and the UPDRS shows a score of 24. After a 2-week hospitalization, the patient was discharged without any anti-Parkinson drugs administered. Postoperative follow-up shows complete resolution of all Parkinson-like symptoms. The UPDRS score remains at 24, until the 5-year postoperative follow-up. The 2-year postoperative MRI examination shows no residual hematoma left (Fig. 4).

Parkinsonism consists of several extrapyramidal signs, characterized by muscle rigidity, tremor, bradykinesia, and loss of postural reflexes. The most common cause of parkinsonism is idiopathic Parkinson's disease, whereas the secondary ones include drug exposure, infection, and trauma, constituting approximately 14–16% of all cases, especially in patients aged ≥40 years [10,14–18].

Acute onset of parkinsonism or worsening of pre-existing parkinsonism is a rare CSDH manifestation, but is significantly correlated because both parkinsonism and CSDH are related with elderly individuals [9,16]. Trauma is an important factor in the CSDH occurrence in elderly individuals. Old age is associated with cerebral atrophy and increased venous fragility, the major predisposing factors for CSDH, even after the minor head injury. Nevertheless, a direct head injury is not reported in 30–50% of studies [19,20]. CSDH itself may have various movement disorder manifestations, such as chorea [21], dystonia [22], and parkinsonism [13,17]. Movement disorders are occasionally associated with chronic subdural hematomas [9].

The interval between initial symptoms and CSDH diagnosis ranged from 1 week to 1 year (mean interval, 8 weeks) in a study [10]. The pathomechanism leading to parkinsonism in CSH remains unclear, and several mechanisms can be postulated. Direct mechanical pressure on the basal ganglia, either directly by the overlying hematoma or through torsion and brain structure displacement, has been postulated [7,15]. Compression may result in decreased number of dopaminergic receptors in the striatum, and a disturbance of nigrostriatal pathways and striatum

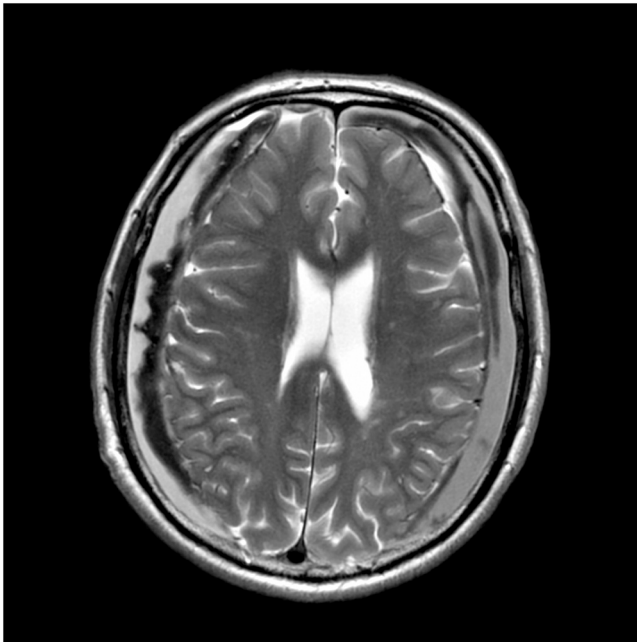
**Table 3**  
Summary of findings of included studies.

No	Author	Participants		Symptoms	Diagnosis	History of trauma	Trauma to onset of symptoms	Treatment	Onset of Symptoms to Diagnosis of CSDH	Outcome	
		Sex	Age (year)							Symptom	Duration of follow-up
1	Samiy, 1963	M	52	Tremor, rigidity, gait disturbance, dysphasia.	CSDH (L)	Denied	n/a	Craniotomy	4 months	Minimal	3 months
2	Sandyk, 1983	F	38	Tremor, rigidity, gait disturbance, facial masking, dysphasia, bradykinesia	CSDH (R)	Denied	n/a	Craniotomy	3 weeks	None	3 months
3	Accardi, 1985	M	48	Tremor, rigidity, gait disturbance, bradykinesia	Bilateral CSDH	Denied	n/a	Surgery, not specifically mentioned	5 months	Minimal	3 months
4	Krul, 1987	M	83	Tremor, rigidity, gait disturbance, facial masking, dysphasia, bradykinesia, urinary incontinence.	Bilateral Frontal CSDH	Yes	1 week	Burr hole	3 weeks	Partial recovery	n/a
5	Pau, 1989	F	60	Rigidity, bradykinesia	CSDH (R)	Yes	1 month	Craniotomy	1 month	Minimal	3 months
6	Hageman, 1994	M	66	Tremor, facial masking, dysarthria, bradykinesia	CSDH (L)	Denied	n/a	Observation	a few months	Minimal	3 months
7	Sunada, 1996	M	75	Tremor, rigidity, gait disturbance, facial masking	CSDH (L)	Yes	1 month	Levodopa 3 months + Craniotomy	1 month	None	3 months
8	Wiest, 1999	M	63	Tremor, rigidity, gait disturbance, facial masking, dysarthria, bradykinesia	CSDH (R)	Yes	1 week	Pre-op Levodopa 3 × 250 mg + Burr hole	n/a	None	4 weeks
9	Suman, 2006	M	81	Rigidity, gait disturbance	Bilateral Frontoparietal CSDH	Yes	2 months	Burr hole	2 weeks	None	1 weeks
10	Park, 2009	M	78	Tremor, rigidity, gait disturbance, facial masking, dysarthria, bradykinesia	CSDH (L)	Yes	3 months	Burr hole	2 weeks	Minimal	3 weeks
11	Bostantjopoulou, 2009	F	65	Rigidity, gait disturbance, facial masking, bradykinesia	Bilateral CSDH	Yes	45 days	Burr hole	1 weeks	None	1 months
12	Gelabert-Gonzalez, 2012	M	71	Tremor, rigidity, bradykinesia	Bilateral Frontoparietal CSDH	Yes	1 week	Pre-op Levodopa (20 days) + Burr hole	35 days	None	2 months
		M	68	Tremor, gait disturbance, bradykinesia	CSDH (L)	Denied	n/a	Burr hole	1 month	None	3 months
		M	77	Rigidity, gait disturbance	Bilateral CSDH	Yes	1 month	Burr hole	2 weeks	None	6 months
		F	59	Tremor, facial masking, bradykinesia	CSDH (R)	Denied	n/a	Burr hole	7 weeks	None	4 weeks
13	Guppy, 2017	M	80	Gait disturbance, urinary incontinence, bradykinesia	Bilateral CSDH	Yes	6 weeks	Burr hole	2 weeks	None	4 years

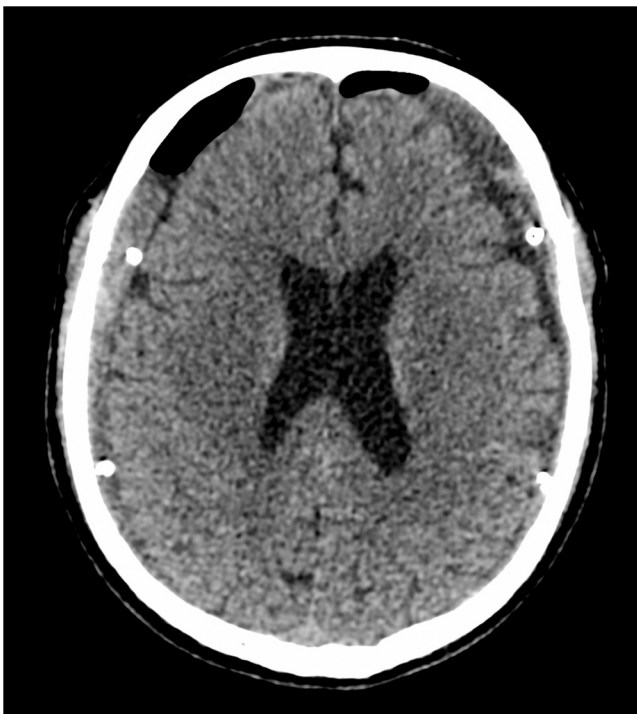and lead to onset of a parkinsonian syndrome. Reduction of dopaminergic receptors has been reported in a patient with parkinsonism secondary to an intracranial tumor who did not benefit from levodopa therapy [9]. Midbrain compression from the transtentorial uncal herniation following the brain shift has also been postulated [3]. Positron emission tomography (PET) and diffusion tensor imaging (DTI) MRI might be helpful to uncover the mechanism in the future. Transient circulatory disturbances of basal ganglion structures could be caused by

anterior choroidal artery displacement and compression. Exploration about glymphatics and brain lymphatics also needed. For the compressive theory, all patients rapidly recovered after the subdural hematoma evacuation and displacement disappearance of the hemisphere [7]. However, the rarity of parkinsonism due to CSH has led to the hypothesis that these particular patients may have preclinical nigrostriatal dysfunction, and therefore, they cannot compensate with further insults to the basal ganglia [13,23].



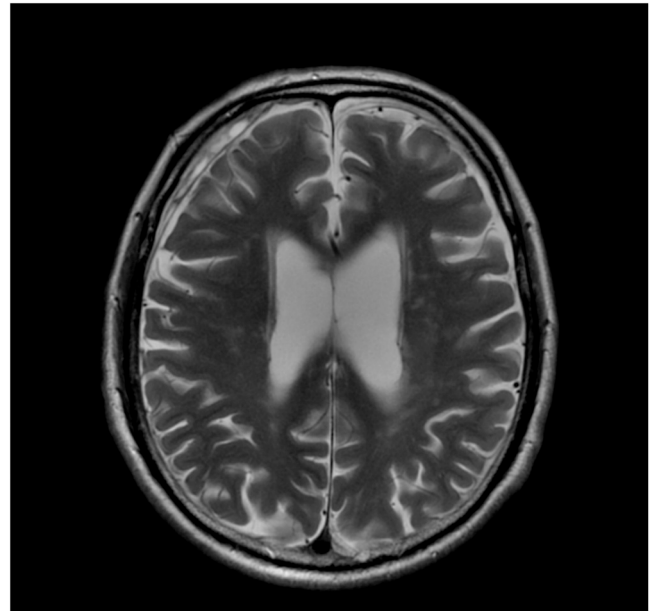


**Fig. 2.** Preoperative brain MRI examination shows a bilateral crescent-shaped hyperdense lesion under the dura mater that compresses both hemispheres of the cortex, suggesting a bilateral chronic subdural hematoma (CSDH).



**Fig. 3.** Postoperative head CT scan shows the drainage tube placed in the bilateral subdural space, decreasing the hematoma size. A, Axial CT scan; B, Three-dimensional reconstruction.

Our patient presented with an extremely new onset, and rapidly progressive symmetrical parkinsonism that affects the whole body. This patient was suspected with CSDH due to history of head impacts for the last 1 month. CSDH in this patient is suspected to be the main cause of the occurrence of signs and symptoms of parkinsonism. This is evident after the hematoma drainage; the patient has experienced dramatic and rapid clinical improvement. Even in the hospitalization, the patient did



**Fig. 4.** Two-year postoperative brain MRI examination shows a small residual of hematoma.

not take any anti-parkinsonism medications postoperatively until 5-years follow-up. Surgical evacuation of the hematoma has become the gold standard for patients with CSDH, with or without parkinsonism symptoms, and these patients have demonstrated rapid symptom improvement in patients postoperatively [7].

Long-term evaluation is required in these patients, due to the theory of preclinical nigrostriatal dysfunction in patients with parkinsonism in CSDH. Our patients were subjected to periodic follow-up and brain MRI 2-years postoperatively (Fig. 4). To evaluate the signs and symptoms of Parkinson's disease in these patients, a thorough assessment, including regular UPDRS scoring as performed in our patient, is necessary [13,23].

#### 4.1. Limitation

Limitation of this review relates to exclusion of case reports and case series not in English or Bahasa. Moreover, we might have missed few case reports because relevant search terms may not be found in titles or abstracts. In this study, the conclusions are also found to be limited due to the small number of identified articles.

Another limitation of this review is that the outcome assessment was unclear, as only one case report used the UPDRS to assess the outcome.

#### 5. Conclusion

Only 16 CSDH-induced parkinsonisms were identified since the 1960s. This condition is thought to occur due to basal ganglia compression. Surgery on the chronic subdural hematoma provides a favorable outcomes on alleviating parkinsonism symptoms. Timely diagnosis of CSDH might result in better outcomes. To screen any CSDH-induced parkinsonism, we propose to perform CT Scan or MRI in every patient with parkinsonism. Further research is needed on CSDH-induced parkinsonism is needed, especially in the mechanisms and treatment outcomes.

#### Funding

This research did not receive any specific grant from funding agencies in the public, commercial, or not-for-profit sectors.

## Conflict of interest

The authors declare no conflict of interest regarding this study.

## References

- [1] L.B. Miranda, E. Braxton, J. Hobbs, M.R. Quigley, Chronic subdural hematoma in the elderly: not a benign disease, *J. Neurosurg.* 114 (2011) 72–76, <https://doi.org/10.3171/2010.8.jns10298>.
- [2] A. Chari, K.C. Hocking, E. Edlmann, C. Turner, T. Santarius, P.J. Hutchinson, A. G. Kolias, Core outcomes and common data elements in chronic subdural hematoma: a systematic review of the literature focusing on baseline and peri-operative care data elements, *J. Neurotrauma* 33 (2016) 1569–1575, <https://doi.org/10.1089/neu.2015.4248>.
- [3] Y.R. Yadav, V. Parihar, H. Namdev, J. Bajaj, Chronic subdural hematoma, *Asian J. Neurosurg.* 11 (2016) 330–342, <https://doi.org/10.4103/1793-5482.145102>.
- [4] B. Park, S.K. Song, J.Y. Hong, P.H. Lee, Parkinsonism due to a chronic subdural hematoma, *J. Mov. Disord.* 2 (2009) 43–44, <https://doi.org/10.14802/jmd.09011>.
- [5] J. García de Yébenes, J.J. Gervas, J. Iglesias, M.A. Mena, R. Martín del Río, E. Somoza, Biochemical findings in a case of parkinsonism secondary to brain tumor, *Ann. Neurol.* 11 (1982) 313–316, <https://doi.org/10.1002/ana.410110313>.
- [6] M.J. Ling, A. Aggarwal, J.G.L. Morris, Dopa-responsive parkinsonism secondary to right temporal lobe haemorrhage, *Mov. Disord.* 17 (2002) 402–404, <https://doi.org/10.1002/mds.10081>.
- [7] R. Sandyk, Parkinsonism due to subdural hematoma, *J. Neurosurg.* 58 (1983) 298–299, <https://doi.org/10.3171/jns.1983.58.2.0298>.
- [8] J.M.J. Krul, J.H.J. Wokke, Bilateral subdural hematoma presenting as subacute parkinsonism, *Clin. Neurol. Neurosurg.* 89 (1987) 107–109, [https://doi.org/10.1016/0303-8467\(87\)90184-3](https://doi.org/10.1016/0303-8467(87)90184-3).
- [9] R.G. Wiest, J.M. Burgunder, J.K. Krauss, Chronic subdural haematomas and parkinsonian syndromes, *Acta Neurochir.* 141 (1999) 753–758, <https://doi.org/10.1007/s007010050371>.
- [10] M. Gelabert-Gonzalez, R. Serramito-García, E. Aran-Echabe, Parkinsonism secondary to subdural haematoma, *Neurosurg. Rev.* 35 (2012) 457–460, <https://doi.org/10.1007/s10143-012-0386-1>.
- [11] B. Park, S.K. Song, J.Y. Hong, P.H. Lee, Parkinsonism due to a chronic subdural hematoma, *J. Mov. Disord.* 2 (2009) 43–44, <https://doi.org/10.14802/jmd.09011>.
- [12] R. Accardi, G. Arnetoli, F. Ammannati, Parkinsonism caused by chronic subdural hematoma. a case report, *Ital. J. Neurol. Sci.* 6 (1985) 109–111, <https://doi.org/10.1007/bf02229229>.
- [13] A.T. Hageman, M.W. Horstink, Parkinsonism due to a subdural hematoma, *Mov. Disord.* 9 (1994) 107–108, <https://doi.org/10.1002/mds.870090120>.
- [14] E. Samiy, Chronic subdural hematoma presenting a Parkinsonian syndrome, *J. Neurosurg.* 20 (1963) 903, <https://doi.org/10.3171/jns.1963.20.10.0903>.
- [15] A. Pau, M. Brambilla, M. Cossu, R. Schoenhuber, D. Siccardi, S. Turtas, Parkinsonism in the presence of intracranial extracerebral haematomas, *Acta Neurochir.* 96 (1989) 159–160, <https://doi.org/10.1007/bf01456177>.
- [16] S. Suman, S. Meenakshisundaram, P. Woodhouse, Bilateral chronic subdural haematoma: a reversible cause of parkinsonism, *J. R. Soc. Med.* 99 (2006) 91–92, <https://doi.org/10.1258/jrsm.99.2.91>.
- [17] S. Bostantjopoulou, Z. Katsarou, M. Michael, A. Petridis, Reversible parkinsonism due to chronic bilateral subdural hematomas, *J. Clin. Neurosci.* 16 (2009) 458–460, <https://doi.org/10.1016/j.jocn.2008.03.016>.
- [18] K.H. Guppy, S.M. Khandhar, C. Ochi, Reversible Parkinson-like symptoms in patient with bilateral chronic subdural hematomas and cervical spinal stenosis, *World Neurosurg.* 109 (2018) 285–290, <https://doi.org/10.1016/j.wneu.2017.10.009>.
- [19] M. Asghar, V. Adhiyaman, M.W. Greenway, B.K. Bhowmick, A. Bates, Chronic subdural haematoma in the elderly - a North Wales experience, *J. R. Soc. Med.* 95 (2002) 290–292, <https://doi.org/10.1258/jrsm.95.6.290>.
- [20] V. Adhiyaman, M. Asghar, K.N. Ganeshran, B.K. Bhowmick, Chronic subdural haematoma in the elderly, *Postgrad. Med. J.* 78 (2002) 71–75, <https://doi.org/10.1136/pmj.78.916.71>.
- [21] V.E. Young, G. Pickett, P.L. Richardson, P. Leach, Choreathetoid movement as an unusual presentation of subdural haematoma, *Acta Neurochir.* 150 (2008) 733–735, <https://doi.org/10.1007/s00701-008-1591-0>.
- [22] F.A. Nobbe, J.K. Krauss, Subdural hematoma as a cause of contralateral dystonia, *Clin. Neurol. Neurosurg.* 99 (1997) 37–39, [https://doi.org/10.1016/s0303-8467\(96\)00556-2](https://doi.org/10.1016/s0303-8467(96)00556-2).
- [23] N. Turjanski, B. Pentland, A.J. Lees, D.J. Brooks, Parkinsonism associated with acute intracranial hematomas: an [18F]dopa positron-emission tomography study, *Mov. Disord.* 12 (1997) 1035–1038, <https://doi.org/10.1002/mds.870120630>.