



Dystonia and parkinsonism as presenting CADASIL features: a case report

Francesca Spagnolo¹ · Vincenza Pinto¹ · Augusto Maria Rini¹ · Bruno Passarella¹

Received: 22 January 2021 / Accepted: 13 June 2021
© Fondazione Società Italiana di Neurologia 2021

Dear Editor-in-Chief,

Cerebral autosomal dominant arteriopathy with subcortical infarcts and leukoencephalopathy (CADASIL) is the most common hereditary small vessel disease; it results from mutations in the *Notch3* gene, encoding for a transmembrane protein mainly expressed in vascular smooth muscle cells [1]. Since the first identification, over 200 mutations of *Notch3* have been identified; however, no specific phenotype-genotype association has been described.

CADASIL-phenotypic expressions are mainly due to an augmented cerebrovascular risk. The earliest and most common CADASIL-clinical manifestation is migraine, generally followed by transient ischemic attacks or subcortical lacunar events, occurring in 60 to 85% of cases. Cognitive decline with a typical multidomain deficit is the third most frequent symptom; epileptic seizures and psychiatric disorders may also occur. The variable expression of *Notch3* mutations is likely responsible for widespread underrecognition and misdiagnosis of this syndrome.

Abnormalities on brain magnetic resonance imaging (MRI) are observed in virtually all CADASIL-subjects and consist of diffuse white matter lesions and lacunar infarcts.

Movement disorders are not considered a typical CADASIL-phenotype and most frequently occur later in disease progression.

Here we report the case of a male presenting with a movement disorder characterized by progressive dystonic and parkinsonian features and later diagnosed as a CADASIL-disease mutation carrier.

A 60-year-old man with a 7-year history of right facial hemispasm and a minor stroke when he was 54, came to our attention 2 years ago for an insidiously progressive gait slowing, inconstant right-limb tremor, and upper limbs abnormal posture, associated with unmotivated laughing and crying. There was no previous history of neuroleptic use, neither of migraine.

Unfortunately, no many data about patient's family history are available, as both his parents died and he is only child. Specifically, his mother died at 58 of myocardial infarction, while his father died at 84 in unknown circumstances. Among his offspring, patient's daughter suffers from juvenile myoclonic epilepsy and underwent a normal brain MRI scan.

On his first neurological examination in our clinic, he showed an inconstant, mild-amplitude, rest tremor in his right hand and a dystonic upper limbs posture during walking, with a bradykinetic, slightly unstable, gait. Patient's cognitive profile revealed a reduced global cognitive efficiency (Montreal cognitive assessment—MOCA: 16/30), with multiple domain deficits involving memory, attention, and executive functions, especially verbal fluency. Because of the characteristic pattern of MRI lesions, showing extensive white matter periventricular involvement and deep grey nuclei lacunar infarcts (Fig. 1), in the absence of conventional vascular risk factors, a diagnosis of CADASIL was suspected. Mutational screening of the *Notch3* gene (coding exons 1–33) revealed a mutation (V322M) in exon 6, previously reported in CADASIL patients (2). A skin biopsy was refused by our patient.

A DaTscan-SPECT imaging was unremarkable. Antiplatelet monotherapy and a low dose of levodopa (levodopa/benserazide 300 mg per day) were initiated, and carried on, with minimal improvement in bradykinesia and mental slowing. Two years after diagnosis, instability and dystonic features slightly worsened and became more symmetrical, while rest tremor disappeared (Video 1). A new brain MRI

Francesca Spagnolo and Vincenza Pinto these authors contribute equally to this work.

✉ Francesca Spagnolo
francesca.spagnolo81@gmail.com

¹ Neurological Department, Antonio Perrino's Hospital, Strada Statale 7 per Taranto, 72100 Brindisi, Italy

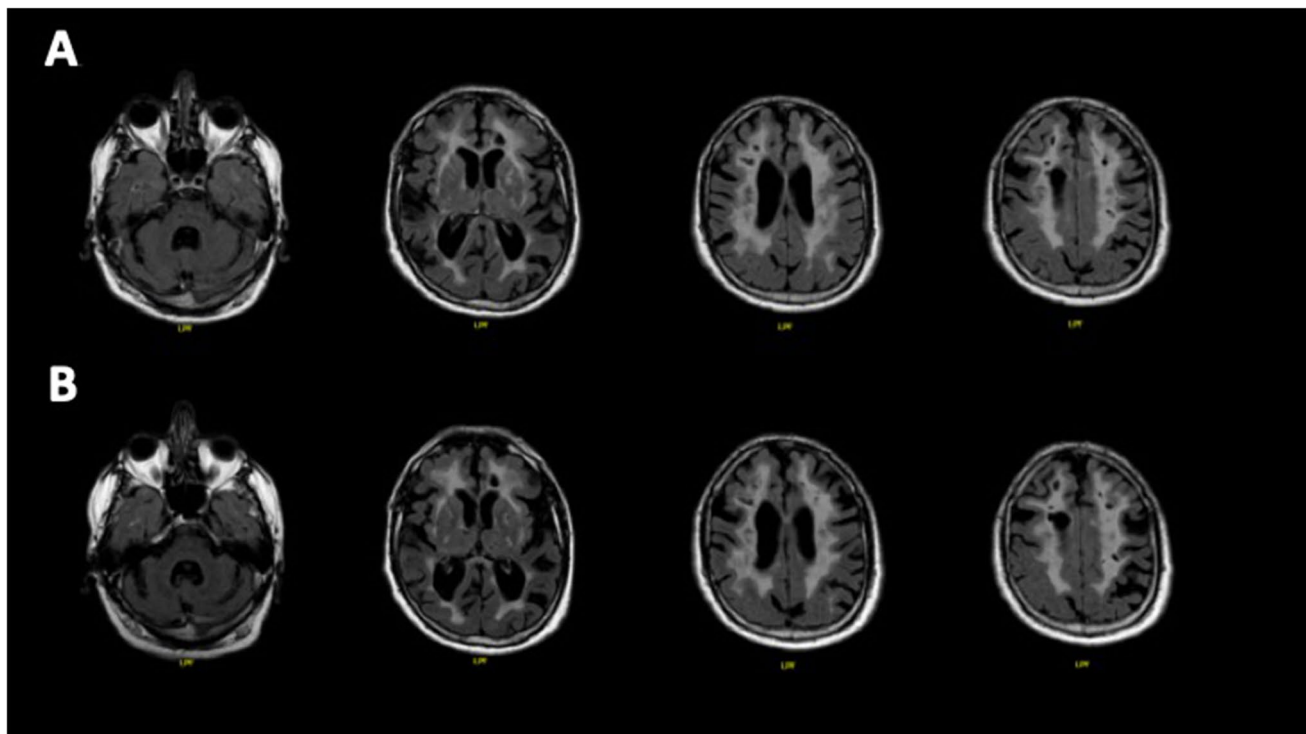


Fig. 1 Brain MRI at different timepoints: at the diagnosis, when the patient was 58 (**a**), and after 2 years, when he was 60 (**b**). In both cases, brain MRI demonstrates confluent and symmetrical distribution of white matter lesions in periventricular area, semioval center, and external capsule on fluid attenuation inversion recovery (FLAIR)

mainly showed a progression of cortical and subcortical atrophy (Fig. 1).

Both proband's offspring were referred to a genetic counselor and underwent predictive genetic testing with negative results.

Here we describe an atypical, never reported, clinical presentation of CADASIL. In our patient, dystonia and parkinsonism coexisted and were the initial symptoms leading to look for medical attention. CADASIL varies widely in its clinical presentation, with migraine and subcortical lacunar ischemic events being the most commonly reported initial symptoms [2]. Among unusual CADASIL presentations, movement disorders are seldom reported. Particularly, facial dystonia has been described once, in two members of a CADASIL family [3], while parkinsonism, described more frequently, is generally a tardive clinical feature [4, 5]. A study on a large sample of 102 CADASIL patients showed an age-dependent increase of basal ganglia symptoms in up to 48% patients older than 60 [1].

Ragno et al. reported five CADASIL patients carrying the R10006C mutation affected by parkinsonism [6]; however, no specific phenotype-genotype association has been described, and patients with parkinsonism carrying different mutations have been reported. Akinesia, rigidity, and

imaging. Multiple lacunar infarcts can be observed predominantly in basal ganglia and subcortical white matter. A slight progression of the vascular load and a worsening of cortico-subcortical atrophy can be appreciated at the last radiological follow-up (**b**)

postural instability seem the main clinical parkinsonian signs, whereas so far rest tremor has never been described [6]. Asymmetry of motor signs is not generally reported in CADASIL patients suffering from parkinsonism. In our case, an asymmetric rest tremor was observed, even if inconsistently, at the diagnosis, associated with other parkinsonian and dystonic signs.

It is conceivable that small vessel disease affecting the striatonigral or the thalamocortical pathways is primarily responsible for parkinsonian phenotype in CADASIL patients, leading to a disconnection in the motor circuit. Sporadic causes of stroke can induce delayed onset dystonia due to lesions involving components of the cortico-thalamic-basal ganglia circuits, with most lesions involving the striatum or thalamus. The absence of response to levodopa typically described in CADASIL patients [6] suggests that dysfunction of the striatal dopamine receptors or of the nondopaminergic thalamocortical pathways also contributes to the pathophysiology of CADASIL-related parkinsonism. Despite the normal DaTscan imaging, our patient showed a slight clinical improvement with chronic levodopa intake, especially on bradykinesia and mental processing speed. More than 95% of CADASIL mutations are missense mutations altering the number of cysteine residues within the

epidermal growth factor (EGF)-like repeats of Notch3 extracellular portion [7].

However, beside canonical “cysteine-residues rule” mutations, several cysteine-sparing mutations exist, as in the case we described here. Skin biopsies in two unrelated patients carrying the same variant (V322M) here reported, revealed the existence of CADASIL-specific deposits of granular osmiophilic material (GOM) affecting the basal membranes of vascular smooth muscle cells, without any difference with cysteine-related mutations, confirming the pathogenicity of this Notch3 variant [7].

Our report emphasizes CADASIL-diagnostic difficulties. Movement disorders, especially dystonia, should be added to the pleomorphic clinical presentation of this condition. On the other hand, we suggest to consider CADASIL in the differential diagnosis of secondary dystonia.

Supplementary Information The online version contains supplementary material available at <https://doi.org/10.1007/s10072-021-05407-8>.

Acknowledgements The authors wish to thank our patient and his family.

Author contribution FS: study conception and manuscript writing; VP: study conception and manuscript writing; AMR: manuscript revision for intellectual content; BP: manuscript revision.

Data availability Not applicable.

Code availability Not applicable.

Declarations

Ethics approval and consent to participate The subject gave written informed consent for the publication of this case report and video files in accordance with the Declaration of Helsinki. The subject gave writ-

ten informed consent for the publication of this case report and video files in accordance with the Declaration of Helsinki.

Consent for publication The subject gave written informed consent for the publication of this case report and video files in accordance with the Declaration of Helsinki.

Conflict of interest The authors declare no competing interests.

References

1. Dichgans M, Mayer M, Uttner I et al (1998) The phenotypic spectrum of CADASIL: clinical findings in 102 cases. *Ann Neurol* 44:731–739
2. Desmond DW, Moroney JT, Lynch T et al (1999) The natural history of CADASIL: a pooled analysis of previously published cases. *Stroke* 30:1230–1233
3. Miranda M, Dichgans M, Slachevsky A et al (2006) CADASIL presenting with movement disorders: a clinical study of a Chilean Kindred. *Mov Disord* 21(7):1008–1012
4. Wegner F, Strecker K, Schwarz J et al (2011) Vascular parkinsonism in a CADASIL case with an intact nigrostriatal dopaminergic system. *J Neurol* 258:1632–1636
5. Erro R, Lees AJ, Moccia M et al (2014) Progressive parkinsonism, balance difficulties, and supranuclear gaze palsy. *JAMA Neurol* 71:104–107
6. Rago M, Berbellini A, Cacchiò G et al (2013) Parkinsonism is a Late, not rare, feature of CADASIL. A study on Italian patients carrying the R1006C mutation. *Stroke* 44:1147–1149
7. Abramycheva N, Stepanova M, Kalashnikova L et al (2015 Feb 15) New mutations in the Notch3 gene in patients with cerebral autosomal dominant arteriopathy with subcortical infarcts and leukoencephalopathy (CADASIL). *J Neurol Sci* 349(1–2):196–201

Publisher's note Springer Nature remains neutral with regard to jurisdictional claims in published maps and institutional affiliations.