

CHIASMAL APOPLEXY DUE TO INTRACHIASMATIC VASCULAR MALFORMATION RUPTURE

G. J. HANKEY

Neurology Registrar, Royal Perth Hospital, WA

M. S. KHANGURE

Consultant Radiologist, Royal Perth Hospital, WA

Abstract:

Hemorrhage from an intrinsic vascular malformation of the optic chiasm (chiasmal apoplexy) is an uncommon cause of sudden visual loss with chiasmal visual field defects.

This paper describes one case of sudden visual loss with an anterior chiasmal visual field defect due to rupture of an intrachiasmatic venous angioma and contrasts it with the clinical presentation of a case of hemorrhage from an intrachiasmatic arteriovenous malformation causing severe headache and a less apoplectic onset of visual symptoms.

The variable clinical presentation and the accuracy of high resolution post-contrast cranial CT scan in the diagnosis of intrachiasmal hemorrhage is highlighted. (*Aust NZ J Med* 1987; 17: 444-446).

Key words: Optic chiasm, vascular malformation, visual disturbance.

Sudden visual loss with chiasmal visual field defects usually suggests pituitary apoplexy due to infarction or hemorrhage within a pituitary adenoma, but less frequently it may be caused by hemorrhage from an intrachiasmatic vascular malformation. We present a case of sudden visual loss with a right superior temporal quadrantanopia caused by rupture of the intrachiasmatic venous angioma. It is compared with the uncharacteristic, less apoplectic onset of symptoms following hemorrhage from an intrachiasmatic arteriovenous malformation in case one.

CASE 1

A 36-year-old woman awoke nine days prior to presentation with a severe left temporal headache which persisted. Three days later she noted blurred vision in the left eye which did not remit. Otherwise she was asymptomatic and her past history was unremarkable.

On examination, visual acuity was 6/36 in the left eye and 6/12 in the right eye. Colour vision was severely impaired in the left eye and mildly impaired in the right eye. A left afferent pupillary defect and a partially atrophic left optic disc were present. A right (nasal half field) hemianopia and an incomplete peripheral temporal hemianopia were noted in the visual field of the left eye. An incomplete peripheral upper temporal quadrantanopia was present in the field of the right eye. The remainder of the examination was normal.

Cranial CT scan demonstrated a high density, homogeneously enhancing supra-sellar mass conforming to the shape of the optic chiasm, extending anteriorly into the left optic nerve to the optic

nerve canal and posteriorly along the line of the left optic tract. Elevation of the A1 segment of the left anterior cerebral artery was present (Figs. 1 and 2).

Four vessel cerebral angiography revealed slight elevation of the A1 segment of the left anterior cerebral artery but was otherwise normal.

Left fronto-temporal craniotomy revealed a darkened discolouration of the posterior aspect of the left optic nerve and optic chiasm. A longitudinal incision was made into the optic nerve and a hematoma expressed. Six fragments of hemorrhagic tissue (up to 0.5 cm in diameter) were obtained from the optic chiasm lesion. Histological examination showed that these consisted of a considerable amount of blood clot adjacent to collections of thin-walled blood vessels, mainly composed of collagenous adventitial tissues and abnormal glial tissue. The features were consistent with an arteriovenous malformation and evidence of recent and older hemorrhage, together with adjacent reactive glial changes.

At follow-up 18 months after her operation, her visual acuity was 6/12 in the left eye and 6/6 in the right eye. Colour vision was normal in the right eye but mildly impaired in the left eye. Visual evoked potentials, which were not performed pre-operatively, showed an absent response from the nasal half field of the left eye and an attenuated and relatively delayed response from the temporal half field of the right eye (homonymous right half fields). Attenuation of the temporal half field response from the left eye was also present. Central field stimulation failed to evoke an identifiable response from the left eye, but measured 2.4 μ V at 115 ms from the right eye. Such a combination of abnormalities was consistent with dysfunction of the fibres subserving central vision in the left eye, the left lateral aspect of the optic chiasm and the left optic tract.

Reprint requests to: Dr G. J. Hankey, Department of Neurology, Royal Perth Hospital, GPO Box 2213, Perth, WA 6001.

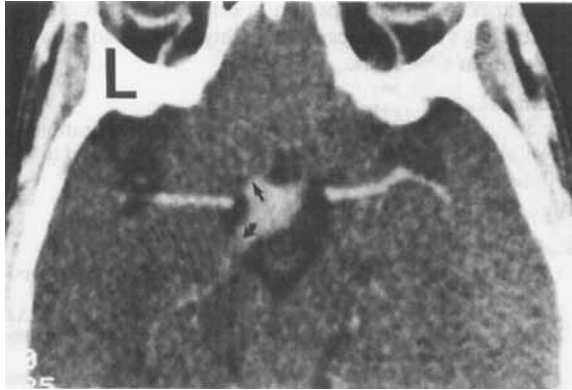

Figure 1: Post-contrast high resolution 4 mm section through the suprasellar cistern.

L = left side. There is uniform enhancement of the optic chiasm. Anteriorly this enhancement extended into the optic nerve (straight arrow) to the level of the optic nerve canal on higher sections. Posteriorly this enhancement extends into the optic tract (curved arrow).

CASE 2

A 26-year-old man presented following sudden visual loss in the left eye. On examination, visual acuity was 6/60 in the left eye and 6/9 in the right eye. Colour vision was impaired in the left eye and preserved in the right eye. A left afferent pupillary defect was present and ophthalmoscopy was normal. An incomplete temporal hemianopia was present in the visual field of the left eye and in a right superior temporal quadrantanopia in the field of the right eye (anterior chiasmal syndrome of Traquir). The examination was otherwise normal.

Cranial CT scan with contrast showed a homogeneously enhancing mass lesion in the suprasellar cistern, extending into the left optic nerve (Fig. 3). Cisternogram CT showed clearly that the suprasellar mass was entirely within the optic chiasm (Fig. 4). Carotid angiography was normal.

Left fronto-temporal craniotomy revealed a hematoma in the left optic nerve and chiasm. A longitudinal incision was made into the left optic nerve and chiasm, and the hematoma was expressed. The histological appearances of the expressed hemorrhagic tissue were those of a venous angioma.

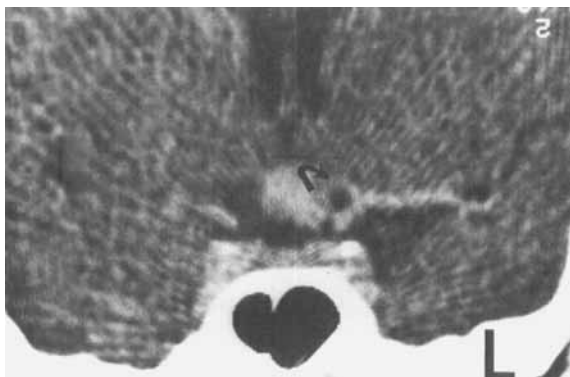


Figure 2: Post contrast 2 mm section coronal view through suprasellar cistern.

The enhancing mass occupies the mid and left side of suprasellar cistern. The left A1 segment of anterior cerebral artery (curved arrow) was elevated above the mass on other sections.

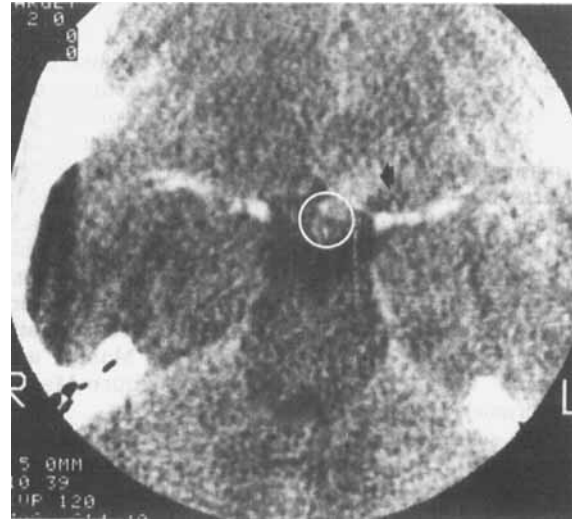


Figure 3: Post contrast 3 mm section through suprasellar cistern.

There is an enhancing mass on the left side of the suprasellar cistern (circle) with extension towards left optic nerve (short arrow).

DISCUSSION

Intrinsic vascular malformations of the optic chiasm have been reported in only ten cases,¹⁻⁸ of which nine were confirmed histologically.^{1-4,6-8} Arteriovenous malformation was present in five cases,^{3,5,6,7} cavernous hemangioma in three cases^{2,7,8} and venous angioma in two cases.^{1,4}

Hemorrhage into the optic chiasm has been reported in an additional eight cases⁹⁻¹² and termed 'chiasmal apoplexy' by Maitland *et al.*¹² In two of the cases^{10,12} the source of the hemorrhage was a chiasmatic glioma. In the remainder, the source of the bleeding was assumed to be venous cryptic vascular malformations, although no abnormal vessels were seen at the time of surgery.

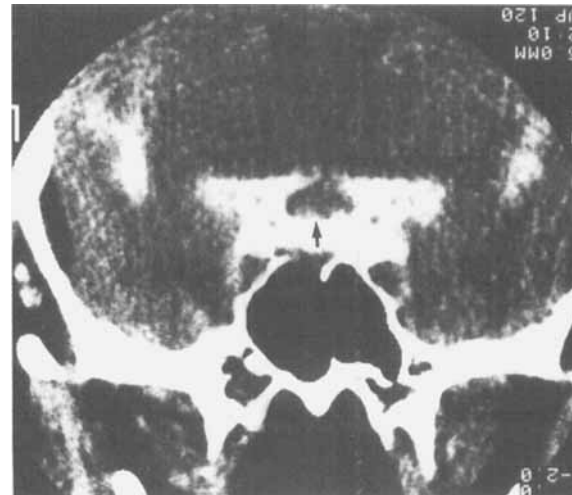


Figure 4: Coronal 3 mm section through the suprasellar cistern following intrathecal metrizamide.

There is a mass lesion in the suprasellar cistern (arrow) which represents an enlarged optic chiasm.

Chiasmal apoplexy occurs predominantly in the third or fourth decade of life with sudden onset of headache and visual loss. The headache is usually throbbing and generalised or retro-orbital, sometimes accompanied by nausea and vomiting. The visual symptoms of impaired vision are frequently bitemporal and associated with chiasmal visual field defects.⁶ Vascular malformations extrinsic to the chiasm may present with visual loss but in a less apoplectic fashion.^{13,14} Systemic symptoms and signs such as meningismus, shock or endocrine dysfunction are absent. Other vascular malformations may present including facial angioma, bulbar conjunctival angioma,¹² nasal hemangioma, telangiectatic angioma in the region of the foramen of Munro¹¹ and retinal vascular malformation (Wyburn-Mason syndrome).⁵

The sella turcica is normal on X-ray and CT scan demonstrates a high density suprasellar mass that may enhance with contrast. Although most lesions of the chiasm with these CT appearances represent a glioma or a meningioma, a vascular malformation must be considered when the history is that of sudden headache combined with acute visual disturbance.²

At craniotomy the chiasm is distended and discoloured by blood or blood products. Incision discloses either a large hematoma or cystic lesion containing dark fluid or blood. Surgical decompression may improve visual acuity and the visual field, but symptoms may also resolve spontaneously. Optic atrophy may subsequently develop and symptoms may recur.⁶

We report two cases of intrachiasmatic hemorrhage from a vascular malformation within the optic chiasm. Case 2 presented with an acute chiasmal syndrome typical of chiasmal apoplexy following hemorrhage from an intrachiasmatic venous angioma. Case 1 had a more insidious onset of headache and visual disturbance, similar to the less apoplectic onset characteristically seen with rupture of vascular malformations extrinsic to the optic chiasm. These two cases are presented to highlight

the variable clinical presentation of intrachiasmatic hemorrhage and the accuracy of high resolution cranial CT scan in diagnosis.

Acknowledgements

We are grateful to the Department of Medical Illustrations of Royal Perth Hospital for preparing the photographs and to Mrs J. Nixon and Mrs S. Mathie for secretarial assistance.

Accepted for publication: 5 May 1987.

References

1. Fermaglich J, Kattah J, Manz H. Venous angioma of the optic chiasm. *Ann Neurol* 1978; 4: 470-1.
2. Manz HJ, Klein LH, Fermaglich J, Kattah J, Luessenhop AJ. Cavernous hemangioma of optic chiasm, optic nerves and right optic tract. *Virchows Arch [Pathol Anat]* 1979; 383: 225-31.
3. Roski RA, Gardner JH, Spetzler RF. Intrachiasmatic arteriovenous malformation. Case report. *J Neurosurg* 1981; 54: 540-1.
4. Carter JE, Wymore J, Ansbacher L, Reid WS. Sudden visual loss and chiasmal syndrome due to an intrachiasmatic vascular malformation. *J Clin Neuro-Ophthalmol* 1982; 2: 163-7.
5. Hopen G, Lawton Smith J, Hoff JT, Quencer R. The Wyburn-Mason Syndrome. Concomitant chiasmal and fundus vascular malformations. *J Clin Neuro-Ophthalmol* 1983; 3: 53-62.
6. Lavin PJM, McCrary JA, Roessmann U, Ellenberger C. Chiasmal apoplexy: Hemorrhage from a cryptic vascular malformation in the optic chiasm. *Neurology (Cleveland)* 1984; 34: 1007-111.
7. Danis R, Appen RE. Optic atrophy and the Wyburn-Mason Syndrome. *J Clin Neuro-Ophthalmol* 1984; 4: 91-5.
8. Mohr G, Hardy J, Gauvin P. Chiasmal apoplexy due to ruptured cavernous hemangioma of the optic chiasm. *Surg Neurol* 1985; 24: 636-40.
9. Holt H. Cysts of the intracranial portion of the optic nerve. *Am J Ophthalmol* 1966; 61: 1166-70.
10. Schneider RC, Kriss FC, Falls HF. Pre-chiasmal infarction associated with intrachiasmatic and suprasellar tumours. *J Neurosurg* 1970; 32: 197-208.
11. Riishede J, Seedorff HH. Spontaneous haematoma of the optic chiasm: Report of a case. *Acta Ophthalmol (Copenh)* 1974; 52: 317-22.
12. Maitland CG, Abiko SM, Hoyt WF, Wilson CB, Okamura T. Chiasmal apoplexy: Report of four cases. *J Neurosurg* 1982; 56: 118-22.
13. Burnbaum MD, Harbison JW, Selhorst JB, Young HF. Blue domed cyst with optic nerve compression. *J Neurol Neurosurg Psychiatry* 1978; 41: 987-91.
14. Sibony PA, Lessell S, Wray S. Chiasmal syndrome caused by arteriovenous malformations. *Arch Ophthalmol* 1982; 100: 438-42.