

ing tremor was observed. Laboratory investigations were normal except for brucella agglutination titres of 1/80 and non-agglutinating antibodies titre of 1/1280 in the serum. CSF protein, glucose, cells were normal and cultures were negative. Brucella agglutination titres were only slightly positive (1/8). CT scan of the head disclosed no abnormality. *Brucella melitensis* was isolated from two blood cultures performed when the patient had no fever. After levodopa and bromocriptine withdrawal, treatment with doxycycline by mouth 100 mg bid, streptomycin 1 g IM daily and rifampin 600 mg daily was introduced. One month later, the patient was able to walk without assistance, but still had a mild hypokinesia and resting tremor. Doxycycline and rifampin were continued for 2 months, and the patient was discharged free of symptoms.

According to Roger and Poursine's classification, our patient suffered a late onset neurobrucellosis presenting as Parkinsonism. Though considered rare, extrapyramidal forms of neurobrucellosis have been well recorded, especially in Italian publications⁴; amongst these were two cases of subacute hemiparkinsonism.^{4,5} Unlike ours, both may be included in the early form of Roger and Poursine's, their symptoms having appeared during the course of brucellosis. In both cases, right hemiparkinsonism persisted because treatment was limited by streptomycin toxicity and the lack of new antibiotics at the time. The exact pathogenesis of Parkinsonism in brucellosis is still unknown; there is a lack of pathological studies. Gianelli⁴ suggest a focal encephalitis with circumscribed symptoms, related to concurrent treatment (there being normal CSF), probably due to an idiosyncratic immunological reaction. In our opinion, Parkinsonism unresponsive to levodopa and bromocriptine suggests a post-synaptic dopamine receptor lesion, such as corpus striatum vascular inflammation similar to that observed in syphilitic Parkinsonism.⁶ Whether this reaction is immunological and not due to direct invasion by the organism, cannot be determined only on the basis of a negative CSF culture and agglutination titre, because serine pre-treatment CSF cultures obviously are not performed. Besides, CSF agglutination titres in chronic cases are usually low, and non-agglutinating antibodies or complement-fixation titres need to be included in adequate serologic study.² Finally, we believe that previous treatment is the reason for the lack of CSF abnormality, as found in modern or partially treated neurosyphilis,⁷ especially in chronic and

encephalitic forms. All these considerations lead us to recommend serine blood cultures when suspecting brucellosis in patients with unusual neurological manifestations and normal or inconvincing CSF changes, even if fever or other general symptoms are absent. Treatment with two, three or even four drugs, including those with high CSF penetration (rifampin, trimethoprim-sulfamethoxazole), seems to be desirable⁸ but there are neither comparative studies nor large series to verify the best drug combination.

We conclude by emphasising the importance of this sometimes underestimated disease, with a marked CNS affinity, which is still far from being eradicated.

A MOLINS
J MONTALBÁN
A CODINA

*The Department of Neurology,
Vall d'Hebrón Hospital,
Barcelona,
Spain.*

Address for correspondence: Albert Molins, Av/Meridiana 30-32 Esc B 3° 1ª 08018 Barcelona, Spain.

References

- 1 Hughes ML. *Mediterranean, Malta or Undulant Fever*. London: McMillan and Company Ed. 1897.
- 2 Pedro Pons A, Foz M, Codina A. Les Neurobrucelloses. *Cahiers de Médecine (Europa Medica)* 1972;13:855-62.
- 3 Sahs AL. Brucellosis. In: *Handbook of Clinical Neurology* 1978;33:305-26.
- 4 Gianelli A. Contribution to the study of neurobrucellosis. Parainfective hemiparkinsonism with chronic development. *Riv Pat Nerv Ment* 1959;80:1135-52.
- 5 D'Amore. Emisindrome parkinsoniana nel corso della febbre di Malta. *Morgagni* 1933;75:1208.
- 6 Guillain G. Les syndromes Parkinsoniens d'origine syphilitique. *Progres Med* 1935;23:978.
- 7 Hotson JR. Modern neurosyphilis: a partially treated chronic meningitis. Medical progress. *West J Med* 1981;135:191-200.
- 8 Sanz J, Puras A, Alguacil A, Alonso F, Franch O, Damiano A. Neurobrucellosis. *Rev Clin Esp* 1985;176:349-53.

Accepted 13 July 1987

Pure word deafness and unilateral right temporo-parietal lesion: a case report

Sir: The syndrome of pure word deafness

has up until now only been reported either in patients with bilateral temporal lesions or with a unilateral lesion affecting the middle third of the superior temporal gyrus of the left temporal lobe.^{1,2} We have recently seen a patient with an agnosia predominantly for spoken words who had a unilateral right hemisphere temporo-parietal lesion demonstrated by computed tomography (CT).

The patient, a 61 year old man who lived alone, noticed one morning when he turned on his radio that he was no longer able to recognise sounds; he could not make sense of what voices were saying and could not recognise any musical tunes. He was a keen CB radio operator and reported that "it was as though the audio was quite correct and loud but I could not make out who was speaking. It was as though some of the frequencies had been chopped out". Although spoken conversation with the patient was almost impossible because of his problem interpreting speech, he was able to continue his work as a commercial artist without any apparent problems. A friend eventually persuaded him to seek medical advice. Although there was no history of any previous illness, hypertension or cardiovascular disease, an electrocardiogram showed changes of a previous, apparently asymptomatic, myocardial infarction. On examination the blood pressure was 110/70 mm Hg and the abnormalities found were confined to the nervous system. The patient's spontaneous speech was fluent, appropriate and comprehensible, though with occasional paraphasic errors. He was able to give a reasonable account of his illness. In contrast, his comprehension of the spoken word was restricted to simple direct questions about his age, name and occupation, though comprehension improved if he was aware of the context of the question. He sometimes understood other direct questions such as "how are you?", but he could not reliably obey simple commands such as "sit down" or "stand up". Repetition of spoken material was poor and limited to three digits and two simple words. He could understand the written word normally, responding rapidly and accurately to complex written commands. Object naming and reading out loud were slightly impaired. He had occasional difficulty recognising non-verbal sounds such as rattling keys and tearing paper. He reported that he was no longer able to appreciate music or recognise familiar melodies. Visuospatial and constructional abilities were normal, he was able to perform the block design test of the WAIS without difficulty and perhaps more importantly, his employers had not noticed any impairment

in his drawing skills. Handedness was assessed by informal questioning about hand, foot and eye preference for various activities, direct observation and the results of the Handedness Inventory.³ All measures used indicated strong right preference with no evidence of left hand bias. There was no family history of left handedness. Left hemisphere language representation was indicated. His IQ was estimated to be above average. Pure tone audiometry was not performed. Bedside testing of hearing was normal. The CT scan, performed 3 months after onset, showed an infarct which was predominantly in the right parietal region, with some extension inferiorly into the posterior temporal lobe (fig). There was no evidence of any abnormality in the left hemisphere.

We postulate that our patient's word deafness was due to the right temporo-parietal lesion seen on CT. Patients with tumours of, or injury to, the right hemisphere may develop "crossed" aphasia, though such lesions may cause aphasia by pressure or distortion of the left hemisphere.⁴ Lesions in the non-dominant temporal lobe have been reported to produce an agnosia for non-verbal sounds with preserved comprehension of the spoken word⁵ and impaired appreciation of music.^{6,7} Spreen⁸ described a man with an agnosia for non-verbal sounds, but intact language comprehension. He had had a stroke causing a marked left hemiparesis and subsequently developed emotional lability, seizures and bilateral pyramidal signs. Handedness was not tested. At necropsy, the patient had bilateral subdural haematomas and a very extensive area of infarction in the

right, presumably non-dominant, hemisphere in the fronto-temporo-parietal areas. In contrast, our patient had only a single clinical episode, a more restricted neuropsychological deficit and a smaller lesion. Nonetheless, although the relationship of the lesion to the deficit appears much clearer, other possibilities must be considered: it is possible that there was infarction of the contralateral hemisphere, not visible on the CT scan; it is also possible that the patient was right hemisphere dominant for language (or had bilateral language representation), despite his strong right-handed preference. However, since all these alternative explanations seem unlikely, we conclude that the right hemisphere infarct was the cause of our patient's pure word deafness.

MARK ROBERTS

PETER SANDERCOCK

Fazakerly Hospital, Liverpool

ERIC GHADIALI

Walton Hospital,

Rice Lane,

Liverpool L9 1AE, UK

References

- 1 Buchman AS, Garron DC, Trost-Cardamone JE, Wichter MD, Schwartz M. Word deafness: one hundred years later. *J Neurol Neurosurg Psychiatry* 1986;49:489-99.
- 2 Kirshner HS. *Behavioural Neurology. A Practical Approach*. New York; Churchill Livingstone 1986.
- 3 Briggs GG, Nebes RD. Patterns of hand preference in a student population. *Cortex* 1975;11:230-8.
- 4 Benson FD. *Aphasia, Alexia and Agraphia*. New York; Churchill Livingstone 1979:145.
- 5 Hécaen H. Clinical symptomatology in right and left hemisphere lesions. In: Mountcastle VB (ed), *Interhemispheric Relations and Cerebral Dominance*. Baltimore, Johns Hopkins 1962.
- 6 Milner B. Interhemispheric differences in the localisation of psychological processes in man. *Br Med Bull* 1971;27:272.
- 7 Shankweiler DP. Performance of brain-damaged patients on two tests of sound localisation. *J Comp Physiol Psychol* 1961;54:375.
- 8 Spreen O, Benton AL, Fincham W. Auditory agnosia without aphasia. *Arch Neurol* 1965;13:84-92.

Accepted 26 June 1987

Photosensitivity related to valproate withdrawal

Sir: Photosensitive epilepsy comprises patients in whom seizures are provoked by environmental flicker stimulation.^{1,2} Gener-

alised epileptic discharges are evoked by intermittent photic stimulation, constituting a photoconvulsive response.³ Sodium valproate is the drug of choice for photosensitive epilepsy. Three patients are reported who developed photosensitivity related to sodium valproate withdrawal.

The first case was a 47 year old man who had had four generalised tonic-clonic convulsions, nocturnal or on awakening, from 18 years to 24 years of age. He was seizure-free until 36 years of age, off phenobarbitone therapy since aged 29. Sodium valproate treatment (15 mg/kg/die, plasma level 73.3 µg/ml) was started at 36 years of age because of a relapse with a morning generalised convulsion. EEG initially showed generalised spike and wave discharges at rest and during hyperventilation and then normalised. Intermittent photic stimulation always had no effect. There was gradual sodium valproate reduction at 45 years of age. Six months later, on 5 mg/kg/die of sodium valproate (plasma level 18.5 µg/ml) for 3 weeks, he suffered from two tonic-clonic convulsions when watching television. EEG showed generalised epileptic discharges, evoked by intermittent photic stimulation. Sodium valproate dosage was increased to 10 mg/kg/die (plasma level 44.0 µg/ml). He was seizure-free for the following year and photoconvulsive response disappeared.

A 32 year old man had two morning generalised convulsive seizures at 20 and 22 years of age. EEG showed generalised discharges during hyperventilation but no paroxysmal response to intermittent photic stimulation (fig). Sodium valproate therapy (13 mg/kg/die, plasma level 62.7 µg/ml), started after the second fit, controlled the seizures and normalised the EEG. Sodium valproate was gradually stopped at 30 years of age. Three weeks after drug withdrawal he had a tonic-clonic convulsion while using a video-computer. EEG showed generalised epileptic discharges exclusively during intermittent photic stimulation (fig). On phenobarbitone treatment (1.5 mg/kg/die) there was no seizure recurrence and no abnormal response to intermittent photic stimulation for the following 2 years.

The third case was a 16 year old girl who otherwise neurologically normal had two nocturnal clonic seizures involving the right half of the face at 8 and 9 years. CT of the head was normal. EEG showed left centro-temporal sharp waves but no photoconvulsive response. EEGs of the parents and the older sister were normal. Sodium valproate therapy (20 mg/kg/die), started following the first seizure, was gradually

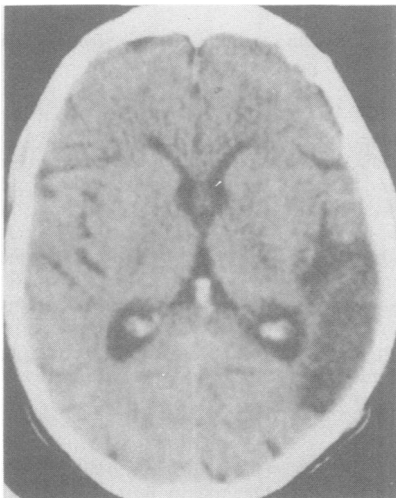


Fig CT scan showing infarction in the right temporo-parietal area.