

# Higher Cortical Disorders: An Unusual Presentation of an Arteriovenous Malformation

J. J. v. Overbeeke, M.D., N. J. Bosma, M.D., A. F. M. M. Verdonck, M.D., and A. C. v. Huffelen, M.D.

*Department of Neurosurgery (JJO, NJB), Department of Neuropsychology (AFMMV), and Department of Clinical Neurophysiology (ACH), University Hospital, Utrecht, The Netherlands*

The authors present a patient with a large arteriovenous malformation in the temporoparietooccipital region of the dominant hemisphere that caused seizures, a homonymous hemianopia, and broad neuropsychological disturbances probably caused by a cerebral steal syndrome. There was no history of hemorrhage. Surgical resection resulted in marked improvement of neuropsychological function and disappearance of the hemianopia. The authors discuss the pre- and postoperative neuropsychological findings, the pathogenesis of the steal phenomenon, and the indications concerning the resection of this large and deep-seated arteriovenous malformation in a functionally important region of the left hemisphere. They state that surgical resection is the method of choice. (*Neurosurgery* 21:839-842, 1987)

**Key words:** Cerebral steal phenomenon, Intracranial arteriovenous malformation, Neuropsychological deficit, Resection

The interest in surgical management of arteriovenous malformations (AVMs) has increased because of more frequent and earlier detection, improvement in microsurgical vascular operative techniques and anesthesiological techniques, and understanding of the anatomy and hemodynamics of AVMs. AVMs commonly present with intracranial hemorrhage, seizures, vascular headache such as migraine, and progressive heart failure in some cases. Far less attention has been given to the presentation of progressive or fluctuating neuropsychological deficits as a result of a "cerebral steal" phenomenon.

We present an unusual case of neuropsychological deterioration caused by a large temporoparietooccipital AVM situated laterally close to the border of the left ventricular trigone. In addition to the risk of bleeding, the neuropsychological disturbances indicated the necessity for surgical resection.

## CASE REPORT

A right-handed, 16-year-old girl suffered from progressive headache. One year after the onset of the headache, she had a partial seizure with complex symptoms characterized by loss of spatial orientation and consciousness. Later, a generalized tonic-clonic seizure was noted.

Physical examination revealed no neurological deficit. Some weeks after the tonic-clonic seizure, the patient complained of disturbances in writing, reading, calculating, and spatial orientation.

On admission, she was found to have a complete right-sided hemianopia, with no other neurological deficit. Electroencephalography (EEG) indicated functional disturbances in both superficial and deep layers of the left temporal-occipital region, with slight epileptiform characteristics. There was asymmetry of the background activity in the posterior temporal and occipital regions. The  $\alpha$  rhythm at the left side was much slower than that at the right side. Moreover, there was an excess of irregular slow activity with a diminution of fast activity at the left side. The photic driving reactions were also asymmetrical. Sporadically, there were some sharp waves in the left posterior temporal region. The computed tomographic (CT) scan showed a tortuous enhancement close to the left trigonum (Fig. 1).

The cerebral angiogram showed an AVM supplied by

branches of the left posterior cerebral artery draining into the left transverse sinus (Figs. 2 and 3).

Neuropsychological investigation (Table 1) showed several remarkable disturbances: there was an indication of deterioration of intellectual cognitive functions, especially of the performance tasks of the WISC-R, but also of verbal tasks. She had a very short attention span. There were also some indications of a disturbance of short term memory and of retention of visual information. There were severe problems in visual perception. Spatial perception and organization were insufficient, and visual analysis and synthesis were severely disturbed, probably because of the hemianopia. There was a pathological narrowing of the range of the visual field and a simultaneous agnosia; only small parts or details of objects, figures, words, and numbers were perceived, and this only in the left part of the visual field. There was a total alexia and she even did not recognize normal symbols, words, or her own writing; she could not read musical notes, although she had played music for several years. Although her mental arithmetic function was normal, she did not recognize mathematical and chemical formulas and constructions on paper. Indications of constructive apraxia were also present. The whole complex of neuropsychological disturbances was a clear indication of a functional disturbance of the parietooccipital region of the left hemisphere. There was dysfunctioning of the left occipitotemporal region especially.

At operation (N.J.B.), a temporoparietooccipital craniotomy was performed. When the dura mater was exposed, the intracranial tension was found to be too high. With the aid of hypotensive anesthesiological techniques, the intracranial pressure was lowered. After incision of the dura mater, a large red draining cerebral vein was visible on the temporal lobe, close to the sigmoid sinus. First, the left posterior cerebral artery was exposed by means of a subtemporal approach. Two feeding arteries coming from the posterior cerebral artery were clipped. This procedure did not diminish the volume of the draining veins.

Because of the high intracerebral pressure, the temporal lobe could not be mobilized further. Therefore, other feeding arteries could not be found under the temporal lobe.

A transtemporal approach along the draining vein to the malformation was chosen. The malformation was found very

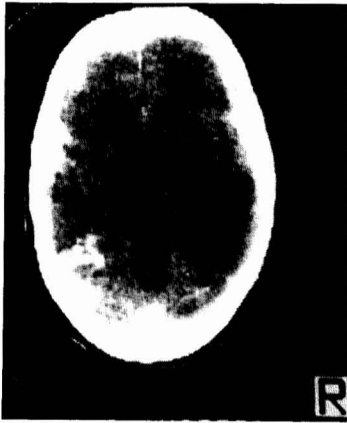


FIG. 1. CT scan with contrast enhancement showing a large left parietal-occipital AVM.

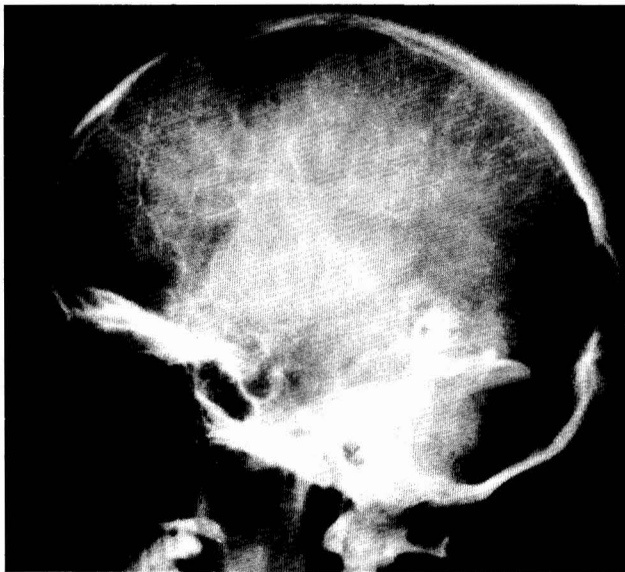


FIG. 2. Venous phase of the left internal carotid angiogram showing a large AVM draining into the left transverse sinus.

close to the left posterior portion of the lateral ventricle. First, the feeding arteries were identified and clipped. When the malformation was completely loose from the surrounding brain tissue, the draining veins were coagulated, and the malformation was removed as a whole. There were no signs of previous bleeding from the anomaly.

On the 1st day after the operation, the hemianopia had disappeared. EEG during the postoperative period showed an asymmetry similar to that found before operation.

The neuropsychological investigation (Table 1) was repeated 3 weeks after the operation. There was improvement in almost all functions, but cognitive functions were still less than the estimated premorbid level and visual analysis and synthesis were still weak; furthermore, information-processing was slower than normal. Visual memory and reproduction of visual information had improved, but were still not normal. Concentration and attention span were better than before the operation, but not yet normal. The simultaneous agnosia had disappeared. There were no more signs of alexia and constructive apraxia. Spatial perception and organization had improved considerably. There were still disorders in interpretation, however; the understanding and use of written mathe-

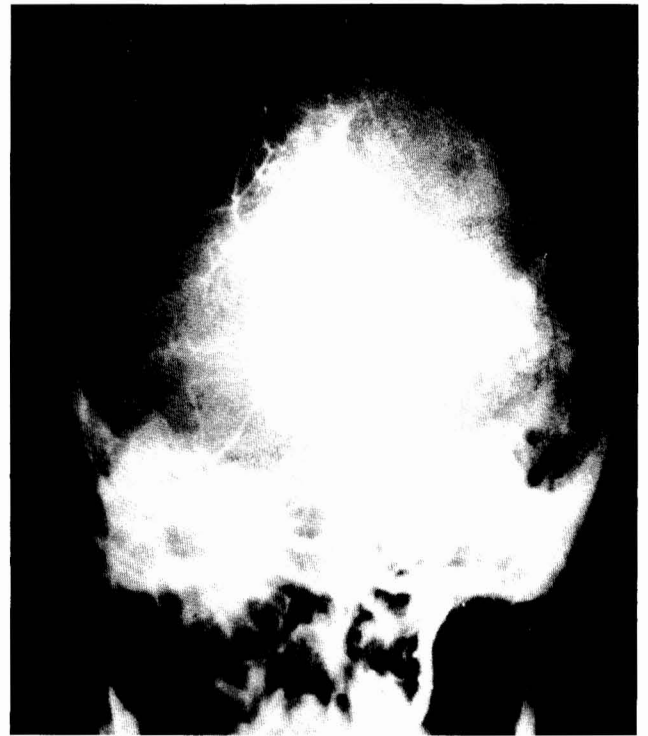


FIG. 3. Left vertebral angiogram showing feeding branches from the posterior cerebral artery to the AVM.

tical and chemical formulas and constructions was practically impossible.

Three months after the second neuropsychological investigation, the patient had no more problems with visual perception, reading and writing, memory, and recognition of objects and symbols. Dyscalculia and alexia had disappeared almost totally, and spatial perception and orientation were normal.

One year after the operation, neuropsychological investigation was repeated once more. Intellectual-cognitive functions had improved, but the patient still showed somewhat more difficulty in performance tasks (visuoconstructive tasks) than in verbal tasks. All other functions were normal, except attention span and pace of work. She was given counseling for her school problems because of depression and emotional problems that she developed after the operation. She still receives psychological therapy. Antiepileptic treatment was given, and the seizures did not recur.

#### DISCUSSION

The concept that an AVM can interfere with circulation in the surrounding brain tissue has been discussed by several authors (3, 5, 6, 16, 17, 23). Terms such as "parasite of the circulation" and "thirsty lesion" have been used (5, 6). The excessive shunt flow through the AVM causing a state of permanent insufficient perfusion of viable tissue has been termed "cerebral steal" (6). Nornes and Grip described the hemodynamic aspects of cerebral AVMs (16, 17), stating that the pressure drop in the feeding artery of an AVM is proportional to the resistance of this vessel and the flow through the AVM. A long feeding artery has a comparatively high resistance due to friction. The shunt flow through the AVM is not considered influenced by autoregulation. Therefore, the flow is extremely pressure-dependent and can be high in a large AVM. The flow through an AVM may range from 1 to 3

TABLE I  
Neuropsychological Tests<sup>a</sup>

Test	At school	Preoperative	3 wk postop	15 wk postop	10 mo postop
1. WAIS (subtests)					
Digit Span	12	11	11	11	12
Arithmetic	13	10	10	10	10
Similarities	12	12	12	12	12
Block Design	13	10	10	11	12
Object Assembly	12	10	10	9	15
Digit Symbol	12	0	8	10	10
2. Bourdon-Wiersma (Dutch paper and pencil attention-concentration test)		1	2	3	3
3. Benton Visual Retention Test		1	2	2	4
4. 15 Words Auditive Verbal Memory Test		1	3	3	4
5. Hooper Visual Organization Test		2	3	3	3
6. Ayres Figure Ground Visual Perception test		3	2	4	4
7. Grassi Block test		3	4	4	4
8. Bender Visuo-Motor Gestalt test		2	3	3	3
9. Vigilance Task, Reaction Time (continuous performance task)		1	2	2	3
10. Halstead-Reitan					
Trailmaking		2	3	3	3
Tactual Performance		2	3	3	3
Finger Tapping		2	1	3	3
11. Motor Performance Task					
Steadiness		3	4	4	4
Tapping		3	1	3	3
Trace Tracking		2	3	3	3
Pegboard		3	3	4	4

<sup>a</sup> The neuropsychological tests were administered in the order listed. Scoring: much below average = 1, below average = 2, average = 3, above average = 4, much above average = 5.

litres of blood per minute, sometimes causing a serious load on the heart (6). Thus, the greater the shunt through the AVM and the larger the caliber of the feeding arteries, the greater the pressure drop in the feeding arteries. The perfusion pressure through the nutrient vessels of the surrounding brain tissue is dependent on the arterial pressure minus the venous pressure. In the case of a large AVM, such as in our patient, the peripheral tissue perfusion is decreased because of a great pressure drop in the feeding artery and an increased venous pressure. Evidence of an increased venous pressure is obtained from observations of dilated arteriolized veins produced by the transmission of arterial pressure directly into the veins.

The permanent state of insufficient tissue perfusion may cause several disturbances related to the location of the AVM. Among these, real neuropsychological disturbances are less commonly described. Several cases of intellectual changes resulting from an AVM have been reported. There is a sparsity of reported cases of documented neuropsychological deficit, however. Most authors only report the possibility of or present some examples of decreased intellectual function caused by an AVM (2, 3, 11, 14, 25). The earlier literature reported psychiatric disorders caused by AVMs. Tonnis reported personality changes in 9.5% of the patients with AVMs (22). Hamilton Paterson found "dementional" disorders in 8% (8), and Kelly found such disorders in 9.5% of patients with supratentorial AVMs (10). Almost all authors refer to the effects of the steal phenomenon as the cause of these disturbances. In most cases, other deficits have been described, such as seizures and neurological deficit.

The decision of whether to operate on a large AVM that

has not bled and is situated in functionally important regions requires one to weigh natural risks against surgical risks (1, 2, 9, 11-13, 20, 24-26). The yearly rate of initial hemorrhage is between 2% and 3%, with a considerable mortality and morbidity of 10 to 30%. The accumulated risk of bleeding at 20 years is 37% (7, 12). The natural incidence of spontaneous disappearance of intracranial AVMs is estimated at 2 to 5%. This phenomenon is primarily caused by acute thrombosis, with a time interval from diagnosis to disappearance of 7 months to 21 years (19). Although a large AVM is less likely to bleed (12, 18), Drake frequently found blood around large AVMs during excision (4). It is possible that symptoms ascribed to the steal phenomenon are really those of repeated minor bleeding.

We do not agree with Ianesk that conservative treatment is the appropriate management of an AVM that has not bled (9). Apart from the considerable risk of bleeding in the case of a young patient with an AVM there are other indications for operation, such as disabling neurological and neuropsychological disturbances.

Because of careful microdissection techniques, the use of embolization as a preliminary step, hypotensive anesthesiological techniques, and the preoperative avoidance of abrupt hemodynamic changes by gradual occlusion of the feeders, the surgical risk has been decreased considerably (2, 4, 11, 12, 15, 18, 20, 21, 25). The surgical mortality and morbidity has ranged from 2% (20) to 11% (4) in many series (1, 2, 11, 13, 18, 21, 25, 26). The statistical variance depends on the preoperative condition of the patient, the location and size of the anomaly, and the operative procedure.

To evaluate the pre- and postoperative state of patients with AVMs in the temporoparietal region of the dominant hemisphere, we used neuropsychological tests. We suggest the following as the most useful: WAIS, Benton Visual Retention Test, 15-Words Auditive Verbal Memory Test, Motor Performance Task, Bender Visuo-Motor Gestalt Test, Grassi Block Test, Reaction Time Test (continuous performance-vigilance task), and some subtests of the Halstead-Reitan Neuropsychological Battery (Trail Making, Tactual Performance, Finger Tapping, and Aphasia Screening Test).

To prevent hemorrhage and progressive ischemic damage of the brain tissue adjacent to the AVM, we decided that surgical removal of this anomaly was the method of choice.

Received for publication, October 21, 1986; accepted, June 23, 1987.

Reprint requests: J. J. v. Overbeek, Department of Neurosurgery, University Hospital, Catharijnesingel 101, 3511 6V Utrecht, The Netherlands.

#### REFERENCES

- Adelt D, Zeumer H, Wolters J: Surgical treatment of cerebral arteriovenous malformations: Follow-up study of 43 cases. *Acta Neurochir (Wien)* 76:45-49, 1985.
- Davis CH, Symon L: The management of cerebral arteriovenous malformations. *Acta Neurochir (Wien)* 74:4-11, 1985.
- Deutsch G: Blood flow changes in arteriovenous malformation during behavioural activation. *Ann Neurol* 13:38-43, 1983.
- Drake CG: Cerebral arteriovenous malformations: Considerations for and experience with surgical treatment in 166 cases, in Carmel PW (ed): *Clinical Neurosurgery*. Baltimore, William & Wilkins, 1979, vol 26, pp 145-208.
- Feindel W, Perot P: Red cerebral veins: A report on arteriovenous shunts in tumors and cerebral scars. *J Neurosurg* 22:315-325, 1965.
- Feindel W, Yamamoto YL, Hodge CP: Red cerebral veins and the cerebral steal syndrome: Evidence from fluorescein angiography and microregional blood flow by radioisotopes during excision of an angioma. *J Neurosurg* 35:167-179, 1971.
- Graf CJ, Perret GE, Torner JC: Bleeding from cerebral arteriovenous malformations as a part of their natural history. *J Neurosurg* 58:331-337, 1983.
- Hamilton Paterson J, McKissock W: A clinical survey of intracranial angiomas with special reference to their mode of progression and surgical treatment: A report of 110 cases. *Brain* 79:233-266, 1956.
- Ianesk R, Elstein A, Balla J: Application of decision analyses to management of cerebral arteriovenous malformation. *Lancet* 1132-1135, 1983.
- Kelly DL, Alexander E, Davis CH, Maynard DC: Intracranial arteriovenous malformations: Clinical review and evaluation of brain scans. *J Neurosurg* 31:422-428, 1969.
- Kunc Z: Surgery of arteriovenous malformations in the speech and motor sensory regions. *J Neurosurg* 40:293-303, 1974.
- Luessenhop AJ, Rosa L: Cerebral arteriovenous malformations: Indications for and results of surgery, and the role of intravascular techniques. *J Neurosurg* 60:14-22, 1984.
- Martin NA, Edwards MSB, Wilson CB: Management of intracranial vascular malformations in children and adolescents, in Humphreys RP (ed): *Concepts in Pediatric Neurosurgery*. Basel, Karger, 1983, vol 4, pp 264-290.
- Michelsen WJ: Natural history and pathophysiology of arteriovenous malformations, in Carmel PW (ed): *Clinical Neurosurgery*. Baltimore, William & Wilkins, 1979, vol 26, 307-313.
- Mingrino S: Supratentorial arteriovenous malformations of the brain, in Krayenbuhl H (ed): *Advances and Technical Standards in Neurosurgery*. Zurich, Springer Verlag, 1978, vol 5, pp 93-123.
- Nornes H, Grip A: Hemodynamic aspects of cerebral arteriovenous malformations. *J Neurosurg* 53:456-464, 1980.
- Nornes H, Grip A, Wikeby P: Intraoperative evaluation of cerebral hemodynamics using directional Doppler technique. *J Neurosurg* 50:145-151, 1979.
- Parkinson D, Bachers G: Arteriovenous malformations: Summary of 100 consecutive supratentorial cases. *J Neurosurg* 53:285-299, 1980.
- Pasqualin A, Vivenza C, Rosta L, Scienza R, Da Pian R, Colanelli M: Spontaneous disappearance of intracranial arteriovenous malformations. *Acta Neurochir (Wien)* 76:50-57, 1985.
- Stein BM, Wolpert SM: Arteriovenous malformations of the brain: Part II. Current concepts and treatment. *Arch Neurol* 37:69-75, 1980.
- Suzuki J, Onuma T, Kayama T: Surgical treatment of intracranial arteriovenous malformation. *Neurol Res* 4:191-207, 1982.
- Tonnis W, Schieffer W, Walter W: Signs and symptoms of supratentorial arteriovenous aneurysms. *J Neurosurg* 15:471-480, 1958.
- Tranmer BI, Kindt GW: High altitude: An unusual case of neurological deterioration in a patient with an arteriovenous malformation. *Neurosurgery* 17:320-323, 1985.
- Wilkins RH: Natural history of intracranial vascular malformations: A review. *Neurosurgery* 16:421-430, 1985.
- Wilson CB, U HS, Domingue J: Microsurgical treatment of intracranial vascular malformations. *J Neurosurg* 51:446-454, 1979.
- Yamada S: Arteriovenous malformations in the functional area: Surgical treatment and regional cerebral blood flow. *Neurol Res* 4:283-322, 1982.

#### COMMENT

The authors present a patient with a left temporoparietooccipital arteriovenous malformation. The clinical presentation consisted of a right homonymous hemianopsia, seizures, and a severe left temporal parietal cognitive deficit. The arteriovenous malformation had never bled. The importance of this report lies in its recognition of and emphasis on the severe disruption of the normal cortical functions occurring in the temporoparietooccipital junction on the left side due to an apparent steal phenomenon. The authors document the reversal of these cognitive deficits after removal of the arteriovenous malformation. The authors' conclusion, which is clearly supported by this case report, is that the potential reversible effects of the steal phenomenon due to arteriovenous malformation should be considered when decisions regarding the treatment of arteriovenous malformations are being made.

Charles J. Hodge, Jr.  
Syracuse, New York