



Intracranial thrombosis after ventriculoperitoneal shunting

Nayara M. Pereira¹ · Luiz A. Vieira Netto¹ · Luís Felipe A. Peres¹ · Alice J. Zaccariotti¹ · Lígia G. Ribeiro² · Paulo Ronaldo Jubé Ribeiro¹

Received: 2 June 2021 / Accepted: 2 August 2021

© The Author(s), under exclusive licence to Springer-Verlag GmbH Germany, part of Springer Nature 2021

Abstract

We report a case of intracranial thrombosis (IT) after ventriculoperitoneal shunting (VPS). We reviewed the literature to highlight the importance of considering the possibility of cerebral venous thrombosis following VPS, even though it is a rarely reported complication. A 14-year-old boy underwent distal catheter replacement due to its short size that was detected during a routine consultation. Five days postoperatively, he experienced nausea, vomiting, seizures, and headache. Although a diagnosis of meningitis was considered, diagnosis of IT was eventually confirmed through computed tomography venography and gadolinium magnetic angioresonance. The patient subsequently underwent anticoagulant therapy, which led to complete resolution of symptoms. In this report, we suggest a possible association between VPS and IT, which is a complication that is not commonly reported. The literature suggests that decreased blood flow due to over-drainage of CSF after VPS causes decreased head pressure, culminating in venous stasis and consequent thrombosis. In addition, the literature describes associations between IT and lumbar puncture (LP); therefore, it is important to consider the possibility of IT following these procedures.

Keywords Intracranial thrombosis · Ventriculoperitoneal shunt · Complications · Heparin

Introduction

Hydrocephalus is the accumulation of cerebrospinal fluid (CSF) in the cerebral ventricles; CSF accumulation may occur due to flow obstruction, impaired absorption, overproduction, brain hemorrhage, or infection and can have several consequences, such as brain herniation and death. Hydrocephalus has an estimated prevalence of 1.1 per 1000 infants and a mortality rate of 0–3%, depending on the follow-up, and may occur in genetic conditions with malformations that cause cerebral aqueduct stenosis [1, 2]. Surgical treatment with shunt placement is the first-choice treatment option in this condition [2–4].

Ventriculoperitoneal shunting (VPS) is a relatively simple procedure that is commonly performed for the treatment

of hydrocephalus [5]. It involves creating a connection that leads to the drainage of excess CSF from the ventricles to the abdominal cavity [6]. There are several potential complications of VPS, including intracranial thrombosis (IT), which is rare [5, 7]. We found only two other cases of IT after VPS in the literature [8, 9].

Case report

At 4 months of age, the patient was diagnosed with hydrocephalus secondary to aqueduct stenosis, for which he underwent an endoscopic third ventriculostomy (ETV). Two months postoperatively, the patient returned with ETV failure; consequently, VPS was indicated. The VPS was performed with no complications, and he has since lived a normal life, undergoing routine annual follow-up visits.

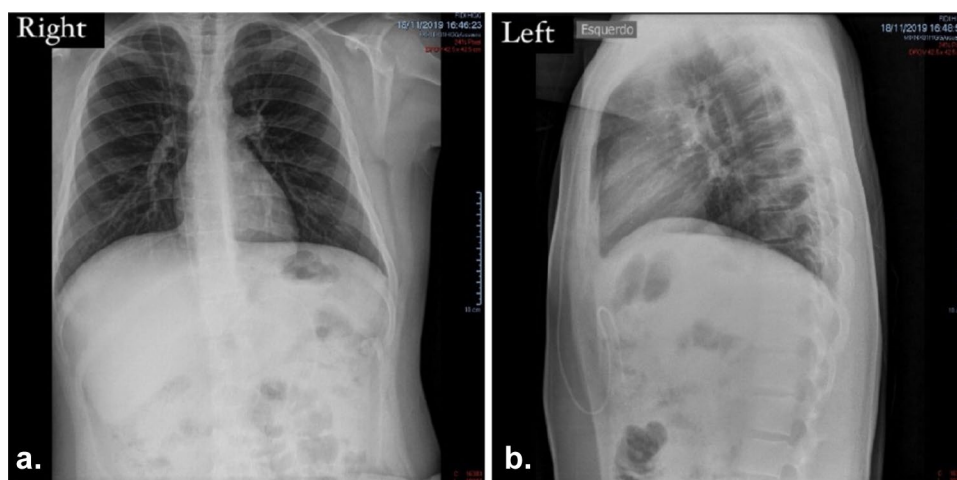
At 14 years old, during one of the patient's follow-up visits, an abdominal radiography revealed that the catheter had become short for his size (< 10 cm in the abdomen) due to his growth (Fig. 1a, b). A revision surgery for the replacement of the distal catheter was subsequently scheduled according to the service protocol.

✉ Nayara M. Pereira
naymp_naymp@hotmail.com

¹ Federal University of Goiás, Setor Leste Universitário, Rua 235, Goiânia, GO 74605-050, Brazil

² UniEVANGÉLICA Medical School, Avenida Universitária, Km 3,5, Cidade Universitária, Anápolis, GO 75083-515, Brazil

Fig. 1 Abdominal radiography showing that the catheter was short for the patient due to his growth. **a** posteroanterior radiography; **b** profile radiography



The results of the preoperative blood count and coagulations tests were within the normal range.

The shunt review was performed through an incision in the region of the valve, followed by replacement of the catheter located in the region from the neck to the abdomen, with no intracranial manipulation. The procedure was performed with no intraoperative complications, and control computed tomography (CT) imaging after the procedure showed no spontaneous hyperdensity of the sinuses (Fig. 2).

The intraoperative routine CSF analysis showed no alterations.

However, 5 days after the procedure, the patient was readmitted due to a pulsating headache of low-to-moderate intensity, which decreased when lying down, and light neck stiffness. Additionally, he reported nausea and vomiting, with abdominal pain adjacent to the surgical wound. The patient

had a Glasgow Coma Scale score of 15 without deficits, and the VPS was functional on palpation. Moreover, the patient had generalized tonic–clonic seizures.

A CT scan showed a VPS catheter well-positioned in the right lateral ventricle, and the presence of subarachnoid hemorrhage, mild diffuse cerebral edema, and spontaneous hyperdensity of the right transverse sinus, leading to the diagnostic hypothesis of IT (Fig. 3).

Blood examination results after readmission showed a normal leukocyte count of $11,800/\text{mm}^3$ (84% neutrophils) and CRP level of 1.9 mg/dL. Simultaneously, lumbar puncture (LP) results showed hematic CSF with normal glucose and protein levels, with no bacterial or fungal growth detected in the CSF culture, ruling out possible meningitis.

The empty delta sign was observed on CT venography, which confirmed the diagnosis of IT (Fig. 4). We observed

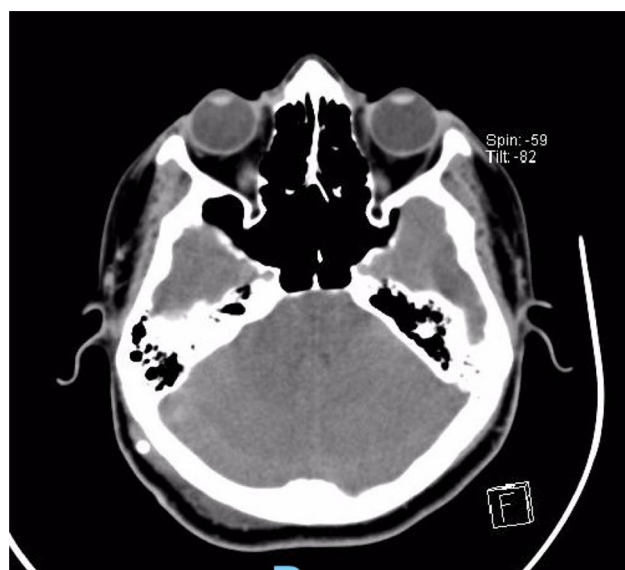


Fig. 2 Routine immediate postoperative brain computed tomography showing that there was no spontaneous hyperdensity

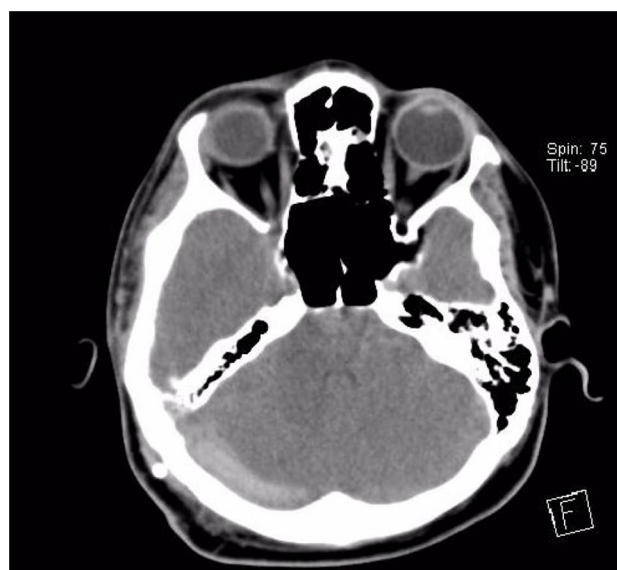


Fig. 3 Brain computed tomography on the first day after readmission showing spontaneous hyperdensity in the right transverse sinus

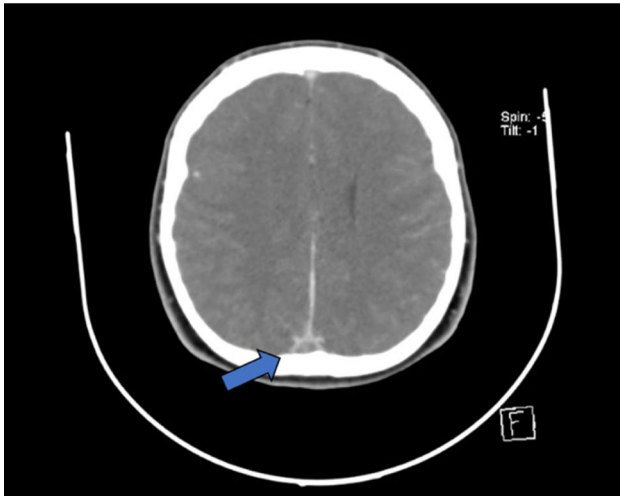


Fig. 4 CT venography showing the empty delta sign (arrow)

signs of cerebral venous thrombosis affecting the upper sagittal sinus, and the right transverse and sigmoid sinuses, which further confirmed the diagnosis of IT. Typical components of a thrombophilia blood panel were tested, including antiphospholipid antibodies. No cause of thrombophilia was identified.

Based on the diagnosis of IT, anticoagulation therapy was performed with a therapeutic dose of the low-molecular-weight heparin, enoxaparin, followed by warfarin. The patient showed complete resolution of his symptoms in less than a day.

Discussion

IT can be caused by any condition that leads to a prothrombotic state. It is commonly related to pregnancy, oral contraceptive use, genetics, thrombophilia, chronic inflammatory diseases, meningitis, otitis or other local infections, and head injury [10, 11].

Thrombus formation can be explained by the Virchow triad, which includes vascular wall injury, hypercoagulability, and venous stasis. Matsubara et al. have reported on IT following VPS in an adult in whom radiological examination clearly demonstrated thrombus formation immediately adjacent to the shunt catheter [5]. Since our patient was still growing, we only performed surgery to exchange the catheter, and a cerebral incision was not needed. The possibility of vascular injury was ruled out as there was no direct contact with the brain sinuses [5, 7].

It is possible that the IT was caused by over-drainage following the VPS, which can cause decreased intracranial pressure, culminating in venous stasis and consequent thrombosis [8]. Furthermore, the possibility of dehydration

being the cause for IT was ruled out due to the chronology of the symptoms, which started with headaches and progressed to vomiting [7, 10, 12]. Moreover, the patient's symptoms appeared 5 days postoperatively and before the lumbar puncture, which increases the possibility of over-drainage being the cause of his symptoms.

IT after LP is rare; only 20 cases were reported until 2002, and there were encountered cases of IT that occurred after diagnostic LP, therapeutic LP, and epidural for obstetrical procedures, totalizing 47 cases [13, 14]. Most patients were treated with anticoagulants, and the majority had favorable clinical improvement [13, 15, 16].

This case highlights the need for vigilance when performing VPS. Assessment of possible risk factors for thrombosis, evaluation of the surgical site for injuries, and maintenance of adequate pressure should be performed [5–7, 10, 12, 17, 18]. Additionally, risks associated with LP should be evaluated.

Conclusion

To summarize, IT after VPS in our patient might have been caused by decreased blood flow after the VPS, leading to venous stasis and consequent thrombosis. The incidence of IT as a complication of VPS may be underestimated, leading to underdiagnosis, undertreatment, and poor prognosis. Therefore, although further studies are needed to confirm the association between IT and VPS, we conclude that close monitoring of patients undergoing VPS is warranted to quickly identify complications such as IT and improve the patient's prognosis.

Author contribution Nayara Matos Pereira and Paulo Ronaldo Jubé Ribeiro supervised the writing of this work. Nayara Matos Pereira was also responsible for reviewing medical records and gathering the exam results. Luiz Alves Vieira Netto, Luís Felipe Araújo Peres, Alice Jardim Zaccariotti, and Lígia Gonsalves Ribeiro did a literature review and wrote the paper. All the authors discussed the case and contributed to the final report of the case.

Declarations

Conflict of interest The authors declare no competing interests.

References

1. Farb R, Rovira A (2020) Hydrocephalus and CSF Disorders. In: Hodler J, Kubik-Huch RA, von Schulthess GK (eds) *Diseases of the Brain, Head and Neck, Spine 2020–2023: Diagnostic Imaging*. IDKD Springer Series. Cham (CH), pp 11–24. https://doi.org/10.1007/978-3-030-38490-6_2
2. Koleva M, De Jesus O (2021) Hydrocephalus. In: StatPearls [Internet]. Treasure Island (FL): StatPearls Publishing; 2021 Jan-. Available from: <https://www.ncbi.nlm.nih.gov/books/NBK560875/>

3. Kahle KT, Kulkarni AV, Limbrick DD Jr, Warf BC (2016) Hydrocephalus in children. *Lancet* 387:788–799. [https://doi.org/10.1016/S0140-6736\(15\)60694-8](https://doi.org/10.1016/S0140-6736(15)60694-8)
4. Tully HM, Dobyns WB (2014) Infantile hydrocephalus: a review of epidemiology, classification and causes. *Eur J Med Genet* 57:359–368. <https://doi.org/10.1016/j.ejmg.2014.06.002>
5. Matsubara T, Ayuzawa S, Aoki T, Ikeda G, Shiigai M, Matsumura A (2014) Cerebral venous thrombosis after ventriculoperitoneal shunting: a case report. *Neurol Med Chir (Tokyo)* 54:554–557. <https://doi.org/10.2176/nmc.cr2012-0312>
6. Fowler JB, De Jesus O, Mesfin FB (2021) Ventriculoperitoneal Shunt In: StatPearls [Internet]. Treasure Island (FL): StatPearls Publishing; 2021 Jan-. PMID: 29083724
7. Misaki K, Uchiyama N, Hayashi Y, Hamada J (2010) Intracerebral hemorrhage secondary to ventriculoperitoneal shunt insertion—four case reports. *Neurol Med Chir (Tokyo)* 50:76–79. <https://doi.org/10.2176/nmc.50.76>
8. Petrov D, Uohara MY, Ichord R, Ali Z, Jastrzab L, Lang SS, Billingham L (2017) Pediatric cerebral sinovenous thrombosis following cranial surgery. *Childs Nerv Syst* 33:491–497. <https://doi.org/10.1007/s00381-016-3329-2>
9. Watanabe J, Okamoto K, Ohashi T, Natsumeda M, Hasegawa H, Oishi M, Miyatake S, Matsumoto N, Fujii Y (2019) Malignant hyperthermia and cerebral venous sinus thrombosis after ventriculoperitoneal shunt in infant with schizencephaly and COL4A1 mutation. *World Neurosurg* 127:446–450. <https://doi.org/10.1016/j.wneu.2019.04.156>
10. Son WS, Park J (2010) Cerebral venous thrombosis complicated by hemorrhagic infarction secondary to ventriculoperitoneal shunting. *J Korean Neurosurg Soc* 48:357–359. <https://doi.org/10.3340/jkns.2010.48.4.357>
11. Trapani S, Stivala M, Lasagni D, Rosati A, Indolfi G (2020) Otogenic lateral sinovenous thrombosis in children: a case series from a single centre and narrative review. *J Stroke Cerebrovasc Dis* 29:105184. <https://doi.org/10.1016/j.jstrokecerebrovasdis.2020.105184>
12. Hanigan WC, Fraser K, Tarantino M, Wang H (2005) Tumefaction of the dural sinuses associated with a coagulopathy following treatment of hydrocephalus in a perinate: case report. *J Neurosurg* 102:426–430. <https://doi.org/10.3171/ped.2005.102.4.0426>
13. Garg A, Rajendram P, Muccilli A, Noel de Tilly L, Micieli JA (2020) Dural venous sinus thrombosis after lumbar puncture in a patient with idiopathic intracranial hypertension. *Eur J Ophthalmol*:1120672120970406. <https://doi.org/10.1177/1120672120970406>
14. Mouraux A, Gille M, Dorban S, Peeters A (2002) Cortical venous thrombosis after lumbar puncture. *J Neurol* 249:1313–1315. <https://doi.org/10.1007/s00415-002-0767-4>
15. Ergan M, Bünauf FHV, Courtheoux P, Viader F, Prouzeau S, Marcelli C (1997) Thrombose veineuse cérébrale après injection intra-thécale de glucocorticoids. *Rev Rhum* 64:595–598
16. Wilder-Smith E, Kothbauer-Margreiter I, Lammler B, Sturzenegger M, Ozdoba C, Hauser SP (1997) Dural puncture and activated protein C resistance: risk factors for cerebral venous sinus thrombosis. *J Neurol Neurosurg Psychiatry* 63:351–356. <https://doi.org/10.1136/jnnp.63.3.351>
17. Aidi S, Chaunu MP, Biousse V, Bousser MG (1999) Changing pattern of headache pointing to cerebral venous thrombosis after lumbar puncture and intravenous high-dose corticosteroids. *Headache* 39:559–564. <https://doi.org/10.1046/j.1526-4610.1999.3908559.x>
18. Browd SR, Gottfried ON, Ragel BT, Kestle JR (2006) Failure of cerebrospinal fluid shunts: part II: overdrainage, loculation, and abdominal complications. *Pediatr Neurol* 34:171–176. <https://doi.org/10.1016/j.pediatrneurol.2005.05.021>

Publisher's Note Springer Nature remains neutral with regard to jurisdictional claims in published maps and institutional affiliations.