

Pediatric Case of Life-Threatening Stroke Caused by Reversible Cerebral Vasoconstriction Syndrome with Spontaneous Cervical Internal Carotid Artery Vasospasm: A Case Report

Yu Fujii, MD, PhD,^{a,1,\$} Yoshiki Hanaoka, MD, PhD,^{a,1,\$}
Toshihiro Ogiwara, MD, PhD,^{a,\$} Jun-ichi Koyama, MD, PhD,^b and
Tetsuyoshi Horiuchi, MD, PhD^{a,\$}

Pediatric reversible cerebral vasoconstriction syndrome (RCVS) and spontaneous cervical internal carotid artery (ICA) vasospasm are rare conditions; the former is commonly associated with a favorable prognosis. A healthy 13-year-old girl presented with thunderclap headache, followed by left hemiparesis, during a curling match. Six days after onset, left hemiparesis worsened to hemiplegia. Magnetic resonance imaging showed progressive cerebral infarction caused by severe right middle cerebral artery and cervical ICA stenosis. She became comatose because of impending uncal herniation. Emergent surgical decompression was performed. Then, 59 days after onset, her multiple stenoses improved, which was consistent with RCVS concomitant with spontaneous cervical ICA vasospasm. This is the first case of RCVS that concurrently developed spontaneous cervical ICA vasospasm. The patient developed life-threatening stroke due to the hemodynamic impairment of the affected intracranial and cervical arteries. Spontaneous extracranial supra-aortic artery vasospasm can be a poor prognostic predictor of RCVS.

Key Words: Extracranial cervical artery vasospasm—Idiopathic cervical internal carotid artery vasospasm—Pediatric stroke—Sympathetic hyperactivity—Thunderclap headache

© 2021 Elsevier Inc. All rights reserved.

Introduction

Reversible cerebral vasoconstriction syndrome (RCVS) is characterized by acute and severe headache, referred to

as thunderclap, and transient segmental cerebral arterial vasoconstriction. The diagnostic criteria include 1) thunderclap headache with or without neurological deficits or seizures, 2) uniphasic course without new symptoms lasting for more than a month after clinical onset, 3) no evidence of aneurysmal subarachnoid hemorrhage, 4) normal or near-normal cerebrospinal fluid analysis findings, 5) multifocal segmental cerebral artery vasoconstriction on either catheter angiography or, indirectly, computed tomography angiography (CTA) or magnetic resonance angiography (MRA) and 6) reversibility of angiographic abnormalities within 12 weeks after onset.¹ Pediatric RCVS is a rare condition and is associated with a favorable prognosis without permanent disabilities.² Moreover, spontaneous cervical internal carotid artery (ICA) (idiopathic cervical ICA or recurrent extracranial carotid artery) vasospasm is extremely uncommon.³⁻⁵

From the ^aDepartment of Neurosurgery, Shinshu University School of Medicine, 3-1-1 Asahi, Matsumoto 390-8621, Japan; and ^bNeuroendovascular Therapy Center, Shinshu University Hospital, Matsumoto, Japan.

Received April 30, 2021; revision received July 24, 2021; accepted July 29, 2021.

Grant support: None

Corresponding author. E-mail: hanaoka@shinshu-u.ac.jp.

¹These authors contributed equally to this work.

^{\$}Department of Neurosurgery, Shinshu University School of Medicine, Matsumoto, Japan

1052-3057/\$ - see front matter

© 2021 Elsevier Inc. All rights reserved.

<https://doi.org/10.1016/j.jstrokecerebrovasdis.2021.106036>

Herein, we report a rare pediatric case of life-threatening stroke caused by RCVS concomitant with spontaneous cervical ICA vasospasm.

Case report

A previously healthy 13-year-old girl presented to a nearby hospital due to thunderclap headache, followed by left hemiparesis, while throwing a stone during a curling match. The patient had no history of smoking, migraine, cardiovascular events, and medication use. Further, there was no relevant family history. Computed tomography (CT) scan did not reveal evidence of subarachnoid hemorrhage. MRA showed reduced signal intensity at the right middle cerebral artery (MCA), and diffusion-weighted imaging (DWI) revealed multiple acute cerebral infarctions at the right anterior cerebral artery (ACA), MCA and posterior cerebral artery (PCA) territories. Thus, the patient was referred to our institution on the same day. On day 1 of admission, electrocardiogram demonstrated no evidence of any arrhythmia or myocardial ischemia. Neurological examination showed moderate left hemiparesis. Moreover, serology test revealed normal inflammatory marker levels, autoimmune profile, immunoglobulin levels, and procoagulant function. The cerebrospinal fluid was clear, and the opening pressure and protein, glucose, and cell levels were normal. Follow-up MRA conducted 3 hours after the initial examination showed progressive multiple segmental stenosis in the right ACA/MCA/PCA/cervical ICA/vertebral artery origin and the left subclavian artery (Fig. 1A). Then, similar findings were observed on CTA. There was no evidence of arterial dissection including intramural hematoma or double-barrel sign on magnetic resonance imaging (MRI) and CTA. Then, oral verapamil (120 mg/day) was administered for the management of presumptive RCVS.

On day 6, left hemiparesis worsened to hemiplegia. MRA revealed loss of signal intensity in the right MCA and cervical ICA, which indicated progressive, fulminant vasoconstriction (Fig. 1B). DWI showed progressive right cerebral infarction caused by hemodynamic impairment of the affected arteries (Fig. 1B). After experiencing recurrent thunderclap headache, the patient became comatose and developed right mydriasis. CT scan revealed right cerebral swelling, which caused impending uncal herniation. Emergent internal and external decompression was performed. Brain tissue and cerebral artery (the anterior and middle temporal arteries of the MCA) specimens were obtained for histopathological analysis.

After surgery, the patient's level of consciousness gradually improved. Histopathological study revealed no evidence of vasculitis, including inflammatory cell infiltration, presence of multinucleated giant cells and granulomas. Then, cranioplasty was conducted on day 41. Follow-up MRA showed improvement in multiple intracranial and

extracranial supra-aortic artery stenosis on day 59 (Fig. 1C). Thus, the patient was diagnosed with RCVS concomitant with spontaneous cervical ICA vasospasm. On day 131, mild hemiparesis was observed. However, independent gait was still achieved, and the level of consciousness normalized. Hence, the patient was discharged home. Then, 3 years and 5 months after the last attack, recurrent headache and stroke were not observed.

Discussion

RCVS is characterized by thunderclap headache and reversible cerebral vasoconstriction, with or without neurological deficits or seizure. Headache usually recurs over 1–3 weeks (typically less than 1 month), and it is often caused by sexual activity, exertion, Valsalva-like maneuver, extreme emotion, bathing and/or showering and bending.⁶ RCVS occurs predominantly among middle-aged women (mean age at onset: 42 years). However, the actual incidence of RCVS is unknown. This condition presumably involves a transient disturbance in the control of cerebral arterial tone, and sympathetic hyperactivity may play a role in its pathogenesis.⁷ In approximately 60% of cases, it develops secondary to the use of vasoactive agents or childbirth. This syndrome is generally self-limiting, and the incidence of recurrence is low. The management involves treatment for pain and removal of vasoconstrictive factors. Calcium channel blockers may help relieve headache. RCVS generally has a favorable prognosis. However, death due to fulminant cerebral vasoconstriction can occur. Pediatric RCVS is an extremely rare condition; that is, only 15 cases have been reported in the literature.² In contrast to female preponderance (81%) in adult RCVS cases, most pediatric cases involve boys (85%), and it may be caused by physical exercise.² To date, no pediatric RCVS case with a life-threatening course has been published.

Moreover, spontaneous cervical ICA vasospasm is not common. To the best of our knowledge, only 16 cases (including that of a pediatric patient) have been reported.^{3–5} In all cases, supra-aortic artery vasospasm was localized in the cervical ICA, and there were no cases of concomitant RCVS and spontaneous cervical ICA vasospasm. Spontaneous cervical ICA vasospasm commonly causes neurological deficits in patients aged 20–40 years, with no differences in terms of sex. Spontaneous cervical ICA stenosis is associated with a high recurrence rate and bilateral occurrence. The risk factors include smoking, cardiovascular events, and migraine. The key differential diagnosis is ICA dissection. Moeller et al. showed that hypersensitivity of the cervical ICA to sympathetic nervous system stimulation could cause spontaneous cervical ICA vasospasm. This finding was supported by the cold pressor test, which stimulated the sympathetic nerves, thereby inducing spontaneous cervical ICA vasospasm.⁸ However, there is no

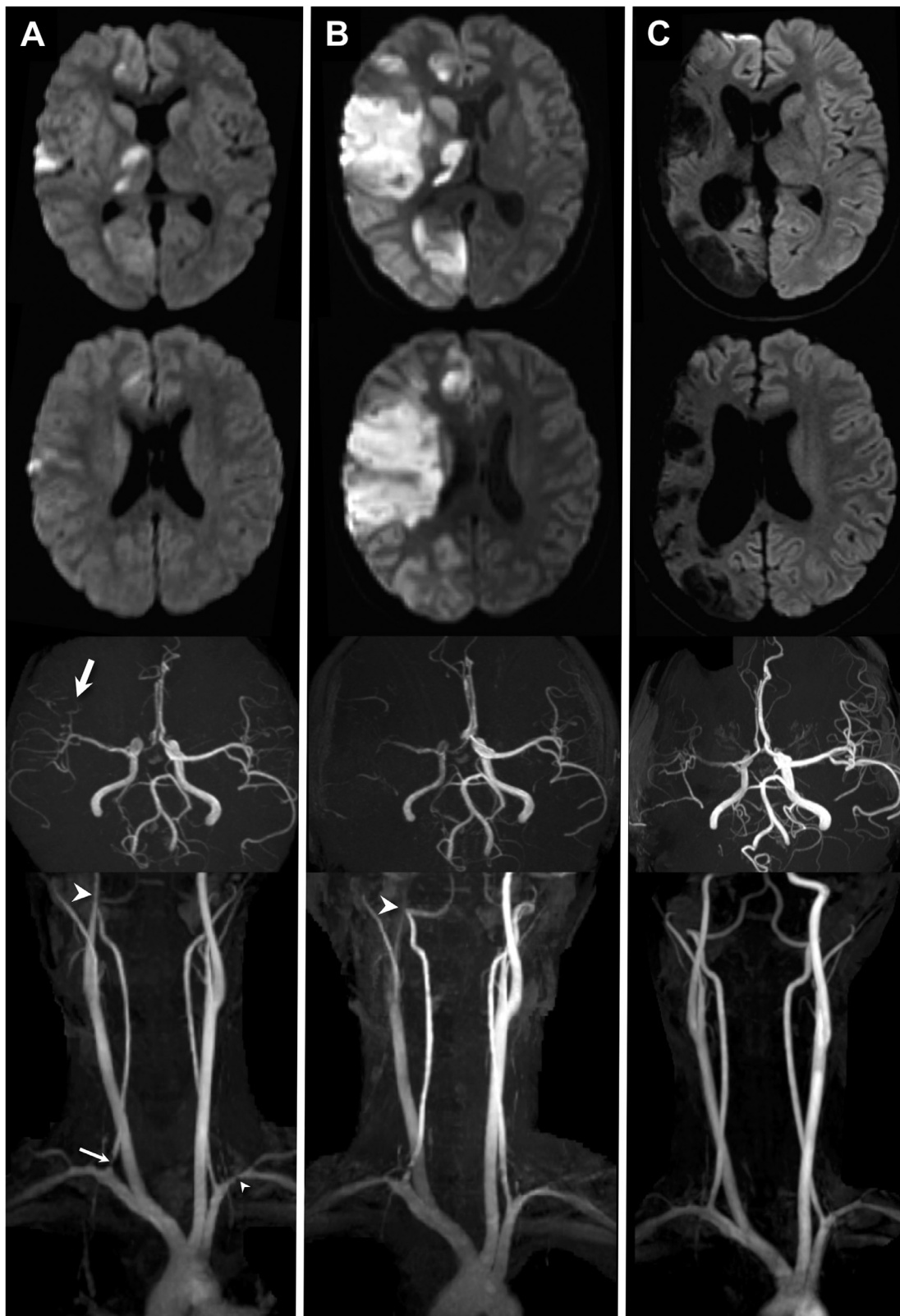


Fig. 1. Chronological findings on diffusion-weighted imaging (DWI) (upper) and intracranial/cervical magnetic resonance angiography (MRA) (lower). (A) Upon clinical onset, DWI revealed lesions with a high signal at the right hemisphere. MRA showed multiple stenosis in the right middle cerebral artery (MCA) (thick white arrow)/cervical internal carotid artery (ICA) (thick white arrowhead)/vertebral artery origin (thin white arrow) and the left subclavian artery (thin white arrowhead). (B) Six days after onset, DWI showed progressive cerebral infarction at the right hemisphere. MRA revealed progressive severe stenosis in the right MCA and the cervical ICA (thick white arrowhead). (C) Follow-up magnetic resonance imaging showed a massive old cerebral infarction at the right hemisphere. MRA revealed improvement in multiple intracranial and extracranial artery stenosis.

standardized treatment. Calcium channel blockers, alpha blockers, steroids, anticoagulant/antiplatelet agents, and stellate ganglion block have been used for the treatment of the condition, and these drugs have different outcomes. Endovascular interventions including balloon angioplasty and carotid artery stenting have been effective for idiopathic cervical ICA vasospasm.^{9,10}

In our case, primary angiitis of the central nervous system was ruled out based on the serum laboratory test, cerebrospinal fluid analysis, and histopathological study. MRI/CTA confirmed no evidence of traumatic lesions, including cerebral/cervical arterial dissection. Moreover, the results of the follow-up MRI conducted within 12 weeks after the clinical onset was compatible with reversible cerebral/cervical vasoconstriction. Thus, the patient was diagnosed with RCVS concomitant with spontaneous cervical ICA vasospasm. To the best of our knowledge, this is the first pediatric RCVS case of concomitant spontaneous extracranial supra-aortic artery vasospasm in the cervical ICA and extracranial vertebral and subclavian arteries. Laeeq et al. have presented a case of RCVS associated with coronary artery vasospasm.¹¹ Meanwhile, in the study of Yoshimoto et al., there were cases of spontaneous cervical ICA vasospasm associated with coronary artery vasospasm.¹² Hence, RCVS/spontaneous cervical ICA vasospasm may be a systemic vascular disease. Our case can support this hypothesis. In the current case, the patient had no history of smoking, migraine, cardiovascular events, and medication use. There was no evidence suggestive of coronary artery vasospasm. Physical exercise, Valsalva-like maneuver, extreme emotion, and bending can cause thunderclap headache and multiple vasospasms. Sympathetic hyperactivity may be associated with a concurrent increase in intracranial and extracranial vascular tones. The patient had a life-threatening stroke caused by severe MCA and ipsilateral cervical ICA vasospasm. Thus, spontaneous extracranial supra-aortic artery vasospasm can be a poor prognostic predictor of RCVS. Therefore, in RCVS cases, the extracranial supra-aortic artery should be evaluated via radiological examination. In our case, the patient did not experience recurrence of spontaneous cervical ICA vasospasm 3 years after the initial onset. However, considering the characteristics of spontaneous cervical ICA vasospasm, recurrence should be considered in cases of extracranial supra-aortic artery vasospasm.

Conclusion

To the best of our knowledge, this is the first case of RCVS that concurrently developed spontaneous cervical ICA vasospasm. The patient developed life-threatening stroke due to the hemodynamic impairment of the affected intracranial and cervical arteries. Sympathetic hyperactivity may concomitantly increase the intra-/extracranial vascular tone. Spontaneous extracranial supra-aortic artery vasospasm can be a poor prognostic predictor of RCVS.

Declaration of Competing Interest

None

References

1. Ducros A. Reversible cerebral vasoconstriction syndrome. *Lancet Neurol* 2012;11:906-917.
2. Kayfan S, Sharifi A, Xie S, et al. MRA and ASL perfusion findings in pediatric reversible cerebral vasoconstriction syndrome. *Radiol Case Rep* 2019;14:832-836.
3. Hirayama K, Hirayama T, Tahara J, et al. Cerebral infarct with idiopathic cervical internal carotid artery vasospasm: a case report and literature review. *Interdiscip Neurosurg* 2018;14:161-163.
4. Huisa BN, Roy G. Spontaneous cervical internal carotid artery vasospasm: case report and literature review. *Neurol Clin Pract* 2014;4:461-464.
5. Janzarik WG, Ringleb PA, Reinhard M, et al. Recurrent extracranial carotid artery vasospasms: report of 2 cases. *Stroke* 2006;7:2170-2173.
6. International classification committee of the international headache society (IHS). 3rd edition The International Classification of Headache Disorders, 33. Cephalalgia; 2013. p. 629-808.
7. Ducros A, Wolff V. The typical thunderclap headache of reversible cerebral vasoconstriction syndrome and its various triggers. *Headache* 2016;56:657-673.
8. Moeller S, Hilz MJ, Blinzler C, et al. Extracranial internal carotid artery vasospasm due to sympathetic dysfunction. *Neurology* 2012;78:1892-1894.
9. Yoshimoto H, Asakuno K, Matsuo S, et al. Idiopathic carotid and coronary vasospasm: a case treated by carotid artery stenting. *Surg Neurol Int* 2014;5:461.
10. Levecque E, Goffette P, Duprez T, et al. Idiopathic internal carotid artery vasospasm successfully treated with balloon angioplasty. *Acta Neurol Belg* 2020;120:1477-1479.
11. Laeeq R, Berman JS, Khalid U, et al. Reversible cerebral vasoconstriction syndrome associated with coronary artery vasospasm. *Tex Heart Inst J* 2019;46:139-142.
12. Yoshimoto H, Matsuo S, Umemoto T, et al. Idiopathic carotid and coronary vasospasm: a new syndrome? *J Neuroimaging* 2011;21:273-276.