

NSL 04974

Crossed cerebello-cerebral diaschisis in a patient with cerebellar infarction

Karl Broich¹, Alexander Hartmann¹, Hans-Jürgen Biersack² and Rolf Horn¹

¹Neurologische Universitätsklinik and ²Institut für klinische und experimentelle Nuklearmedizin, University of Bonn, Bonn (F.R.G.)

(Received 27 February 1987; Revised version received 30 July 1987; Accepted 10 August 1987)

Key words: Diaschisis; Cerebral blood flow; Cerebellar blood flow; Single-photon-emission-computerized-tomography; Cerebellar infarction; Human patient

After supratentorial infarction crossed cerebellar diaschisis has been described. This report concerns the rare phenomenon of crossed cerebral diaschisis in cerebellar infarction. Relative distribution of cerebral and cerebellar blood flow was measured using three-dimensional, qualitative single-photon-emission-computed-tomography (SPECT) with a rotating gamma camera and ¹²³I-IMP. Regional cerebral blood flow was calculated with the two-dimensional, quantitative ¹³³Xe-inhalation-technique. Reduced uptake was observed in the left cerebral hemisphere (–13.9%) contralateral to the cerebellar infarction with the most marked reduction in the left premotor region (–21%). This might be explained by the functional depression of cerebello-ponto-thalamo-cerebral pathways.

A transient reduction of cerebral activity in areas without structural damage distant from the primary brain lesion has been observed in unilateral supratentorial brain ischemia in patients [19] and animals [5, 10, 13]. Metabolic depression in one cerebellar hemisphere contralateral to supratentorial infarction has been described using positron emission tomography [1, 7, 8, 10] or single-photon-emission-computed-tomography (SPECT) [2, 6, 15]. It is assumed to be transmitted by decreased activity of cortico-ponto-cerebellar pathways [12]. Reduction of cerebral hemispheric blood flow following primary cerebellar ischemia has not been described yet.

A 26-year-old male student complained about sudden onset of occipital headache, dizziness, blurred vision, diplopia, slurring of speech and repeated vomiting 2 h after a strenuous football match. Neurological examination revealed slight drowsiness but full orientation, ataxic signs over both rightsided extremities, severe swaying on Romberg test, dysarthric speech, and inability to walk. No other pathologic findings were observed.

Correspondence: K. Broich, Neurologische Universitätsklinik, Sigmund-Freud-Str. 25, D-5300 Bonn 1, F.R.G.

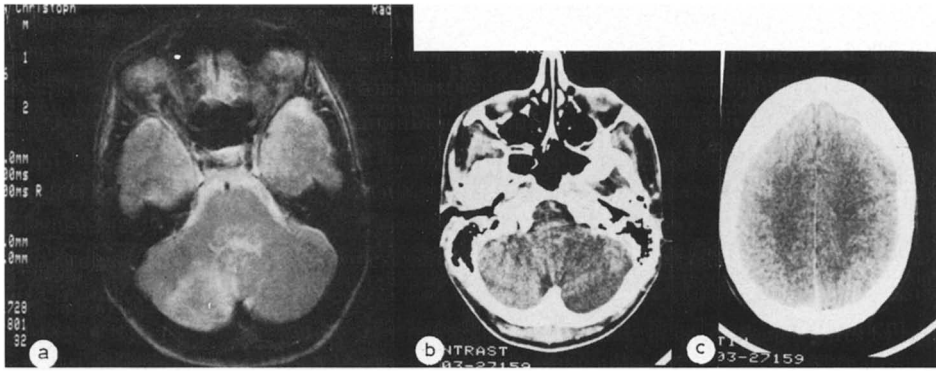


Fig. 1. Nuclear magnetic resonance imaging (NMR) and cranial computerized tomography (CCT): NMR of the posterior fossa (a) indicates an area of increased signal intensity in the right cerebellar hemisphere (left side of a) which corresponds to the low density appearance in CCT (right side of b). Supratentorial tissue is normal in CCT (c) and NMR.

Computerized tomography and nuclear magnetic resonance imaging on day 4 and 11 revealed a rightsided cerebellar hemispheric infarction without mass effect and normal supratentorial tissue appearance (Fig. 1). Angiography revealed complete occlusion of the right vertebral artery at the level of the atlas and otherwise normal vessel appearance. Diagnostic workup did not indicate any abnormality except hypertension, polycythemia, hypercholesterolemia and history of smoking. The history did not reveal any sign of previous cerebral ischemia or any other central nervous system disease. Dizziness and ataxia persisted for two weeks, drowsiness, headache and vomiting vanished within a few days. Follow up studies were normal.

The relative distribution of cerebral and cerebellar blood flow (CBF and CeBF) were measured using a single-head rotating gamma camera (Gammatome T 9000, CGR) with a high resolution-low energy collimator (full width-half maximum 11–15 mm, slice thickness 12 mm for two pixels) on days 24 and 60 after onset of symptoms. Thirty minutes after injection of 6 mCi ^{123}I -amphetamine (IMP) 64 frames were collected during a 360 grad rotation as 64×64 pixels on a 4K frame. Transverse sections were reconstructed by absorption correction and filtered back projection.

Regional cerebral blood flow (rCBF) was calculated with the ^{133}Xe -inhalation technique [11, 14]. Following saturation by inhalation of ^{133}Xe -gas for 60 s, desaturation was recorded for 10 min during breathing of room air. Activity was recorded by 32 helmet-like arranged NaI-detectors (20 mm collimation). IMP-SPECT and ^{133}Xe -rCBF were compared as follows: in a phantom-model the regions of interest in horizontal brain cuts of the SPECT technique were reconstructed in correlation to the tissue cylinders, which were recorded from the NaI-detectors of the ^{133}Xe -method.

In the first IMP-SPECT the ratio of the uptake between affected and non-affected cerebellar hemisphere was 0.59. Compared to the lesion in cranial computerized tomography (CCT) the extent of the perfusion defect was substantially greater (Figs. 1 and 2).

STUDY 1

STUDY 2

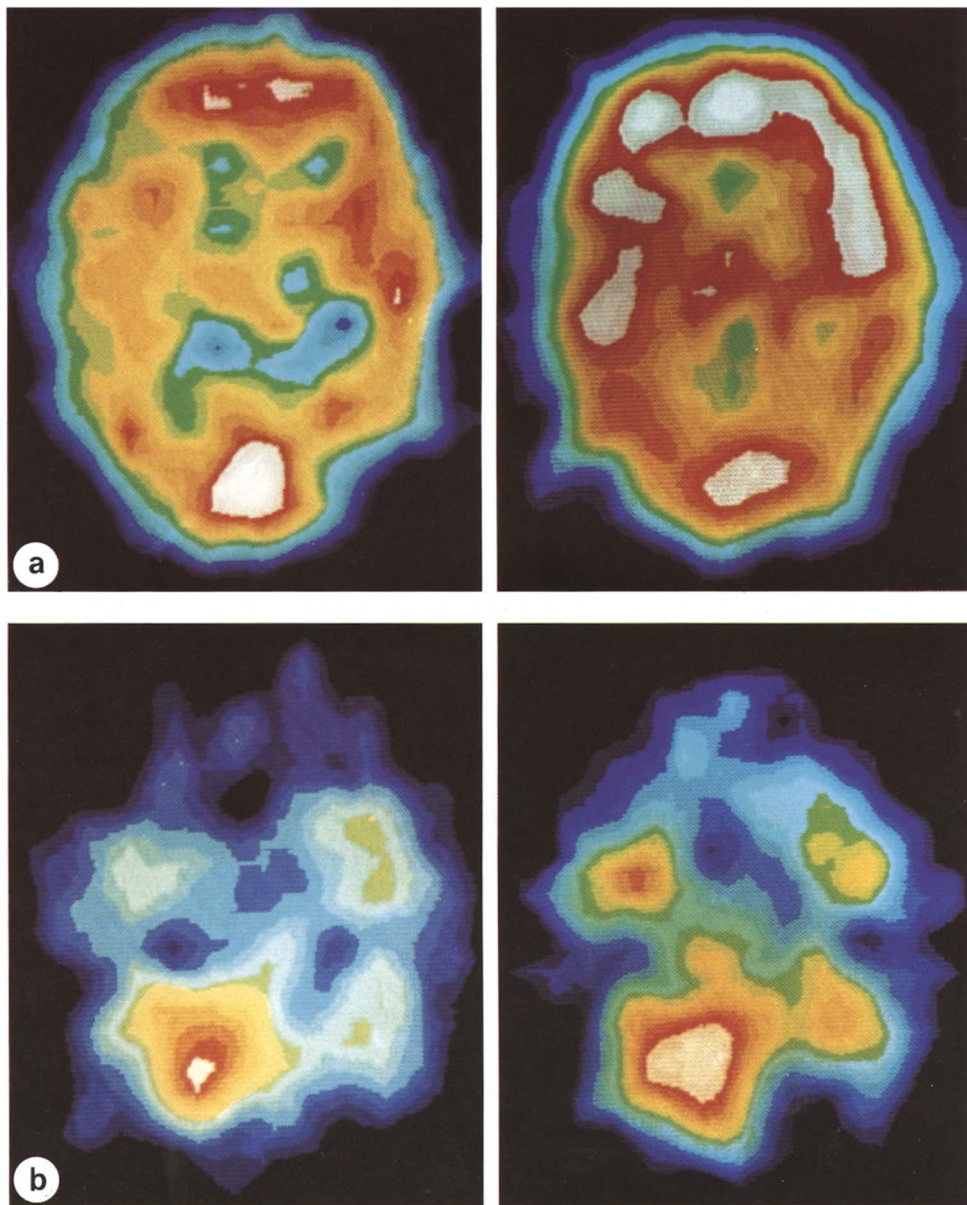


Fig. 2. ^{123}I -IMP-SPECT of the cerebellum and supratentorial tissue at study 1 and 2 of the patient. The images represent the ^{123}I -IMP uptake. Red and white colors indicate a relative high uptake, yellow a medium and green and blue a low uptake. At study 1 the left cerebral hemisphere (a) reveals a reduced uptake compared to the right side of the supratentorial tissue. The right cerebellum has almost no uptake at all (b). At study 2 the lacking uptake in the right cerebellar hemisphere is constant but uptake in the left supratentorial tissue is normal. There is no significant qualitatively reduced uptake in the right parietal lobe.

PERCENTAGE OF ^{123}I -IMP- UPTAKE IN THE
BRAIN : COMPARISON OF AFFECTED TO CONTRA=
LATERAL HEMISPHERES (= 100 %)

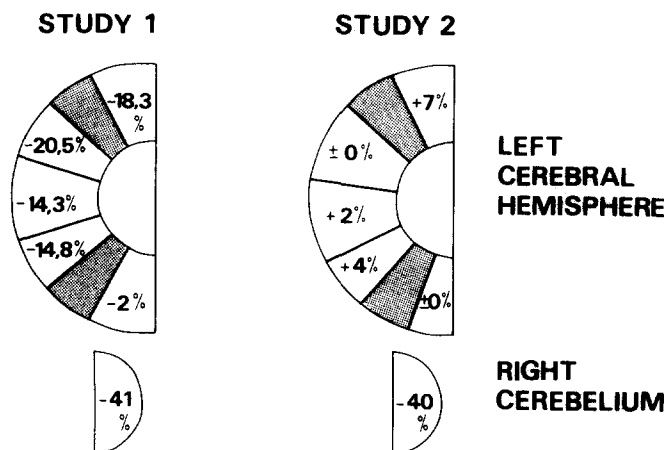


Fig. 3. Percentage of ^{123}I -IMP uptake of cerebral and cerebellar tissue. The difference of the right cerebellar (lower part of figure) and the left supratentorial tissue (upper part of figure) compared to the contralateral side is indicated. The white areas with numbers separated by shadowed areas represent the regions of interest of SPECT corresponding to the tissue as 'seen' by the detectors of the ^{133}Xe -technique.

In the structurally unaffected supratentorial tissue a reduced ^{123}I -IMP uptake in the left cerebral hemisphere was observed with the most marked reduction in the left premotor region (ratio 0.79) and a perfusion deficit in frontal areas (Figs. 2a and 3). The uptake in the rightsided parietal lobe was lower than in the rightsided precentral areas. In the second SPECT study the reduced uptake of the right cerebellar hemisphere was unchanged (Fig. 2b) whereas an uptake deficit of the left cerebral hemisphere was not detectable. Reduced uptake in the left premotor and the right parietal region did not reach a significant level (Figs. 2b and 3).

Mean hemispheric flow values of F1 were 58 ml/100 g/min for both sides. Flow of the right parietal lobe was slightly reduced (right-left ratio: 0.83).

The volume of the cerebellum (ca. 50–75 cm³) is above the critical volume for SPECT as performed with the single-head rotating gamma-camera. The mean right-left difference (R/L-D) of the IMP uptake in patients with no central nervous system disease is $2.5 \pm 2.5\%$ [20]. The physiological mean R/L-D for flow of the fast perfused tissue (F1) using the ^{133}Xe -inhalation technique is $2.1 \pm 4.2\%$ for normal volunteers. A resulting R/L-D of more than 12% may be regarded as being significantly abnormal.

In our case the difference of the IMP uptake at the first study was 41.2% for the cerebellum and 13.9% for the cerebral hemispheres, the latter due to a reduced uptake in the leftsided premotor region (Fig. 2). The uptake in the rightsided parietal lobe was lower than in the rightsided precentral areas. The 2nd SPECT showed a reduced

uptake in the right cerebellum without a statistically significant difference in the cerebral hemisphere. The discrepancies of the SPECT and the ^{133}Xe -rCBF might be due to the specific and unspecific binding of IMP. However Büll et al. [3] have shown that bilateral distribution of both tracers is rather similar confirming the initial observation in dogs that the early uptake of IMP parallels rCBF [10]. Since IMP uptake is rather fast and the concentration constant for several hours with only negligible decline of tissue activity [2, 6], an imaging of the uptake 30–60 min after injection as practiced in our study might reflect the tissue-flow distribution. However, our own studies in patients with cerebrovascular disease revealed a high correlation for IMP and ^{133}Xe for both normal and low flow but only a poor correlation in areas with high flow [20].

Reduced contralateral CBF as a consequence of cerebral ischemia [2, 4] is assumed to be due to functional deactivation by loss of excitatory afferent inputs via the cortico-thalamo-ponto-cerebellar pathways [12].

Crossed cerebello-cerebral diaschisis has not been described before. It can be assumed that reduced IMP uptake in the contralateral cerebral hemisphere is caused by functional deactivation of the cerebello-ponto-thalamo-cerebral pathways which have been described in cats and monkeys [15–17]. The contralateral cerebral precentral area (areas 4 and 6) and the parietal association cortex (area 5) are stimulated by cerebellar nuclei (medial/fastigial and lateral/dentate cerebellar nuclei). Both regions project back to the cerebellum via the pons [10].

In addition Sasaki et al. [17] observed evoked responses in the ipsilateral cerebral cortex after cerebellar stimulation, which might explain the reduction of uptake in the rightsided parietal lobe of the patient presented here. An additional factor might be the deactivation of the transcallosal interhemispheric connections from the left to the right cerebral cortex.

In summary the observation in this rare case of acute rightsided cerebellar ischemia with prolonged ischemia in the contralateral precentral and parietal region of the left cerebral hemisphere might be explained by the functional deactivation of the cerebello-ponto-cerebral pathways. Whether this is as frequent as contralateral cerebellar diaschisis [12] should be evaluated by further studies.

- 1 Baron, J.C., Bousser, M.G., Comar, D. and Castaigne, P., 'Crossed cerebellar diaschisis' in human supratentorial brain infarction, *Trans. Am. Neurol. Ass.*, 105 (1980) 459–461.
- 2 Biersack, H.J., Hartmann, A., Friedrich, G., Fröscher, M., Reichmann, K., Reske, S.N. and Knopp, R., Zur Ursache der gekreuzten zerebellaren Diaschisis bei zerebrovaskulärer Erkrankung, *Nuklearmedizin*, 23 (1984) 227–230.
- 3 Büll, U., Olteanu-Nerbe, V., Kirsch, C.M. and Schmiedek, P., ^{123}I -Amphetamine single photon emission computed (SPECT) tomography versus ^{133}Xe dynamic SPECT: preliminary results, *Nucl. Med. Com.*, 5 (1984) 439–449.
- 4 Cesaro, P., Moretti, J.L., Caron, J.P., Roualdes, B., Louarn, F., N'guyen, J.P., Gaston, A. and Degos, J.D., Tomoscintigraphie cerebrale utilisant la P.-iodo- ^{123}I -N-isopropyl-amphetamine, *Presse Medicale*, 14 (1985) 205–208.
- 5 Ginsberg, M.D., Reivich, M., Giandomenico, A. and Greenberg, J.H., Local glucose utilization in acute focal cerebral ischemia: local dysmetabolism and diaschisis, *Neurology*, 27 (1977) 1042–1048.

- 6 Kuhl, D.E., Barrio, J.R., Huang, S.C., Selin, C., Ackermann, R.F., Lear, J.L., Wu, J.L., Lin, Th. and Phelps, M.E., Quantifying local cerebral blood flow by N-Isopropyl-p-¹²³I-Iodoamphetamine (IMP) tomography, *J. Nucl. Med.*, 23 (1982) 196–203.
- 7 Kushner, M., Alavi, A., Reivich, M., Dann, R. and Robinson, G., Contralateral cerebellar hypometabolism following cerebral insult: a positron emission tomographic study, *Ann. Neurol.*, 15 (1984) 425–434.
- 8 Martin, W.R.W. and Raichle, M.E., Cerebellar blood flow and metabolism in cerebral hemisphere infarction, *Ann. Neurol.*, 14 (1983) 168–176.
- 9 Meneghetti, G., Vorstrup, S., Mickey, B., Lindewald, H. and Lassen, N.A., Crossed cerebellar diaschisis in ischemic stroke: a study of regional cerebral blood flow by ¹³³Xe inhalation and single photon emission computerized tomography, *J. Cereb. Blood Flow Metab.*, 4 (1984) 235–240.
- 10 Naritomi, H., Transtentorial diaschisis: reduction of cerebellar blood flow caused by supratentorial local cerebral ischemia in the gerbil, *Stroke*, 14 (1983) 213–218.
- 11 Obrist, W.D., Thompson, H.K., Wang, H.S. and Wilkinson, W.F., Regional cerebral blood flow estimated by ¹³³Xenon inhalation, *Stroke*, 6 (1975) 245–256.
- 12 Pantano, P., Baron, J.C., Samson, Y., Bousser, M.G., Derouesne, C. and Comar, D., Crossed cerebellar diaschisis: further studies, *Brain*, 109 (1986) 677–694.
- 13 Reivich, M., Jones, S., Ginsberg, M., Slater, R. and Greenberg, J., Regional hemodynamic and metabolic alterations in focal cerebral ischemia: studies of diaschisis, *Adv. Exp. Med. Biol.*, 94 (1977) 617–622.
- 14 Risberg, J., Ali, Z., Wilson, E.M., Wills, E.L. and Halsey, J.H., rCBF by ¹³³Xenon inhalation: preliminary evaluation of an initial slope index in patients with unstable flow compartments, *Stroke*, 6 (1975) 142–148.
- 15 Sasaki, K., Kawaguchi, S., Matsuda, Y. and Mizuno, N., Electrophysiological studies on cerebello-cerebral projections in the cat, *Exp. Brain Res.*, 16 (1972) 75–88.
- 16 Sasaki, K., Matsuda, Y., Kawaguchi, S. and Mizuno, N., On the cerebello-thalamo-cerebral pathways for the parietal cortex, *Exp. Brain Res.*, 16 (1972) 89–103.
- 17 Sasaki, K., Kawaguchi, S., Oka, H., Sakai, M. and Mizuno, N., Electrophysiological studies on the cerebellocerebral projections in monkeys, *Exp. Brain Res.*, 24 (1976) 495–507.
- 18 Von Schulthess, G.K., Ketz, E., Schubiger, A. and Bekier, A., Regional quantitative noninvasive assessment of cerebral perfusion and function with N-isopropyl-¹²³I-Iodo-amphetamine, *J. Nucl. Med.*, 26 (1985) 9–16.
- 19 Slater, R., Reivich, M., Goldberg, H., Banka, R. and Greenberg, J., Diaschisis with cerebral infarction, *Stroke*, 8 (1977) 678–690.
- 20 Tsuda, Y., Hartmann, A., Biersack, H.J., Valerius, E. and Reichmann, K., Assessment of regional cerebral blood flow with ¹²³Iodine-Amphetamine (IMP) SPECT in cerebrovascular disease: semiquantitative analysis comparing with ¹³³Xenon inhalation method, *Acta Radiol. (Suppl.)*, in press.