

Crossed Choreoathetosis Caused by Unilateral Thalamic Hemorrhage

Sumire Kurihara, MD,¹ Takeo Sato, MD,¹ Hidetomo Murakami, MD, PhD,
Teppei Komatsu, MD, PhD, Kenichiro Sakai, MD, PhD, Tadashi Umehara, MD, PhD,
Shusaku Omoto, MD, PhD, Hidetaka Mitsumura, MD, PhD, and
Yasuyuki Iguchi, MD, PhD

In general, involuntary movements after stroke are due to a disturbance in the unilateral cortico-basal ganglia loop and appear contralateral to stroke lesions. Crossed involuntary movements after unilateral stroke are very rare. We observed a case of crossed involuntary movements in the left upper limb and right lower limb after a right thalamic hemorrhage expanded to the right subthalamic nucleus. We considered a possible three-step theory as the basis of crossed choreoathetosis. This case informs our better understanding of the cortico-basal ganglia loop and involuntary movements after stroke.

Key Words: Cortico-basal ganglia loop—Involuntary movement—Choreoathetosis—Thalamus—Cerebrovascular disease—Hemorrhagic stroke—Movement disorders
© 2021 Elsevier Inc. All rights reserved.

Case report

An 81-year-old male with hypertension developed left hemiparesis. Paralytic dysarthria, left hemiparesis, and hypesthesia on the left side were seen. CT revealed a right thalamic hemorrhage (Fig. 1A). Left hypesthesia gradually improved, but paresis in his left lower limb remained more severe than that in his upper limb.

On the 16th hospital day, involuntary movements (IVM) emerged in the left upper limb and right lower limb (video). These were observed in distal limbs more than in proximal and was interpreted as choreoathetosis. MRI revealed the right medial subthalamic nucleus (STN) was affected by the hemorrhage (Fig. 1B). Choreoathetosis gradually improved without medications over 14 days after the onset.

From the Department of Neurology, The Jikei University School of Medicine, 3-25-8, Nishi-Shimbashi, Minato-ku, Tokyo 105-8461, Japan.

Received June 4, 2021; revision received August 3, 2021; accepted August 4, 2021.

Corresponding author. E-mail: takeo.sato.821@gmail.com.

¹These authors contributed equally to this work.

1052-3057/\$ - see front matter

© 2021 Elsevier Inc. All rights reserved.

<https://doi.org/10.1016/j.jstrokecerebrovasdis.2021.106049>

Discussion

Involuntary movements after stroke are caused by a disturbance in the unilateral cortico-basal ganglia loop (CBGL) and usually appear contralateral to stroke lesions.¹ Crossed IVM after unilateral stroke are rare. We speculated on the possibility of a three-step theory.

First, the STN has a commissural connection to the contralateral CBGL,² which could cause bilateral IVM following unilateral STN damage. High-frequency stimulation of unilateral STN changes the contralateral STN activity in relation to the occurrence of ipsilateral dyskinesias in patients with Parkinson's disease.² This suggests a disturbance of the unilateral STN could affect the bilateral CBGL via the commissural connection resulting in bilateral involuntary movements (Fig. 1C,1). Indeed, a rare case of bilateral ballism after unilateral subthalamic infarction has been reported.³

Second, the somatotopy of the STN may explain the lower limb-dominant IVM due to external damage to the medial STN.^{4,5} Neurons from the primary motor cortex (M1) and supplementary motor cortex (SMA) to the STN suppress thalamocortical circuits, which are part of the CBGL, and arrest movements.⁴ These neurons converge

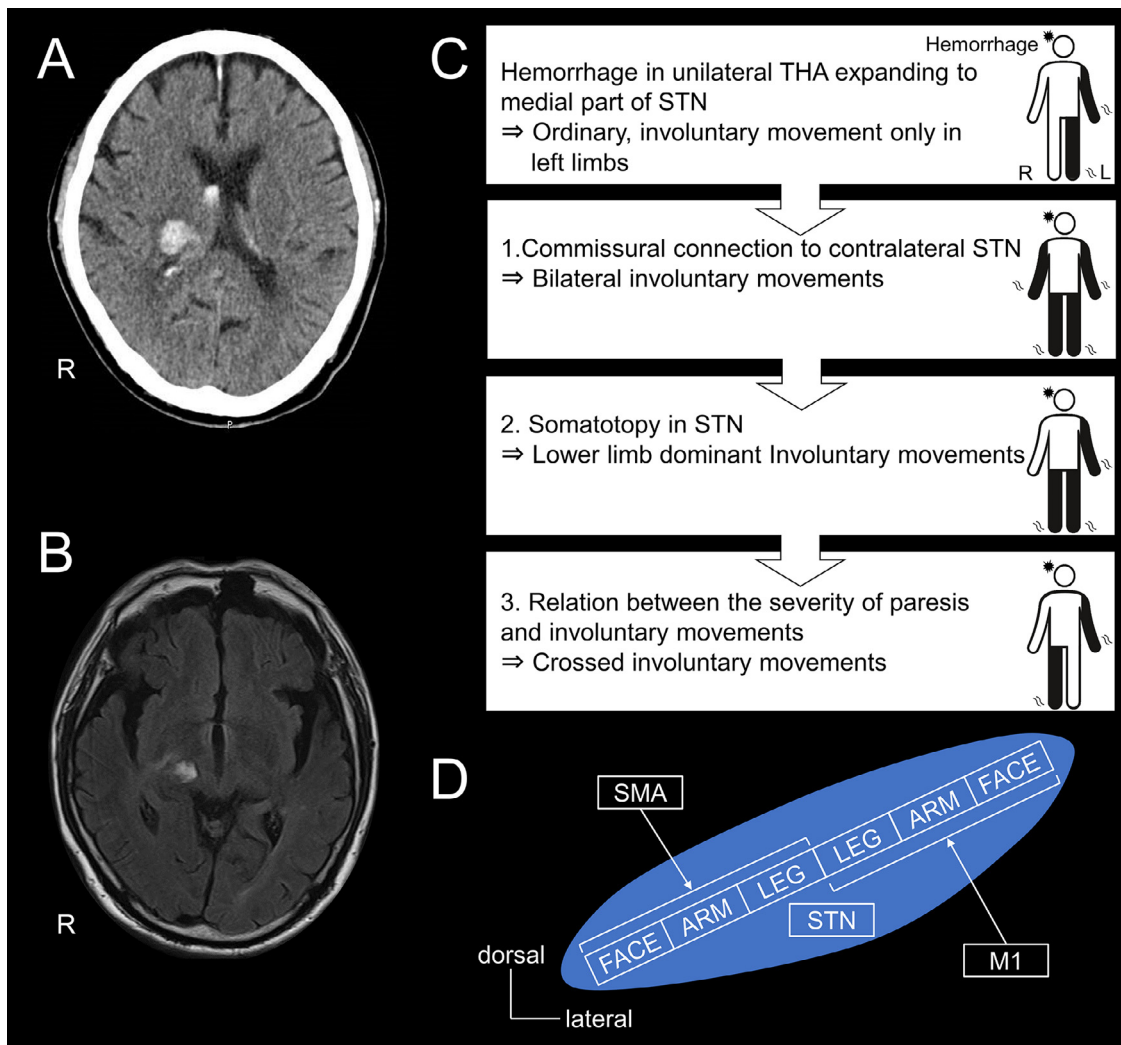


Fig. 1. A. Brain CT. B. Brain MRI. C. Three-step theory for crossed choreoathetosis. A. Brain CT at admission showed a right thalamic hemorrhage. B. MRI, fluid-attenuated inversion recovery, on the 23rd hospital day revealed that the right thalamic hemorrhage had expanded to the medial part of the right subthalamic nucleus. C. Possible three-step theory for crossed choreoathetosis. Diagrams of the human body, with black showing limbs with involuntary movements. D. Somatotopy of the subthalamic nucleus. Modified from Nambu et al.^{4,5} M1, primary motor cortex; SMA, supplementary motor area; STN, subthalamic nucleus; THA, thalamus.

somatotopically on the STN.^{4,5} The M1 projects to the lateral part, and the SMA projects to the medial part of STN.^{4,5} The face, arm, and leg regions of the M1 project to the lateral to medial parts of the lateral STN, while those of the SMA project to the medial to lateral parts of the medial STN, representing like a mirror image (Fig. 1D). Therefore, the lower limb regions of both M1 and SMA concentrate to the medial part of the STN.^{4,5} When STN is externally damaged, lower limb regions of both M1 and SMA domains are easily affected simultaneously, resulting in lower dominant IVM.⁶ It has been also reported regarding experimentally evoked dyskinesia by STN lesioning that lower limb dyskinesias are more marked than upper limb, and rare in orofacial area.⁶ In this case, the hemorrhage expanded and externally damaged the medial part of STN so that we consider IVM were likely to appear in the lower limbs (Fig. 1C,2).

Third, IVM rarely appear in a limb with severe paresis.⁷ In our case, left lower limb paresis remained more severe than in the left upper limb, and thus, IVM were unlikely to appear in the left lower limb (Fig. 1C,3).

Based on these three possible mechanisms, we speculate IVM finally appeared in the left upper limb and right lower limb after right thalamic hemorrhage expanded to the medial STN. However, this theory has several limitations. Concerning the first step, the suspected commissural connection between STNs has been revealed only based on extrapolation of data from experimental high-frequency stimulation of STN in patients with Parkinson's disease. Further investigation to identify the connection between STNs using connectomics or tractography are required to confirm the first step theory. Concerning the second step, STN is anatomically so small that affecting only the lower limb region must be somewhat difficult,

considering the size of the current hemorrhage. There remains a possibility that a slight IVM in the right upper limb might have actually happened and been overlooked.

We believe this case provides better understanding of the CBGL and IVM after stroke.

Financial disclosures

None.

Study funding and grant support

None.

Acknowledgment

None.

Supplementary materials

Supplementary material associated with this article can be found in the online version at doi:[10.1016/j.jstrokecerebrovasdis.2021.106049](https://doi.org/10.1016/j.jstrokecerebrovasdis.2021.106049).

References

1. Bansi S, Prakash N, Kaye J, et al. Movement disorders after stroke in adults: a review. *Tremor Other Hyperkinet Mov* 2012;2: tre-02-42-195-1.
2. Brun Y, Karachi C, Fernandez-Vidal S, et al. Does unilateral basal ganglia activity functionally influence the contralateral side? What we can learn from STN stimulation in patients with Parkinson's disease. *J Neurophysiol* 2012;108:1575-1583.
3. Mark VW, Oberheu AM, Henderson C, et al. Ballism after stroke responds to standard physical therapeutic interventions. *Arch Phys Med Rehabil* 2005;86:1226-1233.
4. Nambu A, Takada M, Inase M. Dual somatotopical representations in the primate subthalamic nucleus: evidence for ordered but reversed body-map transformations from the primary motor cortex and the supplementary motor area. *J Neurosci* 1996;16:2671-2683.
5. Nambu A. Somatotopic organization of the primate basal ganglia. *Front Neuroanat* 2011;5:26.
6. Noda K, Hattori N, Okuma Y. Hemiballism with leg predominance caused by contralateral subthalamic haemorrhage. *BMJ Case Rep* 2015;2015:bcr2014208525.
7. Mehanna R, Jankovic J. Movement disorders in cerebrovascular disease. *Lancet Neurol* 2013;12:597-608.