

**The resilience of the developing reading system:
multi-modal evidence of incident and recovery after a pediatric stroke.**

Borghesani, V.^{1,2}, Wang, C.^{1,2}, Miller, C.^{1,2}, Mandelli, M.L.^{1,2}, Shapiro, K.^{1,2}, Miller, Z.^{1,2}, Fox, C.²,
Dronkers. N.F.^{3,4}, Gorno-Tempini, M.L.^{1,2,5} & Watson, C.^{1, 2,5*}

¹ *Memory and Aging Center, Department of Neurology, University of California San Francisco*

² *Department of Neurology, University of California, San Francisco, CA*

³ *Department of Psychology, University of California, Berkeley, CA*

⁴ *Department of Neurology, University of California, Davis, CA3*

⁵ *Dyslexia Center, University of California, San Francisco, CA*

*** Corresponding author:**

Christa Watson

Memory and Aging Center - University of California, San Francisco

675 Nelson Rising Lane, Suite 190 | San Francisco, CA 94158

christa.watson@ucsf.edu

Abstract: 129 words

Body: 6,373 including references and citations

Figures: 3

Tables: 4

ABSTRACT:

Reading requires the sophisticated interplay of multiple neurocognitive systems. Decades of neuropsychological and neuroimaging findings have shed light onto the highly specialized brain areas along the ventral occipitotemporal stream that harbor the first critical step: the transition from grouping of lines to recognizable words.

Here, we report on a 14-year old female who developed temporary dyslexia (i.e., slow and effortful reading) after suffering a left ventral occipitotemporal ischemic stroke. Our longitudinal multimodal findings indicate that the resolution of the reading impairment was associated with heightened activity in the left posterior superior temporal gyrus and left inferior temporal gyrus.

Overall, our findings highlight the critical role played by the left inferior temporal gyrus in reading and suggest the importance of perilesional and ipsilateral cortical areas for functional recovery after childhood stroke.

KEYWORDS: pediatric stroke, reading, acquired dyslexia, lexical access, inferior occipitotemporal cortex

INTRODUCTION

Reading, i.e., mapping arbitrary symbols to meaningful concepts, requires the interplay of numerous cognitive processes relying on distinct neural substrates, with converging lines of research assigning a key role to the computations hosted by the ventral occipitotemporal cortex (vOT). The hierarchical series of processes required to analyze printed words (Dehaene, Cohen, Sigman, & Vinckier, 2005) has been associated with the unfolding of neural activity from the occipital lobe to the temporal pole within 400 ms (Marinkovic et al., 2003). A region in the left lateral occipitotemporal sulcus, known as visual word form area (VWFA, Dehaene & Cohen, 2011), appears to be critical. The VWFA response is greater to printed words than other visual stimuli such as false fonts (Cohen et al., 2002; Vinckier et al., 2007) and pseudowords (Gauthier et al., 2000), invariant to changes in low-level visual aspects of stimuli such as font or location (Cohen et al., 2000, 2002; Dehaene et al., 2001), highly reproducible across individuals (Dehaene, Guran, Poline, Bihan, & Cohen, 2006), and functionally tuned to a reader's writing system (Baker et al., 2007; Bolger, Perfetti, & Schneider, 2005).

Neuropsychological evidence demonstrates that adequate reading performance relies on the integrity and efficiency of left posterior vOT computations. Focal lesions of this area, such as those following strokes, have been associated with pure alexia (or alexia without agraphia), an acquired language disorder where slow and effortful reading of words and text, so-called letter-by-letter reading, is associated with sparing of other language functions (Cohen, Martinaud, Lemer, & Lehericy, 2003). Following damage to the left vOT and/or to the underlying white matter, two other acquired impairments of written language can be observed either in isolation or comorbidly: surface alexia (i.e., overreliance on sublexical reading strategies), and surface agraphia (i.e., overreliance on sublexical spelling strategies), both resulting in a preponderance of phonologically plausible errors (Friedman & Hadley, 1992). Similarly, developmental dyslexia, a learning disorder characterized by poor reading not accounted for by differences in intelligence or education, has been consistently associated with atypical functional (e.g., Maisog et al.,

2008; Richlan et al., 2011) and structural (e.g., Richlan, Kronbichler, & Wimmer, 2013) findings in left posterior vOT. While studies on adults can speak to the ability of the mature reading system to recover after neural damage, studies in children are particularly interesting as they allow for the investigation within the context of development. This is especially relevant for the kind of perceptual expertise associated with hierarchical representations of visual information and literacy acquisition supported by vOT, which require prolonged maturation (Dehaene et al., 2010); Golarai et al., 2007; Grill-Spector & Weiner, 2014). The vOT develops sensitivity to printed words (vs. nonverbal visual stimuli) within the first 4 years of life, while specificity (vs. other complex visual stimuli) requires longer maturation (Cantlon, Pinel, Dehaene, & Pelphey, 2011; Centanni, King, Eddy, Whitfield-Gabrieli, & Gabrieli, 2017; Olulade, Flowers, Napoliello, & Eden, 2013). Hence, great advancements in our understanding of the neurocognitive properties of vOT will come from studies of acquired dyslexia following childhood focal lesions to this area. As these cases are rare and heterogeneous (due to variability in lesion site, age at onset, prior language lateralization, etc...), in-depth descriptions of single cases are instrumental in developing new hypotheses and guiding future research.

Here we present the case of a 14-year-old, left-handed female, Ms. C, who manifested acquired dyslexia in the acute phase following a left occipitotemporal ischemic stroke. We followed her for over three years documenting her recovery with both neuropsychological and neuroimaging data. Our longitudinal multimodal findings underscore the critical role of the left ventral occipitotemporal cortex in reading, as well as the central importance of perilesional and ipsilateral cortical areas for functional recovery after stroke.

MATERIALS & METHODS

Patient Recruitment and Consenting

Ms. C, 14-year-old, left-handed female, was recruited from the UCSF Department of Pediatric Stroke Neurology. Guardians of the participant provided informed written consent and Ms. C provided assent. The study was approved by the UCSF Committee on Human Research and conforms with the Declaration of Helsinki.

Clinical History

Medical chart review was performed by Drs. Watson, Shapiro, and Fox. Only pertinent information is included. Records included information on clinical history, imaging, neurological exams, and cognitive and behavioral testing.

Ms. C.'s initial symptoms started about 30 minutes after she awoke from sleeping, with sudden onset of blurry vision in the right visual field and inability to read while checking text messages on her mobile phone. This progressed to transient horizontal diplopia lasting 30 minutes, then headache with nausea and vomiting. She presented to a local Emergency Department after two days of persistent headache and an inability to read text messages or books but with retained speaking and writing abilities. She noted she could identify letters individually but reported: *"my brain could not piece together words."* On the neurologic exam, she had dyslexia and dyscalculia, but the remainder of her exam was normal including intact cranial nerve function, normal visual fields and normal strength, sensation and coordination. Brain MRI demonstrated a left posterior inferior temporal cortical ischemic stroke. No stroke risk factors were identified after ECHO with bubble study, vascular head and neck imaging and hypercoagulable testing. She had a normal birth history and typical early development with no significant past medical history. Prior to the stroke, she enjoyed reading and writing and was doing well in middle school.

During admission, neuropsychological testing demonstrated alexia without agraphia, overregularization of irregular words, the ability to copy and write sentences but not read them, difficulty with calculations, especially subtractions. The chief difficulty appeared to be reading single words without context. She was referred for follow-up in the UCSF Pediatric Brain language specialty clinic. Neuropsychological, neurological and

neuroimaging assessments reported here were conducted 20 days, 1-year and 2-years post-stroke.

Neuropsychological Assessment

All neuropsychological tasks were administered by clinical neuropsychologists or research staff trained and supervised by a neuropsychologist and neurologists.

At presentation (2017), neuropsychological assessment was the same reported in (Caverzasi et al., 2018). A similar neuropsychological evaluation was performed during the second follow-up (2019). Table 1 reports, for both time points, the percentile and the descriptive term associated with Ms. C's performance.

Both at presentation (2017) and at the one-year follow-up (2018), assessment included standardized academic measures using the Woodcock-Johnson IV (WJ-IV, Schrank, Mather, & McGrew, 2014). Timed reading was assessed via the Test of One-Word Reading Efficiency version 2 (TOWRE-2, Torgesen, Wagner, & Rashotte, 2012). Table 2 reports the percentile and the descriptive term associated with Ms. C's performance in these five tasks.

Finally, in-depth language testing was performed during the first assessment. It included the Expressive and Receptive One-Word Picture Vocabulary Tests-Fourth Edition (EOWPVT-4 and ROWPVT-4, Frauwirth, Michalec, & Henninger, 2017), and the Clinical Evaluation of Language Fundamentals-Fifth Edition (CELF-5, Wiig, Secord, & Semel, 2013). This evaluation also integrated experimental tasks for which data on age-matched controls are not currently available. Confrontation naming was assessed with a short version of the Boston Naming Test (short BNT, Kramer et al., 2003; Mack, Freed, Williams, & Henderson, 1992). To assess phrase repetition ability, we used a short version of the Bayles test (25 items, Bayles, Tomoeda, & Rein, 1996). Syntax and grammar were assessed with the short version of the NAT-UT (12 items, Weintraub et al., 2009). Visual and verbal semantic processing were tested with the Camel and Cactus Test (64 items, Bozeat, Lambon Ralph, Patterson, Garrard, & Hodges, 2000). Table 3 reports the percentiles (or raw scores) and the descriptive terms associated with each task.

Neuroimaging

Both year 1 (2017) and year 2 (2018) visits included anatomical and functional neuroimaging assessment. Data were collected at University of California San Francisco (UCSF) Neuroimaging Center with a 3 Tesla Siemens Magnetom Prisma scanner using a 64-channel head coil. Anatomical images were acquired using a T1 magnetization prepared rapid gradient echo (MPRAGE) sequence (160 sagittal slices, field of view = 256 mm², matrix = 256 x 240, voxel size 1x1x1 mm, repetition time = 2300 msec; echo time = 2.9 msec; inversion time = 900 msec; flip angle = 9°). Whole brain functional images were acquired using echo-planar imaging (EPI) scans with the following parameters: 64 axial slices; 310 repetitions; field of view = 220mm; voxel size in plane = 2.2x2.2 mm; slice thickness = 2.2mm; repetition time = 1.29s; echo time = 33.4ms; a multiband acceleration factor of 4. We administer the visual version of the Adaptive Language Mapping (ALM, Wilson, Yen, & Eriksson, 2018), which includes a semantic matching task and a false font matching task. During the semantic matching task trials, the subject is presented with a pair of words, and asked to press a button in response to semantically related ones (e.g., *onion - cry*). Similarly, the false font matching task trials requires the subject to answer to matching strings of false fonts (e.g., ΔΘδϚ↵-ΔΘδϚ↵). The ALM runs in Matlab (<http://www.mathworks.com>) with Psychtoolbox-3 (<http://psychtoolbox.org>) with an AB block design, alternating semantic and false font conditions. The seven difficulty levels of the word version result from the modulation of word length, lexical frequency, concreteness, age of acquisition, and degree of relatedness. Ms. C. received training outside the scanner, and, once in the scanner, underwent 1 functional run comprising 10 blocks per condition, thus 20 blocks total (6 m and 40 s).

After standard preprocessing steps (i.e., slice time correction, motion correction, co-registration of functional and anatomical images), functional images were analyzed within the framework of a General Linear Model (GLM). The GLM included 2 regressors of interest (convolved with the standard hemodynamic response function without derivatives) corresponding to onsets of semantic and false font trials respectively, as well

as 6 regressors of no interest corresponding to the movement parameters estimated during the preprocessing. Low– frequency drift terms were removed by a high– pass filter with a cutoff of 128s. At both time points (i.e., year 1 and year 2), the contrast of interest was the comparison of whole-brain activations during the semantic matching task vs. > false font matching task. The underlying assumption is that the two conditions are equivalent in terms of sensorimotor and executive components, yet have different loading onto the language system. All neuroimaging analyses were preprocessed using SPM12 (<https://www.fil.ion.ucl.ac.uk/spm/software/spm12>) in Matlab.

At both evaluations, behavioral performance during the ALM was compared between semantic matching vs. false font matching tasks with a binomial test for accuracy and a t-test for reaction times. Linear regression models were used to assess the presence (and possible changes over time) in linear trends across difficulty levels for both tasks. First, we fit 2 linear regression models to the number of correct trials per difficulty level in the semantic matching tasks at year 1 and year 2. After assessing whether any statistically significant slope was detected, we computed the difference between the trend at year 1 minus the trend at year 2. A third linear regression model fitted on this difference indicated whether there was significant change over time. These analyses were repeated for the false font matching tasks as well as for average RTs in both tasks. All the analyses described in this section were performed with Matlab.

RESULTS

Behavioral profile

The detailed neuropsychological assessment performed during the first visit indicated that basic executive, memory and visuo-spatial functions were intact (Table 1): all measures revealed average or above average performance (with the exception of the digit span forward, which was low but within normal limits). While most of the evaluation was unremarkable, few relevant exceptions were noted. During picture naming, we observed rare instances in which she would be able to identify the items and functions, yet could not retrieve the appropriate lexical label (e.g. stirrup: "*the thing that holds your shoe while you're riding a horse*"). She would also make paraphasic errors including semantic substitutions (clarinet: "*flute*"); neologisms (microscope: "*magnascope*"); and circumlocutions (skyscraper: "*skyscraping building*")." Comparable results were obtained during the second follow-up in our Center, two years later (Table 1). Thus, overall, Ms. C's reading impairment (subjectively reported, but also emerging from the standardized and experimental tasks reported below), cannot be ascribed to only visual processing difficulties nor to generalized executive or attentional impairments.

Table 1. Neuropsychological assessment. Standardized assessment of nonverbal reasoning, processing speed, attention and working memory, verbal and visual recall, visuospatial abilities, and executive functioning. Please see text for details.

| Domain | Assessment | Year 1 (2017) | | | Year 3 (2019) | | |
|--|--|---------------|--------------------|------------------|---------------|-------------------|------------------|
| | | Raw Score | Percentile | Descriptive Term | Raw Score | Percentile | Descriptive Term |
| Nonverbal Reasoning | WASI/WAIS - Matrix Reasoning | 27 | 58 th | Average | n/a | 9 th | Low Average |
| Short-Term and Working Memory (< 30 seconds) | CVLT—C Trial 1 (max = 15) | 7 | 50 th | Average | n/a | 69 th | Average |
| | WISC/WAIS Digit Span Forward Total | 5 | 9 th | Low Average | n/a | 25 th | Average |
| | WISC/WAIS Digit Span Backward Total | 8 | 63 rd | Average | n/a | 63 rd | Average |
| Processing Speed (Visual and Verbal) | NEPSY- II —Naming/ DKEFS Color Naming | 44* | 25 th | Average | n/a | 37 th | Average |
| | WISC/WAIS Symbol Search | 28 | 25 th | Average | n/a | 84 th | High Average |
| | Children’s Colored Trails 1/ DKEFS Number Sequencing | 13* | 62 nd | Average | n/a | 50 th | Average |
| Learning and Long-term Memory | CVLT—C Trial 5 (max = 15) | 13 | 69 th | Average | n/a | 50 th | Average |
| | CVLT-C — Short Delay Free Recall (1 minute recall, max = 15) | 13 | 69 th | Average | n/a | 69 th | Average |
| | CVLT-C — Long Delay Free Recall (20 minute recall, max = 15) | 14 | 84 th | High Average | n/a | 69 th | Average |
| | CVLT-C — Recognition (recognizing target words from distractors) | 98% | 50 th | Average | n/a | 50 th | Average |
| | Rey-O —3 minute delay | 29 | 86 th | High Average | n/a | 75 th | High Average |
| Visuospatial & Visuomotor Processing | WISC/WAIS Coding | 55 | 25 th | Average | n/a | 25 th | Average |
| | Rey-O—Copy | 34 | > 16 th | Average | n/a | >16 th | Average |
| Executive Functioning | NEPSY- II —Semantic Fluency | 41 | 75 th | High Average | n/a | 99 th | Very Superior |
| | NEPSY- II —Phonemic Fluency | 19 | 37 th | Average | n/a | 37 th | Average |
| | Children’s Colored Trails 2/ DKEFS Number-Letter Switching | 41 | 16 th | Low Average | n/a | 75 th | High Average |

Standardized assessment of reading and spelling single words and naming performance revealed the key feature of Ms. C’s behavioral profile: effortful, slow reading (Table 2). During her first evaluation, she presented with impaired timed reading of both words and pseudowords. On the contrary, scores on picture naming, word spelling, and untimed reading were low but within normal limits. In particular, her performance in the untimed letter-words identification test showed a clear effect of words length: no errors with single letters, 3 errors with monosyllabic words, 4 errors with bisyllabic words, 5 errors with trisyllabic words, and only reads correctly one of the words with 4 or more syllables. Moreover, all but 3 of the errors are on irregular words (i.e., *aggrandizement*, *idiosyncrasy*, *staunchest*) and there is a clear frequency effect: log frequency for errors 1.7±0.97 vs. 2.92±0.92 for correctly read words (T-test p-value <0.0001; based on SUBTLEXUS). Her reliance on a letter-by-letter strategy and sublexical processes is corroborated by the responses produced: for instance, presented with the word

municipality she says she doesn't "know if it's 'moon' or 'mun'", with *staunchest* she says she "can't piece it together that well".

The same pattern, just less accentuated, is observed in during the spelling task: no errors with single letters, 2 errors with monosyllabic words, 3 errors with bisyllabic words, 5 errors with trisyllabic words, and 3 errors with words 4 syllables. All errors are on irregular words except for 3 (i.e., skiing calorie, exaggerate) yet the frequency effect is less marked, perhaps due to the stimuli being overall more frequent: log frequency for errors 2.11 ± 0.97 vs. 2.67 ± 1.21 for correctly read words (T-test p-value=0.08). It should be noted that all errors are phonologically plausible except for two deletions (i.e., sking, subscription) and one substitution (i.e., negotiate).

At subsequent evaluations, Ms. C showed a clear improvement in all tasks, reaching low but within normal limits performance in timed reading as well. Within a year since the ischemic stroke, her acquired dyslexia thus appeared resolved from patient and parent subjective reports and school performance.

Table 2. Standardized language assessment. Reading (both [single](#) words and pseudowords), spelling and naming performance was assessed with both timed and untimed standardized tests. Please see text for details.

| Assessment | Year 1 (2017) | | | Year 2 (2018) | | | Year 3 (2019) | | |
|---|---------------|-------------------|------------------|---------------|------------------|------------------|---------------|------------|------------------|
| | Raw Score | Percentile | Descriptive Term | Raw Score | Percentile | Descriptive Term | Raw Score | Percentile | Descriptive Term |
| WJ-IV Letter Word Identification (Untimed Real Words) | 61 | 25th | Average | 64 | 34 th | Average | | | |
| TOWRE-2 Sight Word Efficiency (Timed Real Words) | 57 | < 1 st | Impaired | 66 | 9 th | Low Average | n/a | 19th | Low Average |
| TOWRE-2 Phonemic Decoding Efficiency (Timed Pseudo Words) | 64 | 1 st | Moderate | 80 | 9 th | Low Average | n/a | 14th | Low Average |
| Single Word Spelling WJ-IV Spelling (real words) | 39 | 37 th | Average | 39 | 30 th | Average | | | |
| WJ-IV Rapid Picture Naming | 76 | 3 rd | Borderline | 105 | 25 th | Average | | | |

Overall, the results of the additional in-depth language testing confirmed preserved syntax, grammar and repetition (Table 3). Receptive and expressive vocabulary were average or above average, with only few errors in picture naming (on the hardest trials): *icegloo* instead of *igloo* (self-correct after the phonemic clue is provided), *harmonica* (identified correctly when offered multiple choices), and finally *yoke* and *trellis* (missed even with multiple choices). Similarly, Ms. C made mistakes only in the hardest trials of the sentence repetition task, i.e. on long non-meaningful sentences. A subtle

semantic deficit was detected, with performance on nonverbal semantic being worse than verbal one (51 out of 64 pictures were correctly matched vs. 57 out of 64 words), and a slightly disproportionate impairment for nonliving items as compared to living ones (with pictures: 24 vs. 27; with words: 27 vs. 30). Taken together, these findings corroborate the conclusion that Ms. C difficulties in reading cannot be explained by a loss of conceptual knowledge nor a generalized language impairment, but rather appear as an isolated, specific, impairment of reading processes.

Table 3. In-depth language evaluation. Receptive and expressive vocabulary, confrontation naming, repetition, syntax, grammar, and semantic knowledge were tested via both standardized and experimental tasks. * denotes raw scores rather than percentiles. Please see text for details.

| Domain | Assessment | Year 1 (2017) | | |
|--|---|---------------|------------|----------------------------|
| | | Raw Score | Percentile | Descriptive Term |
| Receptive and Expressive Vocabulary | | | | |
| | ROWPVT-4 | 173 | >99th | <i>V. Superior</i> |
| | EOWPVT-4 | 134 | 73rd | <i>Average</i> |
| Reading Comprehension | | | | |
| | CELF-5 Reading Comprehension | 18 | 50th | <i>Average</i> |
| Confrontation Naming | | | | |
| | Short BNT (max = 15) | 11 | ** | <i>Below Expectations</i> |
| Repetition | | | | |
| | Short Bayles (390 syllables) | | | |
| | <i>Short meaningful (max = 60)</i> | 60 | ** | <i>Within Expectations</i> |
| | <i>Short non-meaningful (max = 60)</i> | 60 | ** | <i>Within Expectations</i> |
| | <i>Long meaningful (max = 90)</i> | 90 | ** | <i>Within Expectations</i> |
| | <i>Long non-meaningful (max = 90)</i> | 80 | ** | <i>Below Expectations</i> |
| | <i>Long frequent (max = 90)</i> | 90 | ** | <i>Within Expectations</i> |
| Syntax and grammar | | | | |
| | Short NAT-UT (max = 12) | 12 | ** | <i>Within Expectations</i> |
| Semantic knowledge | | | | |
| | Camel and Cactus Test – words (max = 64) | 57 | ** | <i>Within Expectations</i> |
| | Camel and Cactus Test – pictures (max = 64) | 51 | ** | <i>Below Expectations</i> |

Anatomical Neuroimaging

Consistent with her hospital scans, the anatomical scan acquired 1-month post-stroke (year 1), showed a left ventral occipitotemporal cortical stroke with edema in the process of resorption (Fig. 1a). Sequelae are visible in the T1 images acquired 13 months post-stroke (Fig. 1b): tissue volume loss of the left occipital and temporal lobes, in particular the left fusiform gyrus (Brodmann Area 37). The lesion, mostly confined to the grey matter and with only minimal involvement of the underlying white matter, reaches (in MNI coordinates) as medial as $x=-36$ and as lateral as $x=-53$, as posterior as $y=-69$ and as anterior as $y=-48$, as superior as $z=-11$ and as ventral as $z=-28$. This is only slightly more lateral and inferior to the average coordinates of VWFA peak activation in healthy subjects (MNI coordinates $[-44,-58,-15]$ from meta-analysis by Jobard, Crivello, & Tzourio-Mazoyer, 2003).

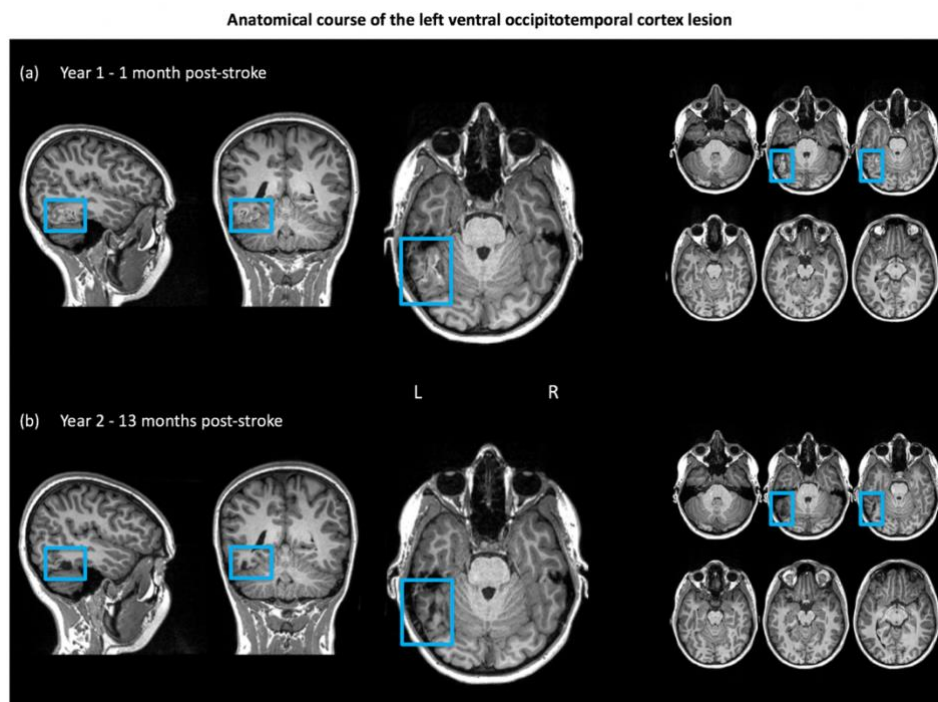


Figure 1. Structural neuroimaging findings. The left ventral occipitotemporal cortex lesion as shown in structural images (native space). (a) T1 scans acquired 1-month post-stroke: the light blue inserts highlight the cortical edema. (b) T1 scans acquired 13 months post-stroke showing the sequelae of the ischemic stroke.

Behavior during Functional Neuroimaging

The analysis of Ms. C behavioral performance during the Adaptive Language Mapping fMRI task conducted in the scanner indicates a progressive improvement in language processing, similar to the neuropsychological evaluations reported above. During the first-year assessment, overall accuracy was statistically different across the two tasks: semantic matching (language) = 81%, false font matching (visuoperceptual) = 89%, binomial test $p=0.04$. However, at the second-year assessment, performance across the two tasks did not statistically differ due to the fact that Ms. C's performance in the semantic condition greatly improves (semantic matching = 86%, false font matching = 88%, binomial test $p=0.5$) (Fig. 2 leftmost columns). The linear regression models fitted to the number of correct trials clearly highlight the difference between the two time points: performance in the semantic matching task peaks at level 2 at year 1 and level 7 at year 2. During the first evaluation, there is a significant negative trend across difficulty levels (slope=-0.24, $p=0.05$) while during the second evaluation a significant positive one (slope=0.23, $p=0.001$), and thus the linear regression fitted on the difference of the two trend is significant (-0.13, $p=0.003$). On the contrary, the performance in the false font matching task, always peaking at level 7, has an almost constant, significant slope: from 0.13 at year 1 ($p=0.03$) to 0.22 at year 2 ($p<0.001$). The linear regression fitted on the difference of the two trends (false font matching task at year 1 vs. year 2) is non-significant (0.05, $p=0.7$). Reaction times (RTs) were statistically different across tasks at both assessments: first year semantic matching = 1.7 ± 0.5 s vs. false font matching = 2 ± 0.4 s (t-test: $t = -2.26$, $p = 0.03$); second year semantic matching = 1.5 ± 0.3 s, false font matching = 1.6 ± 0.3 s (t-test: $t = -2.38$, $p = 0.02$). However, they are relatively constant across difficulty levels and time points as indicated by the fact that our analyses did not reveal any significant trend (Fig. 2 rightmost columns).

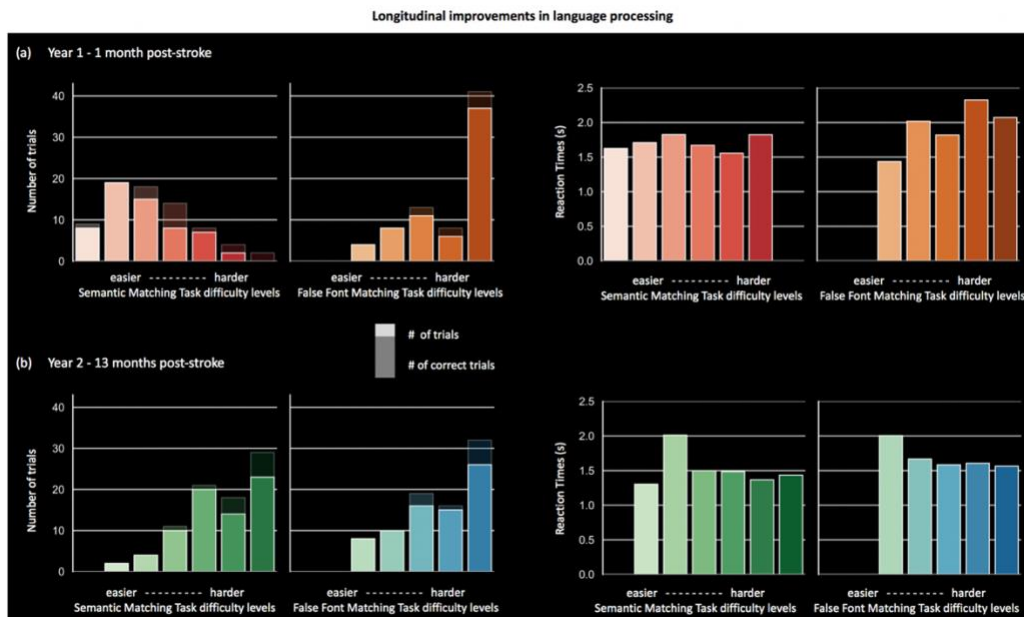


Figure 2. Behavioral performance during functional MRI. Visualization of the longitudinal improvement in language processing. **(a - left)** Shaded color bars indicate the total number of trials performed across the different difficulty levels in the semantic matching task (red) and the false font matching task (orange). Darker color bars illustrate the number of correct trials per each difficulty level. **(a - right)** Reaction times (in seconds) across the different difficulty levels in the semantic matching task (red) and the false font matching task (orange). **(b)** As in (a) but for year 2 (13 months post-stroke).

Functional Neuroimaging Activations

The fMRI Adaptive Language Mapping paradigm allowed whole-brain identification of the regions recruited for language processing at year 1 vs. year 2 (Fig. 3a-b, Table 4). Overall, the contrast semantic matching task > false font matching task highlighted very similar left-lateralized activations, yet at the second evaluation three additional clusters were detected (Fig. 3c).

| Time Point | Brain area | MNI coordinates | | | N voxels | P (FDR) | Max T |
|---------------|--------------------------------|-----------------|------|-----|----------|---------|-------|
| | | x | y | z | | | |
| Year 1 | | | | | | | |
| | left inferior frontal - BA 45 | -48 | 36 | 6 | 1873 | <0.001 | 26.2 |
| | left inferior frontal - BA 11 | -22 | 30 | -14 | 193 | <0.001 | 14.15 |
| | left frontal - BA 6 | -2 | 4 | 68 | 442 | <0.001 | 18.16 |
| | left frontal - BA 6 | -50 | -2 | 54 | 203 | <0.001 | 13.3 |
| | left fusiform - BA 37 | -62 | -54 | -10 | 248 | <0.001 | 18.08 |
| | left superior temporal - BA 22 | -62 | -28 | 2 | 155 | <0.001 | 17.85 |
| | left angular gyrus - BA 39 | -62 | -42 | 28 | 167 | <0.001 | 17.83 |
| | right cerebellum | 12 | -82 | -34 | 254 | <0.001 | 15.01 |
| | right cerebellum | 38 | -72 | -50 | 124 | <0.001 | 12.11 |
| Year 2 | | | | | | | |
| | left inferior frontal - BA 45 | -50 | 36 | 6 | 2749 | <0.001 | 28.98 |
| | left inferior frontal - BA 47 | -24 | 34 | -14 | 439 | <0.001 | 17.27 |
| | left frontal - BA 6 | -4 | 16 | 54 | 1109 | <0.001 | 20.6 |
| | left frontal - BA 6 | -36 | 6 | 44 | 537 | <0.001 | 20.28 |
| | left fusiform - BA 37 | -48 | -54 | -26 | 125 | <0.001 | 10.13 |
| | left superior temporal - BA 22 | -60 | -28 | 0 | 1808 | <0.001 | 19.06 |
| | left angular gyrus - BA 39 | -60 | -44 | 28 | 320 | <0.001 | 18.25 |
| | right occipital - BA 18 | 16 | -100 | 14 | 388 | <0.001 | 11.91 |
| | left V1 - BA 17 | -6 | -92 | 8 | 303 | <0.001 | 10.52 |
| | right cerebellum | 14 | -80 | -36 | 1325 | <0.001 | 15.19 |

Table 4. fMRI Adaptive Language Mapping clusters of significant activation. Whole brain results of the fMRI contrast semantic matching task > false font matching task described by clusters' MNI coordinates, extent, corrected p-value and t-value at the local maxima. The spatial distribution of these clusters can be appreciated in Fig. 3 (a) and (b) for year 1 and 2 respectively.

As expected, given the nature of the task, at both time points activations were found in the left inferior frontal lobe, in particular in the triangular part of inferior frontal gyrus (BA 45) and middle frontal gyrus, extending to the precentral sulcus and the posterior middle frontal gyrus. Additional clusters of significant activation included the left superior temporal sulcus and the middle temporal gyrus, as well as the left superior temporal (BA 22) and left angular (BA 39) gyri. Activations extended ventrally into the inferior temporal gyrus and the fusiform gyrus. Finally, two clusters were detected in the right occipital lobe and right cerebellum.

Longitudinal changes in language-related functional activations

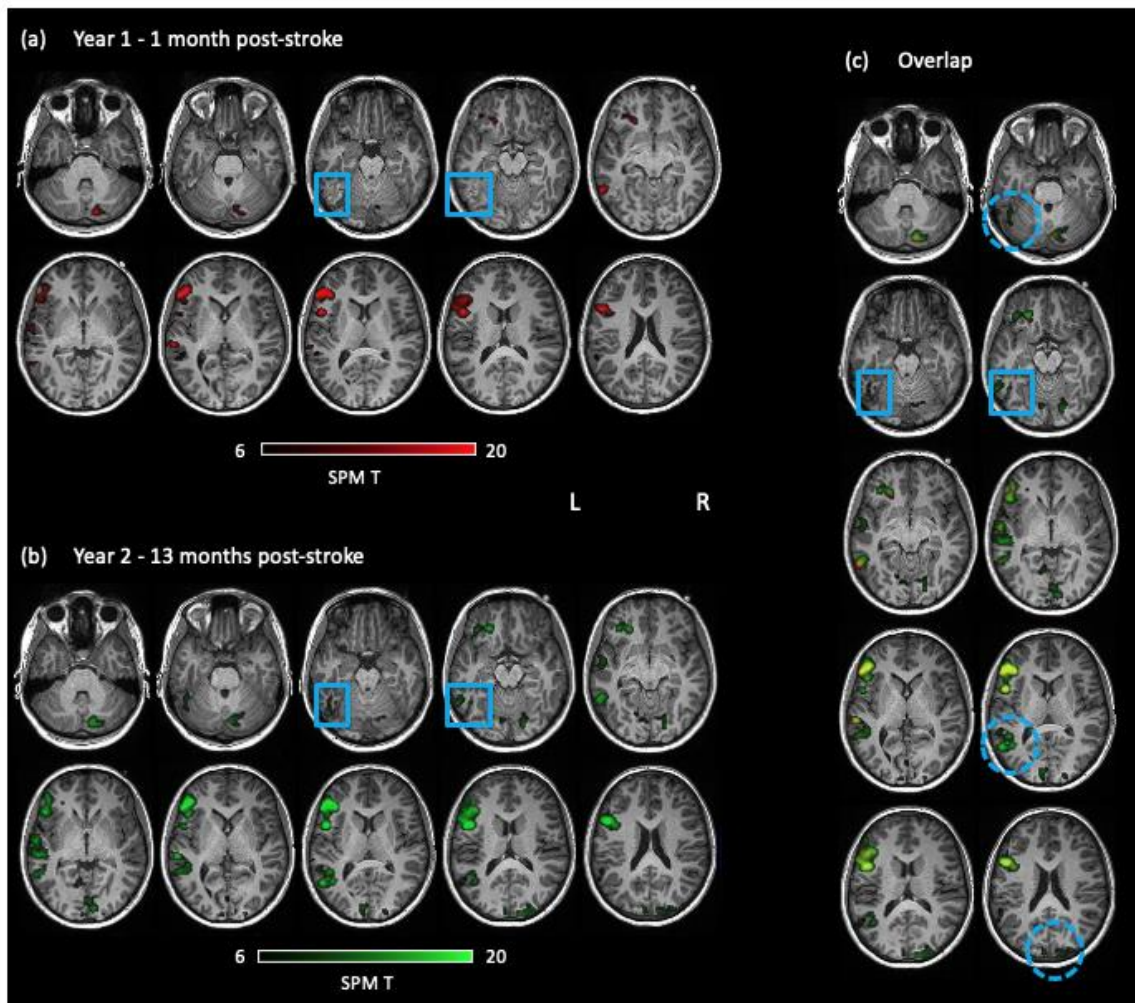


Figure 3. Functional neuroimaging findings. Whole brain results of the fMRI Adaptive Semantic Task indicating language-related activations (contrast: semantic matching task > false font matching task.) **(a)** Significant activations at year 1 overlaid on the normalized anatomical scans acquired 1 month post-stroke. Plotted clusters are thresholded at $p < .001$, FWR corrected, with a cluster extent threshold of 100 voxels. The light blue inserts highlight the left ventral occipitotemporal cortex lesion. **(b)** As in (a) but with functional and anatomical data acquired 13 months post-stroke. **(c)** Overlay of the year 1 (red) and year 2 (green) activations on the normalized anatomical scans acquired 13 months post-stroke (overlap in yellow). Plotted clusters are thresholded at $p < .001$, FDR corrected, with a cluster extent threshold of 100 voxels. The light blue squared inserts highlight the left ventral occipitotemporal cortex lesion while the circled dotted ones the clusters with more activations at year 2.

While overall the same language-related areas can be appreciated at both time points, it would appear that time 2 is characterized by generalized heightened activation

with the critical detection of three clusters not observed at time 1: bilateral primary and secondary visual areas, left posterior superior temporal gyrus, and left inferior temporal gyrus (Fig. 3c). This suggests that the observed improvement in behavioral performance is associated with the recruitment of perilesional and ipsilateral regions.

DISCUSSION

We longitudinally followed a 14-year-old left-handed girl who developed acquired dyslexia (i.e., slow and effortful reading) after sustaining a left ventral occipitotemporal ischemic stroke. The reading impairment resolved within one year and the behavioral changes were associated with heightened activity in the left posterior superior temporal gyrus and left inferior occipitotemporal gyrus. This pediatric case illustrates the critical role played by the left inferior occipitotemporal cortex in written language processing, while highlighting how recruitment of perilesional and ipsilateral cortical areas can support functional recovery after stroke.

Rapid and efficient reading relies on integrity of both ventral and dorsal language pathways for lexical retrieval and conversion from orthography to phonology (Hickok & Poeppel, 2004). Lesions along vOT posterior-to-anterior axis lead to deficits affecting visual input representations with increasing levels of complexity: from cortical blindness (Aldrich, Alessi, Beck, & Gilman, 1987), to pure alexia (Dejerine, 1892; Epelbaum et al., 2008), and finally semantic dementia (Hodges, Patterson, Oxbury, & Funnell, 1992; Snowden, Goulding, & Neary, 1989). Conversely, damage to the dorsal path has been associated with syndromes affecting phonological processing such as conduction aphasia (Damasio, H. & Damasio, 1980) and phonological agraphia (Roeltgen, Sevush, & Heilman, 1983). Ms. C's focal lesion affects a critical area lying at the point of divergence of the two pathways. As a result, the critical feature of her neuropsychological profile was an isolated, transient, acquired dyslexia, characterized by letter-by-letter reading and both length and regularity effects. Ms. C's behavioral performance indicates that the first stages of the reading process, common to both dorsal and ventral reading path, are spared by her lesion: low-level analysis of visually presented stimuli is unaffected (see

Table 1). Similarly spared are semantic and phonological representations, apexes of the two paths respectively (see Table 3). Ms. C's symptoms thus speak to a damage to the orthographic lexicon (Wimmer & Ludersdorfer, 2018).

Overall, the longitudinal multimodal data collected demonstrate that the neural correlates of her reading impairment is a lesion to the left vOT, and that its resolution within the following year is associated with recruitment of perilesional and ipsilateral cortices (Table 2, Figure 3). Thus, Ms. C's case speaks not only to the general role of vOT in reading but specifically to the great potential for recovery that this area exhibits during development. We believe that the timing of the lesion may have been critical: it follows reading acquisition and consolidation (i.e., after formal education), but precedes the functional and structural crystallization of the matured system. The mechanisms in place to sustain recovery after stroke might differ in childhood as compared to adult cases, with few studies systematically comparing short and long term outcomes across the two populations (Bigi et al., 2011; Goeggel Simonetti et al., 2015). A recent study by (Cohen, Dehaene, McCormick, Durant, & Zanker, 2016) describes an adult patient recovering from pure alexia via increasing responses in spared ipsilateral and contralateral occipital cortices. Remarkably, reading remained slow, letter-by-letter, suggesting that the fully developed reading system can only partially compensate for damage to the VWFA establishing an alternative occipital route unlike that of our adolescent patient. Ms. C, made a good recovery with a left-lateralized language system, likely related to her age at the time of the stroke as well as the size and location of the infarct: focal and rather ventro-lateral, thus sparing putative VWFA. Coherently, functional recovery has also been associated with activations of left-lateralized perilesional cortices in adults with relative sparing of VWFA (Purcell et al., 2017). Overall, our results are in line with recent findings, in both adults (Stockert et al., 2020) and children (Bartha-Doering et al., 2019), indicating that proper language recovery is more likely associated with restoration of function in perilesional, left-lateralized regions, rather than the recruitment of functionally unrelated contralateral networks. The phase of recovery appears critical, with evidence of a right-to-left shift as patients move from the acute to the chronic phase (Long, Sebastian, Faria,

& Hillis, 2018). Finally, our fMRI data also suggests involvement of the right cerebellum, in line with previous evidence implicating this region in language (Guell, Schmahmann, Gabrieli, & Ghosh, 2018; Koziol et al., 2014) thus calling for further investigations into the role of cerebellum in the functional recovery from strokes impacting vOT.

Compared to perinatal stroke (i.e., 28 weeks of gestation and 28 days of life), childhood stroke (i.e., 28 days to 18 years) is generally associated with better neurocognitive outcomes, yet some cognitive functions, such as executive functions and language, are more vulnerable than others (Keeffe, Murphy, Ganesan, & King, 2017; Peterson, Williams, McDonald, Dlamini, & Westmacott, 2019). Overall, a great variability is observed as a function of which cortical area is involved and at which stage of maturation (Liu & Behrmann, 2017). The effect of age at lesion, in particular, is thought to be nonlinear and results greatly vary across cognitive functions, suggesting that levels and mechanisms of plasticity are both age time and location sensitive (Allman, Scott, Allman, & Scott, 2013; Anderson et al., 2009). For language, it appears that laterality of perinatal strokes may not predict later language development, while left hemisphere strokes in older children often result in functional language impairments (Fuentes, Deotto, Desrocher, DeVeber, & Westmacott, 2016). Specifically concerning reading, while already left-lateralized by the age of 7 (Gaillard, Balsamo, Ibrahim, Sachs, & Xu, 2003), the reading system reaches adult-like functional properties only around the age of 10, after years of formal education (Aghababian & Nazir, 2000). This lengthened window in which the reading system is amenable to change represents its strength as well as its vulnerability. While it is possible to learn to read after early childhood lesions to left vOT, the outcomes will greatly vary (Cohen, 2004; Connelly, Cross, Boyd, Gadian, & Lie, 2004; Müller et al., 1999; Renaux-kieffer et al., 2002; Vargha-khadem, O’gorman, & Watters, 1985). Ms. C’s case demonstrates that full recovery of previously developed reading abilities is possible provided relative sparing of left vOT.

Typically, pure alexia appears among the sequelae of stroke lesions affecting the VWFA (Cohen et al., 2003; Pflugshaupt, Gutbrod, Wurtz, & Wartburg, 2009; Starrfelt, Habekost, & Leff, 2009), yet it has also been associated with its deafferentation

(Epelbaum et al., 2008; Maeshima & Osawa, 2011; Molko et al., 2002). Overall, these findings suggest that efficient reading requires both the integrity of left vOT as well as its capacity to receive proper inputs. Indeed, VWFA's critical role in the integration of orthographic, phonological and semantic representations is supported by short- and long-range white matter tracts connections to widespread language-related regions (Bouhali et al., 2014; Moulton et al., 2019; Yeatman, Rauschecker, & Wandell, 2013). In future studies, it would be important to assess how behavioral longitudinal changes relate not only to functional changes (as done here with fMRI), but also to damage (and recovery) of white matter tracts (as could be done with diffusion imaging). Similarly, a functional localizer should be used to functionally define VWFA at the single subject level whenever possible (e.g. Yeatman et al., 2013). Finally, one might wonder whether Ms. C's left-hand dominance played a role in her successful language recovery. However, while anomalous language activation is higher in non-right-handed population (Geschwind, Miller, DeCarli, & Carmelli, 2002; Szaflarski et al., 2012), Ms. C. fMRI results show predominant left hemisphere activation, cautioning against this interpretation. However, taken together with the right-lateralized occipital activation detected at time 2 (Fig.3b), Ms. C. left-handedness calls for further exploration of the role of the non-dominant hemisphere in (written) language processing (Cohen et al., 2003). It has been suggested that the right hemisphere has limited orthographic abilities allowing processing of high-frequency, concrete words (Coltheart 2000). To assess right hemisphere residual contribution to reading, one needs not only to carefully select the stimuli but also to rely on tasks such as tachistoscopic lexical decisions, where timed presentation prevents reliance on letter-by-letter strategy (Coslett & Saffran, 1994). Indeed, a recent careful study on the behavioral and structural consequences of a left posterior occipito-temporal stroke provides strong evidence in favor of the role of the right hemisphere in implicit reading (Bonandrini et al 2020). Unfortunately, the data we have on Ms. C's reading performance does not allow us to elaborate further.

A few other limitations of the present study need to be acknowledged. First of all, our data on Ms. C acute reading and spelling abilities are somewhat limited, preventing

us from framing this case as “pure alexia” or “surface dyslexia”. Moreover, the follow-up evaluations are based on clinical neuropsychological assessments only, as the clinical evaluations were necessary, and Ms. C had limited extra time for optional research evaluations. The fact that the follow-ups were administered in the clinic, has two major implications. First, in-depth language assessment was possible only at time 1 and lacks a longitudinal comparison. Second, we are limited in our ability to interpret scores variability, for instance Ms.C. nonverbal reasoning appears to drop from the 58th to the 9th percentile yet we cannot exclude confounding factors such as fatigue during testing. Finally, while no educational interventions were recorded in her medical chart, it is possible that accommodations or supports were put in place at home or at school.

In conclusion, while further studies are warranted to address the singular importance of the VWFA (Price & Devlin, 2003), this case report provides critical evidence on the resilience of the developing reading system following left ventral occipitotemporal ischemic stroke.

REFERENCES

- Aghababian, V., & Nazir, T. (2000). Developing Normal Reading Skills : Aspects of the Visual Processes Underlying Word Recognition, *150*, 123–150. <https://doi.org/10.1006/jecp.1999.2540>
- Aldrich, M. S., Alessi, A. G., Beck, R. W., & Gilman, S. (1987). Cortical blindness: Etiology, diagnosis, and prognosis. *Annals of Neurology*, *21*(2), 149–158. <https://doi.org/10.1002/ana.410210207>
- Allman, C., Scott, R. B., Allman, C., & Scott, R. B. (2013). Neuropsychological sequelae following pediatric stroke : A nonlinear model of age at lesion effects A nonlinear model of age at lesion effects, *7049*. <https://doi.org/10.1080/09297049.2011.639756>
- Anderson, V., Spencer-Smith, M., Leventer, R., Coleman, L., Anderson, P., Williams, J., ... Jacobs, R. (2009). Childhood brain insult: Can age at insult help us predict outcome? *Brain*, *132*(1), 45–56. <https://doi.org/10.1093/brain/awn293>
- Baker, C. I., Liu, J., Wald, L. L., Kwong, K. K., Benner, T., & Kanwisher, N. (2007). Visual word processing and experiential origins of functional selectivity of human extrastriate cortex. *Proceedings of the National Academy of Sciences*, *104*(21), 1–6.
- Bartha-Doering, L., Novak, A., Kollndorfer, K., Schuler, A. L., Kasprian, G., Langs, G., ... Seidl, R. (2019). Atypical language representation is unfavorable for language abilities following childhood stroke. *European Journal of Paediatric Neurology*,

- 23(1), 102–116. <https://doi.org/10.1016/j.ejpn.2018.09.007>
- Bayles, K. A., Tomoeda, C. K., & Rein, J. A. (1996). Phrase repetition in Alzheimer's disease: effect of meaning and length. *Brain and Language*, *54*(2), 246–261.
- Bigi, S., Fischer, U., Wehrli, E., Mattle, H. P., Boltshauser, E., Bürki, S., ... Arnold, M. (2011). Acute ischemic stroke in children versus young adults. *Annals of Neurology*, *70*(2), 245–254. <https://doi.org/10.1002/ana.22427>
- Bolger, D. J., Perfetti, C. A., & Schneider, W. (2005). Cross-cultural effect on the brain revisited: Universal structures plus writing system variation. *Human Brain Mapping*, *25*(1), 92–104. <https://doi.org/10.1002/hbm.20124>
- Bonandrini, R., Veronelli, L., Licciardo, D., Caporali, A., Judica, E., Corbo, M., & Luzzatti, C. (2020). Can the right hemisphere read? A behavioral and disconnectome study on implicit reading in a patient with pure alexia. *Neurocase*, *26*: 321–327.
- Bouhali, F., Schotten, M. T. De, Pinel, P., Poupon, C., Universite, S., Atomique, E., ... Yvette, G. (2014). Anatomical Connections of the Visual Word Form Area, *34*(46), 15402–15414. <https://doi.org/10.1523/JNEUROSCI.4918-13.2014>
- Bozeat, S., Lambon Ralph, M. A., Patterson, K., Garrard, P., & Hodges, J. R. (2000). Non-verbal impairment in semantic dementia. *Neuropsychologia*, *38*, 1207–1214.
- Cantlon, J. F., Pinel, P., Dehaene, S., & Pelphrey, K. A. (2011). Cortical representations of symbols, objects, and faces are pruned back during early childhood. *Cerebral Cortex*, *21*(1), 191–199. <https://doi.org/10.1093/cercor/bhq078>
- Caverzasi, E., Mandelli, M. L., Hoefl, F., Watson, C., Meyer, M., Allen, I. E., ... Gorno-Tempini, M. L. (2018). Abnormal age-related cortical folding and neurite morphology in children with developmental dyslexia. *NeuroImage: Clinical*, *18*(August 2017), 814–821. <https://doi.org/10.1016/j.nicl.2018.03.012>
- Centanni, T. M., King, L. W., Eddy, M. D., Whitfield-gabrieli, S., & Gabrieli, J. D. E. (2017). Brain & Language Development of sensitivity versus specificity for print in the visual word form area. *Brain and Language*, *170*, 62–70. <https://doi.org/10.1016/j.bandl.2017.03.009>
- Cohen, L., Martinaud, O., Lemer, C., & Lehericy, S. (2003). Visual Word Recognition in the Left and Right Hemispheres : Anatomical and Functional Correlates of Peripheral Alexias, (December), 1313–1333. <https://doi.org/10.1093/cercor/bhg079>
- Cohen, Laurent. (2004). Learning to Read without a Left Occipital Lobe : Right-Hemispheric Shift of Visual Word Form Area, *12*, 890–894. <https://doi.org/10.1002/ana.20326>
- Cohen, Laurent, Dehaene, S., McCormick, S., Durant, S., & Zanker, J. M. (2016). Brain mechanisms of recovery from pure alexia : A single case study with multiple longitudinal scans. *Neuropsychologia*, *91*, 36–49. <https://doi.org/10.1016/j.neuropsychologia.2016.07.009>
- Cohen, Laurent, Dehaene, S., Naccache, L., Lehericy, S., Dehaene-Lambertz, G., Hénaff, M.-A., & Michel, F. (2000). The visual word form area: spatial and temporal characterization of an initial stage of reading in normal subjects and posterior split-brain patients. *Brain* *123* (Pt2): 291307
- Corbetta M, Shulman GL (2002) Control of goal-directed and stimulus-driven attention. *Brain: A Journal of Neurology*, *123*, 291–307.

- Cohen, Laurent, Lehericy, S., Chochon, F., Lemer, C., Rivaud, S., & Dehaene, S. (2002). Language-specific tuning of visual cortex? Functional properties of the Visual Word Form Area. *Brain*, 125(5), 1054–1069. <https://doi.org/10.1093/brain/awf094>
- Cohen, L., Martinaud, O., Lemer, C., Lehericy, S., Samson, Y., Obadia, M., Slachevsky, A. and Dehaene, S., 2003. Visual word recognition in the left and right hemispheres: anatomical and functional correlates of peripheral alexias. *Cerebral cortex*, 13(12), pp.1313-1333.
- Coltheart, M. (2000). Deep dyslexia is right-hemisphere reading. *Brain and Language*, 71(2), 299–309. <https://doi.org/10.1006/brln.1999.2183>
- Connelly, A., Cross, J. H., Boyd, S. G., Gadian, D. G., & Lie, F. (2004). Language reorganization in children with early-onset lesions of the left hemisphere : an fMRI study, 127(6). <https://doi.org/10.1093/brain/awh159>
- Coslett, H. B. & Saffran, E. M. (1994). Mechanisms of implicit reading in alexia. In M. Farah & G. Ratcliff (Eds.), *The Neuropsychology of high-level vision* (pp. 299–330). Lawrence Erlbaum Associates.
- Damasio, H., & Damasio, A. (1980). The anatomical basis of conduction aphasia. *Brain*, (103), 337–350. <https://doi.org/10.1159/000412318>
- Dehaene, S., & Cohen, L. (2011). The unique role of the visual word form area in reading. *Trends in Cognitive Sciences*, 15(6), 254–262. <https://doi.org/10.1016/j.tics.2011.04.003>
- Dehaene, S., Cohen, L., Sigman, M., & Vinckier, F. (2005). The neural code for written words: A proposal. *Trends in Cognitive Sciences*, 9(7), 335–341. <https://doi.org/10.1016/j.tics.2005.05.004>
- Dehaene, S., Gurvan, L. C., Poline, J., Bihan, D. Le, & Cohen, L. (2006). The visual word form area: a prelexical representation of visual words in the fusiform gyrus, 13(3). <https://doi.org/10.1097/00001756-200203040-00015>
- Dehaene, S., Naccache, L., Cohen, L., Bihan, D. Le, Mangin, J.-F., Poline, J.-B., & Rivière, D. (2001). Cerebral mechanisms of word masking and unconscious repetition priming. *Nature Neuroscience*, 4(7), 752–758.
- Dehaene, S., Pegado, F., Braga, L. W., Ventura, P., Nunes Filho, G., Jobert, A., ... Cohen, L. (2010). How learning to read changes the cortical networks for vision and language. *Science (New York, N.Y.)*, 330(6009), 1359–1364. <https://doi.org/10.1126/science.1194140>
- Dejerine, J. (1892). Contribution à l'étude anatomopathologique et clinique des différents variétés de cécité verbale. *Mémoires de La Société de Biologie*, 4, 61–90.
- Epelbaum, S., Pinel, P., Gaillard, R., Delmaire, C., Perrin, M., Dupont, S., ... Cohen, L. (2008). Pure alexia as a disconnection syndrome: New diffusion imaging evidence for an old concept. *Cortex*, 44(8), 962–974. <https://doi.org/10.1016/j.cortex.2008.05.003>
- Frauwirth, S., Michalec, D., & Henninger, N. (2017). Expressive One-Word Picture Vocabulary Test. In J. Kreutzer, J. DeLuca, & B. Caplan (Eds.), *Encyclopedia of Clinical Neuropsychology* (pp. 1–3). Cham: Springer International Publishing. https://doi.org/10.1007/978-3-319-56782-2_1544-2
- Friedman, R.B. and Hadley, J.A., 1992. by-letter surface alexia. *Cognitive*

- Neuropsychology, 9(3), pp.185-208.
- Fuentes, A., Deotto, A., Desrocher, M., DeVeber, G., & Westmacott, R. (2016). Determinants of cognitive outcomes of perinatal and childhood stroke: A review. *Child Neuropsychology*, 22(1), 1–38. <https://doi.org/10.1080/09297049.2014.969694>
- Gaillard, W. D., Balsamo, L. M., Ibrahim, Z., Sachs, B. C., & Xu, B. (2003). fMRI identifies regional specialization of neural networks for reading in young children.
- Gauthier, I., Tarr, M. J., Moylan, J., Skudlarski, P., Gore, J. C., & Anderson, A. W. (2000). The fusiform “face area” is part of a network that processes faces at the individual level. *Journal of Cognitive Neuroscience*, 12(3), 495–504. <https://doi.org/10.1162/089892900562165>
- Geschwind, D. H., Miller, B. L., DeCarli, C., & Carmelli, D. (2002). Heritability of lobar brain volumes in twins supports genetic models of cerebral laterality and handedness. *Proceedings of the National Academy of Sciences of the United States of America*, 99(5), 3176–3181. <https://doi.org/10.1073/pnas.052494999>
- Goeggel Simonetti, B., Cavelti, A., Arnold, M., Bigi, S., Regényi, M., Mattle, H. P., ... Fischer, U. (2015). Long-term outcome after arterial ischemic stroke in children and young adults. *Neurology*, 84(19), 1941–1947. <https://doi.org/10.1212/WNL.0000000000001555>
- Golarai, G., Ghahremani, D. G., Whitfield-Gabrieli, S., Reiss, A., Eberhardt, J. L., Gabrieli, J. D. E., & Grill-Spector, K. (2007). Differential development of high-level visual cortex correlates with category-specific recognition memory. *Nature Neuroscience*, 10(4), 512–522. <https://doi.org/10.1038/nn1865>
- Grill-Spector, K., & Weiner, K. S. (2014). The functional architecture of the ventral temporal cortex and its role in categorization. *Nature Reviews Neuroscience*, 15(8), 536–548. <https://doi.org/10.1038/nrn3747>
- Guell, X., Schmahmann, J. D., Gabrieli, J. D. E., & Ghosh, S. S. (2018). Functional gradients of the cerebellum. *ELife*, 7, 1–22. <https://doi.org/10.7554/eLife.36652>
- Hickok, G., & Poeppel, D. (2004). Dorsal and ventral streams : a framework for understanding aspects of the functional anatomy of language, 92, 67–99. <https://doi.org/10.1016/j.cognition.2003.10.011>
- Hodges, J. R., Patterson, K., Oxbury, S., & Funnell, E. (1992). Semantic dementia. Progressive fluent aphasia with temporal lobe atrophy. *Brain*, 115, 1783–1806. <https://doi.org/10.1093/brain/115.6.1783>
- Jobard, G., Crivello, F., & Tzourio-Mazoyer, N. (2003). Evaluation of the dual route theory of reading: A metanalysis of 35 neuroimaging studies. *NeuroImage*, 20(2), 693–712. [https://doi.org/10.1016/S1053-8119\(03\)00343-4](https://doi.org/10.1016/S1053-8119(03)00343-4)
- Keeffe, F. O., Murphy, O., Ganesan, V., & King, J. (2017). Neuropsychological outcome following childhood stroke – a review. *Brain Injury*, 31(12), 1575–1589. <https://doi.org/10.1080/02699052.2017.1332782>
- Koziol, L. F., Budding, D., Andreasen, N., D’Arrigo, S., Bulgheroni, S., Imamizu, H., ... Yamazaki, T. (2014). Consensus paper: the cerebellum’s role in movement and cognition. *Cerebellum (London, England)*, 13(1), 151–177. <https://doi.org/10.1007/s12311-013-0511-x>

- Kramer, J. H., Jurik, J., Sha, S. J., Rankin, K. P., Rosen, H. J., Johnson, J. K., & Miller, B. L. (2003). Distinctive Neuropsychological Patterns in Frontotemporal Dementia, Semantic Dementia, and Alzheimer Disease. *Cognitive and Behavioral Neurology*, *16*(4), 211–218. <https://doi.org/10.1097/00146965-200312000-00002>
- Liu, T. T., & Behrmann, M. (2017). Functional outcomes following lesions in visual cortex. *Neuropsychologia*, 197–214. <https://doi.org/10.1016/j.neuropsychologia.2017.06.030>
- Long, C., Sebastian, R., Faria, A. V., & Hillis, A. E. (2018). Longitudinal imaging of reading and naming recovery after stroke. *Aphasiology*, *32*(7), 839–854. <https://doi.org/10.1080/02687038.2017.1417538>
- Mack, W. J., Freed, D. M., Williams, B. W., & Henderson, V. W. (1992). Boston Naming Test: shortened versions for use in Alzheimer's disease. *Journal of Gerontology*, *47*(3), P154–P158.
- Maeshima, S., & Osawa, A. (2011). Pure alexia caused by separate lesions of the splenium and optic radiation, 223–226. <https://doi.org/10.1007/s00415-010-5723-0>
- Maisog, J. M., Einbinder, E. R., Flowers, D. L., Turkeltaub, P. E., & Eden, G. F. (2008). A meta-analysis of functional neuroimaging studies of dyslexia. *Annals of the New York Academy of Sciences*, *1145*, 237–259. <https://doi.org/10.1196/annals.1416.024>
- Marinkovic, K., Dhond, R. P., Dale, A. M., Glessner, M., Carr, V., & Halgren, E. (2003). Spatiotemporal dynamics of modality-specific and supramodal word processing. *Neuron*, *38*(3), 487–497. [https://doi.org/10.1016/S0896-6273\(03\)00197-1](https://doi.org/10.1016/S0896-6273(03)00197-1)
- Marshall JC, Newcombe F. Patterns of paralexia: a psycholinguistic approach. *J Psycholinguist Res* 1973; 2: 175–99.
- Molko, N., Cohen, L., Mangin, J. F., Chochon, F., Bihan, D. Le, Dehaene, S., & Lehe, S. (2002). Visualizing the Neural Bases of a Disconnection Syndrome with Diffusion Tensor Imaging. *Journal of Cognitive Neuroscience*, *14*(4), 629–636.
- Moulton, E., Bouhali, F., Monzalvo, K., Poupon, C., Zhang, H., Dehaene, S., ... Jessica, L. (2019). Connectivity between the visual word form area and the parietal lobe improves after the first year of reading instruction : a longitudinal MRI study in children. *Brain Structure and Function*, *224*(4), 1519–1536. <https://doi.org/10.1007/s00429-019-01855-3>
- Müller, R. A., Rothermel, R. D., Behen, M. E., Muzik, O., Chakraborty, P. K., & Chugani, H. T. (1999). Language organization in patients with early and late left-hemisphere lesion: A PET study. *Neuropsychologia*, *37*(5), 545–557. [https://doi.org/10.1016/S0028-3932\(98\)00109-2](https://doi.org/10.1016/S0028-3932(98)00109-2)
- Olulade, O. A., Flowers, D. L., Napoliello, E. M., & Eden, G. F. (2013). Developmental differences for word processing in the ventral stream. *Brain and Language*, *125*(2), 134–145. <https://doi.org/10.1016/j.bandl.2012.04.003>
- Peterson, R. K., Williams, T. S., McDonald, K. P., Dlamini, N., & Westmacott, R. (2019). Cognitive and Academic Outcomes Following Childhood Cortical Stroke. *Journal of Child Neurology*, 088307381986660. <https://doi.org/10.1177/0883073819866609>
- Pflugshaupt, T., Gutbrod, K., Wurtz, P., & Wartburg, R. Von. (2009). About the role of

- visual field defects in pure alexia. <https://doi.org/10.1093/brain/awp141>
- Price, C. J., & Devlin, J. T. (2003). The myth of the visual word form area. *NeuroImage*, *19*(3), 473–481. [https://doi.org/10.1016/S1053-8119\(03\)00084-3](https://doi.org/10.1016/S1053-8119(03)00084-3)
- Purcell, J., Sebastian, R., Leigh, R., Jarso, S., Davis, C., Posner, J., ... Hillis, A. E. (2017). ScienceDirect Recovery of orthographic processing after stroke : A longitudinal fMRI study. *CORTEX*, *92*, 103–118. <https://doi.org/10.1016/j.cortex.2017.03.022>
- Renaux-kieffer, V., Hertz-pannier, L., Chiron, C., Jambaque, I., Moortele, È. Van De, Delalande, O., ... Bihan, D. Le. (2002). Late plasticity for language in a child ' s non-dominant hemisphere A pre- and post-surgery fMRI study.
- Richlan, F., Kronbichler, M., & Wimmer, H. (2011). Meta-analyzing brain dysfunctions in dyslexic children and adults. *NeuroImage*, *56*(3), 1735–1742. <https://doi.org/10.1016/j.neuroimage.2011.02.040>
- Richlan, F., Kronbichler, M., & Wimmer, H. (2013). Structural abnormalities in the dyslexic brain: A meta-analysis of voxel-based morphometry studies. *Human Brain Mapping*, *34*(11), 3055–3065. <https://doi.org/10.1002/hbm.22127>
- Roeltgen, D. P., Sevush, S., & Heilman, K. M. (1983). Phonological agraphia : Writing by the lexical-semantic route, (April 1982), 755–766.
- Schrank, F. A., Mather, N., & McGrew, K. S. (2014). *Woodcock-Johnson IV tests of achievement*. Riverside Publ.
- Snowden, J., Goulding, P., & Neary, D. (1989). Semantic dementia: A form of circumscribed cerebral atrophy. *Behavioural Neurology*, *2*(3), 167–182. https://doi.org/MCI-Converted #101; Thesis_references-Converted #324
- Starrfelt, R., Habekost, T., & Leff, A. P. (2009). Too Little , Too Late : Reduced Visual Span and Speed Characterize Pure Alexia, (December). <https://doi.org/10.1093/cercor/bhp059>
- Stockert, A., Wawrzyniak, M., Klingbeil, J., Wrede, K., Hartwigsen, G., Kaller, C. P., ... Saur, D. (2020). Dynamics of language reorganization after left temporo-parietal and frontal stroke. <https://doi.org/10.1093/brain/awaa023>
- Szaflarski, J. P., Ward, B. D., Binder, J. R., McKiernan, K. A., Hammeke, T. A., & Possing, E. T. (2012). Language lateralization in left-handed and ambidextrous people. *Neurology*, *59*(2), 238–244.
- Torgesen, J. K., Wagner, R. K., & Rashotte, C. A. (2012). *TOWRE-2 Examiner's Manual*. Austin, TX: Pro-Ed.
- Vargha-khadem, F., O'gorman, A. M., & Watters, G. V. (1985). Aphasia and handedness in relation to hemispheric side, age at injury and severity of cerebral lesion during childhood. *Brain*, *108*(3), 677–696. <https://doi.org/10.1093/brain/108.3.677>
- Vinckier, F., Dehaene, S., Jobert, A., Dubus, J. P., Sigman, M., & Cohen, L. (2007). Hierarchical Coding of Letter Strings in the Ventral Stream: Dissecting the Inner Organization of the Visual Word-Form System. *Neuron*, *55*(1), 143–156. <https://doi.org/10.1016/j.neuron.2007.05.031>
- Weintraub, S., Mesulam, M.-M., Wieneke, C., Rademaker, A., Rogalski, E. J., & Thompson, C. K. (2009). The northwestern anagram test: measuring sentence production in primary progressive aphasia. *American Journal of Alzheimer's Disease & Other Dementias*®, *24*(5), 408–416.

- Wiederholt, J. L., & Bryant, B. R. (2012). *Gray oral reading tests—fifth edition (GORT-5)*. Austin, TX: Pro-Ed.
- Wiig, E. H., Secord, W. A., & Semel, E. (2013). *Clinical evaluation of language fundamentals: CELF-5*. Pearson.
- Wilson, S., Yen, M., & Eriksson, D. (2018). An adaptive semantic matching paradigm for reliable and valid language mapping in individuals with aphasia, (February). <https://doi.org/10.1002/hbm.24077>
- Wimmer, H. and Ludersdorfer, P., 2018. Searching for the orthographic lexicon in the visual word form area. In *Reading and Dyslexia* (pp. 57-69). Springer, Cham.
- Yeatman, J. D., Rauschecker, A. M., & Wandell, B. A. (2013). Anatomy of the visual word form area: Adjacent cortical circuits and long-range white matter connections. *Brain and Language*, 125(2), 146–155. <https://doi.org/10.1016/j.bandl.2012.04.010>

Acknowledgments

This research was supported by the Charles and Helen Schwab Foundation. N.D. was supported by NIH/NIDCD R01-DC016345. These supporting sources were not involved in the study design, collection, analysis or interpretation of data, nor were they involved in writing the paper or the decision to submit this report for publication. The authors thank the patient and her family for the time and effort they dedicated to the research.

Declaration of interest statement

None to be declared.