
Mandibular paresthesia secondary to cerebrovascular changes

Lyle W. Nelson, D.M.D.,* William T. Johnson, D.D.S., M.S.,** and David A. Blaha, D.D.S.,*** Omaha and Lincoln, Neb.

UNIVERSITY OF NEBRASKA MEDICAL CENTER

An unusual case of mandibular paresthesia as the only presenting symptom of a cerebrovascular accident is presented. The differential diagnosis of inferior alveolar nerve paresthesia is discussed. Obtaining a definitive diagnosis depends on a thorough medical and dental history complemented by a complete clinical and radiographic examination. The etiology of cerebral vascular accidents is reviewed, as well as risk factors that may increase the possibility of a cerebrovascular accident.

(ORAL SURG. ORAL MED. ORAL PATHOL. 62:17-19, 1986)

Patients with the chief complaint of inferior alveolar nerve paresthesia unrelated to a dental or surgical procedure are rare. Paresthesia is more commonly seen following the injection of local anesthetic agents, endodontic procedures, mandibular fractures, and mandibular surgical procedures. Removal of mandibular third molars, orthognathic surgery, and excisional biopsies are common surgical procedures that may produce paresthesia. The diagnosis of paresthesia related to the above situations is based primarily on the dental history.

Paresthesias that are unrelated to dental procedures or trauma are more difficult to diagnose. Possible causes of inferior alveolar nerve paresthesia include systemic diseases, such as diabetes and hypothyroidism,¹ as well as deficiency states, such as pellagra and pernicious anemia.¹ Paresthesia is most frequently associated with malignant or inflammatory lesions.¹⁻³ A less likely explanation for the occurrence of inferior alveolar paresthesia involves cerebral ischemia and infarction involving the trigeminal nerve fibers.

A cerebrovascular accident can result from cerebral ischemia resulting in infarction or from intracranial hemorrhage. Cerebral ischemia and infarction account for more than 85% of all cerebro-

vascular accidents and can be related to atherosclerotic vessels and/or thrombus formation. Intracranial hemorrhages account for approximately 10% of all cerebrovascular accidents and can be attributed to aneurysms and hypertensive vascular disease.⁴

Cerebrovascular accidents are not uncommon in the adult population, with 25% of the routine autopsies demonstrating evidence of a previous cerebrovascular accident.⁴ The average age of persons at the time of their first cerebrovascular accident is 64 years.⁴ Factors significantly increasing the chance for a cerebrovascular accident include hypertension, diabetes mellitus, cardiac enlargement, hypercholesterolemia, the use of oral contraceptives, and cigarette smoking.⁴

Elimination of the various possibilities from a differential diagnosis involving paresthesia is based on history, clinical examination, laboratory studies, and biopsy techniques. The following case is presented as an example of a cerebrovascular accident with mandibular paresthesia as the only presenting symptom.

CASE REPORT

A 27-year-old white woman came to the University of Nebraska Medical Center College of Dentistry with a chief complaint of mandibular paresthesia. The patient had noticed "a numbness" on awakening that morning and stated that the sensation had not been present at any time previously. She believed the paresthesia to be secondary to a firm mass located in the left mandibular vestibule. She denied odontogenic pain, thermal sensitivity, tenderness to percussion, or drainage from this region.

*Resident, Department of Oral and Maxillofacial Surgery.

**Assistant Professor, Department of Endodontics.

***In the private practice of oral surgery, Lincoln, Neb.

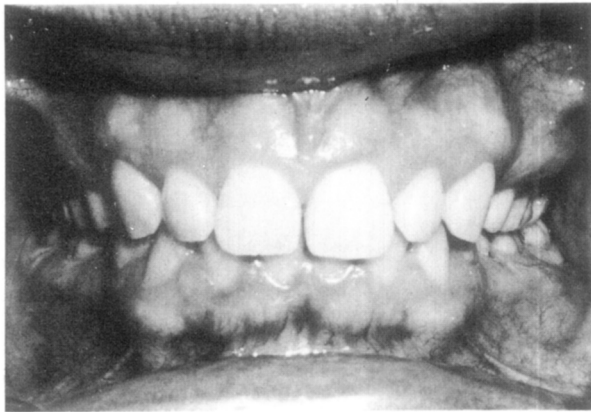


Fig. 1. Clinical photograph of left mandibular posterior area showing mass adjacent to mandibular left first and second molars.

The patient's dental history revealed that she had come to the dental college 4 months previously complaining of a cyclic swelling in the mandibular left molar region of her mouth. She reported that when the mass decreased in size there would be a foul taste in her mouth. When the clinical examination revealed no significant abnormalities, the patient was advised to return to the clinic when the swelling recurred.

A review of the patient's medical history revealed an allergy to codeine and sulfonamides and indicated that she was currently taking oral contraceptives. The patient also related a history of several fainting spells, lasting anywhere from a few seconds to several minutes, with no evidence of tonic or clonic seizures; the most recent fainting spell had occurred 2 years previously. The patient also reported that she had shingles in 1975. In addition, she indicated that she smoked.

Physical examination showed a blood pressure of 130/80 and a pulse rate of 80, which was regular. Clinical examination of the patient's sensory responses revealed paresthesia in the distribution of both the left lingual and left inferior alveolar nerves. There was a decreased response to both pinprick and light touch. A firm, nontender, and nonmoveable mass approximately 1 cm in diameter was noted on the lateral surface of the mandible in the buccal vestibule adjacent to the mandibular left first and second molars (Fig. 1). The lesion was approximately 1 cm from the crest of the ridge, with normal overlying epithelium. The dentition was in good repair, with occlusal restorations in the mandibular first and second molars. A fixed lingual retainer was present from one mandibular cuspid to the opposite mandibular cuspid. Electrical pulp testing of the left mandibular teeth showed all teeth to be responsive, with no abnormal responses to heat, cold, or percussion. Examination of the neck and the remainder of the physical examination revealed structures within normal limits.

Panoramic and periapical radiographs of the involved region showed a condensation of bone, approximately 5 × 5 mm, inferior to the distal root of the mandibular left

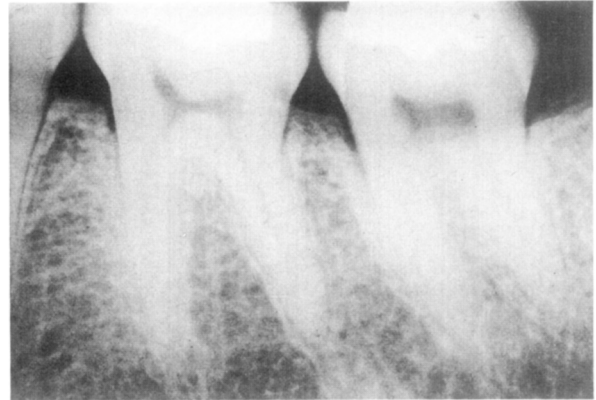

Fig. 2. Periapical radiograph of mandibular left molar region.

first molar (Fig. 2). The remainder of the radiographic findings were within normal limits.

Although the lesion was thought most likely to represent an exostosis, a biopsy was advised because of the patient's dental history, symptoms and concerns, and to eliminate the possibility of malignant disease. The biopsy procedure was scheduled for later the same week. The patient was also referred to a neurologist because of the distribution of the paresthesia, which involved both the left inferior alveolar and lingual nerves.

On returning for biopsy, the patient reported that the original mandibular paresthesia was unchanged. However, over the intervening period of time she had noted a slurring of speech, numbness in the left arm and hand, and the onset of severe migrainelike headaches in the right temporofrontal and retro-orbital regions. In addition, she related that her co-workers had noticed an asymmetry of her face and smile.

A biopsy specimen of the mandibular lesion was obtained with the aid of local anesthesia. Histologic examination revealed dense viable bone consistent with exostosis.

In view of the patient's additional symptoms, a consultation with the neurologist was scheduled for the same afternoon. Upon examination of the patient, the neurologist scheduled her for a CT scan of the head and in addition, obtained an antinuclear antibody titer, a complete blood count, and determination of prothrombin time, partial thromboplastin time, and erythrocyte sedimentation rate. He also advised her to discontinue using the birth control pills and to begin taking one aspirin tablet per day. She was also given a prescription for butalbital and aspirin (Fiorinal) for her migrainelike headaches. While the results of all tests performed were negative, a diagnosis of right pontine brain-stem stroke was made on the basis of the patient's history, symptoms, and physical examination findings. This was thought to be a vasospastic stroke related to the combination of migrainelike headaches and the use of oral contraceptives.

Three months after the initial examination the patient reported a marked improvement in sensation on the left side of her face and arm. In addition, the frequency of her

migrainelike headaches had decreased significantly. The patient was continued on her medications. She was also advised to return if her headaches increased in frequency or severity or if her paresthesia or weakness returned.

DISCUSSION

An unusual case of inferior alveolar paresthesia secondary to a cerebrovascular accident has been presented. This case is unique in that paresthesia of the trigeminal nerve was the initial presenting symptom. A review of the current literature suggests a relationship between oral contraceptives and strokes.⁵⁻⁹ This relationship is further enhanced if the patient is a smoker or has migrainelike headaches.⁵⁻⁹ Birth control pills alone have been reported to cause migrainelike headaches with an associated cerebral ischemia (either permanent or transient).⁶⁻⁸ This patient exhibited several factors that placed her at significant risk for a cerebrovascular accident. Treatment of this patient involved discontinuing the oral contraceptives, which resulted in a decreased incidence of the headaches and an improvement in the paresthesia.

The experience gained in this case suggests that when a patient is seen with a chief complaint of facial paresthesia, a thorough medical history should be obtained and clinical and physical examinations

should be performed. The patient should be questioned regarding symptoms that might suggest a cerebrovascular accident as being the cause of the paresthesia.

REFERENCES

1. Shafer WG, Hine MK, Levy BM: A textbook of oral pathology, ed. 4, Philadelphia, 1983, W.B. Saunders Company.
2. Lilly GE: Differential diagnosis of lesions of the jawbones. *J Oral Surg* **28**: 65, 1970.
3. Kerr DA, Ash MM, Millard HD: Oral diagnosis, ed. 5, St. Louis, 1978, The C. V. Mosby Company.
4. Malamed SF: Cerebral vascular accident. In *Handbook of medical emergencies in the dental practice*, ed. 2, St. Louis, 1982, The C. V. Mosby Company, pp. 210-223.
5. Beck WW: Complications and contraindications of oral contraception. *Clin Obstet Gynecol* **24**: 893-901, 1981.
6. Dalen JE, Hickler RB: Oral contraceptives and cardiovascular disease. *Am Heart J* **101**: 626-639, 1981.
7. Huppert LC: Vascular effects of hormonal contraception. *Clin Obstet Gynecol* **24**: 951-963, 1981.
8. Kelly TM: Systemic effects of oral contraceptives. *West J Med* **141**: 113-116, 1984.
9. Longstreth WT, Swanson PD: Oral contraceptives and stroke. *Stroke* **15**: 747-750, 1982.

Reprint requests to:

Dr. Lyle W. Nelson
Department of Oral and Maxillofacial Surgery
University of Nebraska Medical Center
42nd and Dewey Ave
Omaha, NE 68105