

Short Communications

Ataxic Hemiparesis with Reductions of Ipsilateral Cerebellar Blood Flow

FUMIHIKO SAKAI, M.D., SHINPEI AOKI, M.D.,* SHINICHI KAN, M.D., HISAKA IGARASHI, M.D.,
TADASHI KANDA, M.D., YOSHIKI TAZAKI, M.D.

SUMMARY Regional cerebellar blood flow was measured in a patient with left-sided ataxic hemiparesis, using single-photon emission computed tomography and N-isopropyl-p-[¹²³I]Iodoamphetamine. X-ray computed tomography revealed a small infarct in the paramedian portion of the right upper basis pontis. Blood flow was markedly reduced in the contralateral cerebellar hemisphere corresponding to the side of ataxia. The present study emphasizes the value of the three-dimensional functional imaging of the cerebellum to investigate the responsible lesion for ataxia and to study function of the cerebro-cerebellar circuits.

Stroke Vol 17, No 5, 1986

IN 1978, Fisher¹ reported a pathological study of three patients with sudden onset of weakness and cerebellar ataxia of the same side. He suggested that this unusual combination of ipsilateral hemiparesis and ataxia is caused by a lacunar infarct in the upper basis pontis, and he proposed that the designation "ataxic hemiparesis" should be used to supplant the previously designated "homolateral ataxia with crural paresis" which he himself reported in 1967.² In subsequently reported cases of ataxic hemiparesis, however, the location of CT lesions were rather diverse including not only the basis pontis³ but also the internal capsule,^{4,5} corona radiata⁶ and midbrain.⁷ Based on these variable localizations of CT lesions, some authors^{8,9} speculate that there are several regions where a small lesion may damage both the pyramidal tract and the cerebro-cerebellar circuit. However, it has been a difficult question to settle whether the ataxia or dysmetria on the side of weakness is actually due to cerebellar dysfunction.

We report a case of ataxic hemiparesis in which a lacunar infarct was confirmed in the basis pontis by CT scan and the reduction of contralateral cerebellar blood flow was measured by single-photon emission computed tomography and N-isopropyl-p-[¹²³I]Iodoamphetamine.

Report of a Case

A 70-year-old, right handed, diabetic woman experienced three episodes of transient and mild weakness of the left arm and leg for two days prior to admission. The first episode was associated with slurred speech and the third with nausea. She was able to walk but tended to fall to the left. On the day of admission, she

From the Departments of Medicine, and Radiology,* School of Medicine, Kitasato University, 1-15-1 Kitasato, Sagami-hara, Kanagawa-ken 228, Japan.

Nihon Medi-Physics Co., Ltd. in Japan provided the N-isopropyl-p-[¹²³I]Iodoamphetamine.

Address correspondence to: Fumihiko Sakai, M.D., Department of Medicine, School of Medicine, Kitasato University, 1-15-1 Kitasato, Sagami-hara, Kanagawa-ken 228, Japan.

Received September 4, 1985; accepted November 22, 1985.

woke unable to walk without falling and there was severe clumsiness of the left arm.

On examination she was alert, oriented, with intact recent and remote memory, and was not aphasic. Her blood pressure was 166/92 mmHg, and the pulse was 76/min and regular. She was moderately dysarthric with mild weakness of the left lower portion of the face. The tongue became deviated to the left on protrusion. The left arm and leg showed weakness which was maximal in the left foot. Tendon reflexes on the left were hyperactive with a Babinski sign present on the left. Sensation was intact to pin, touch, joint-position, and vibration. Muscle tone was decreased in the left arm and leg, and finger-nose and heel-knee-shin tests revealed marked dysmetria on the left side which far exceeded any ataxia attributable to the weakness. There was exaggerated rebound of the left limbs. The patient was unable to stand without assistance as she would stagger to the left.

Weakness and ataxia progressed for the next two days, but after the third day improvement began. A week later there was only mild weakness of her left toe and ankle, but dysarthria with left sided ataxia and dysmetria persisted. At the end of the fourth week of illness, speech was normal and ataxia of left upper and lower extremities was moderate and the patient was able to ambulate with a walking cane.

CT Scans

Using the GE model 8800, CT scans were performed on three occasions during the course of the illness. The first two scans were made on admission and on the ninth hospital day. They were both negative including iodine contrast studies. The CT scan, three months after onset, revealed a clear-cut low density lesion, consistent with a small infarct, in the paramedian portion of the right upper basis pontis (fig. 1).

Regional Cerebral Blood Flow Studies

Regional cerebral blood flow was measured on the ninth hospital day utilizing single-photon emission

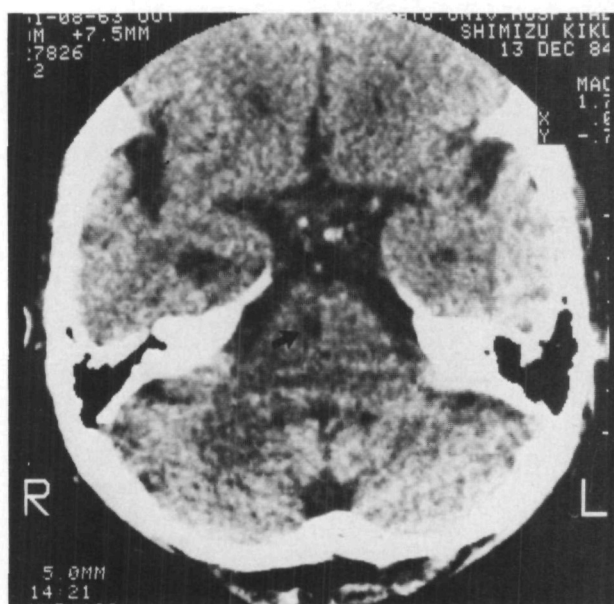


FIGURE 1. CT scan, three months after onset of left-sided ataxic hemiparesis, shows a low density area in the paramedian portion of the right upper pontine basis (arrow). CT scans during the acute stage were negative.

computed tomography (GE Maxi 400T) after the intravenous injection of 3 mCi of N-isopropyl-p-[¹²³I]Iodoamphetamine.¹⁰ Cerebral blood flow (CBF) was normal in supratentorial regions without any hemispheric asymmetries (fig. 2A), however CBF to the left cerebellar cortex was markedly reduced (fig. 2B). The reduction of mean left cerebellar blood flow was by 21.0% compared to the CBF of the right cerebellum calculated from a tomographic slice 1.2cm thick and 2cm above the Reid's base line. The normal range of asymmetries in cerebellar hemispheric CBF measured in 7 neurologically normal subjects is $5.4 \pm 3.2\%$ in our laboratory, and the hemispheric difference measured in this patient was considered abnormal.

Discussion

Neurological signs of this case consisted of mild hemiparesis with a Babinski sign on the left, with marked ataxia and dysmetria of the same side, combined with dysarthria. This combination of clinical signs meet the criteria for ataxic hemiparesis as described by Fisher in 1978.¹ CT scans in our patient showed a small low density lesion compatible with a lacunar infarct in the paramedian portion of the upper basis pontis. The unique feature of this case is that the diagnosis of ataxic hemiparesis during the acute stage of illness was supplemented by measuring reductions of cerebellar blood flow on the side of the clinically suspected cerebellar ataxia. The cerebellar hemispheric asymmetry of CBF in this patient far exceeded the normal range of asymmetry and the reduction seemed more marked in the cortical regions of the cerebellum. This reduction in CBF could well be attributed to reductions of cerebellar metabolism following the damage to the corticoponto-cerebellar pathway before it crosses at the level of the basis pontis. To the best of our knowledge, this is the first reported case in which the three-dimensional functional neuroimaging techniques provide objective proof for involvement of the cerebro-cerebellar system in ataxic hemiparesis. The present case provides both anatomical and pathophysiological support for Fisher's concept of the pathogenesis of ataxic hemiparesis.

Fisher¹ commented that the responsible lesion for the syndrome is in the basis pontis at the level of the junction of the upper one third and lower two thirds of the side opposite to the neurological deficits. The contralateral cerebellar signs are caused by damage to the pontine pathways relaying to the opposite cerebellar hemisphere. In spite of this rather clear-cut pathological explanation of the syndrome, subsequent authors' reports seem to have confused the issue by presenting various combinations of ipsilateral weakness and ataxia seen in patients with CT lesions at a variety of different locations outside the basis pontis, such as the internal capsule, corona radiata and midbrain. They indicated that each of these CT lesions may well be

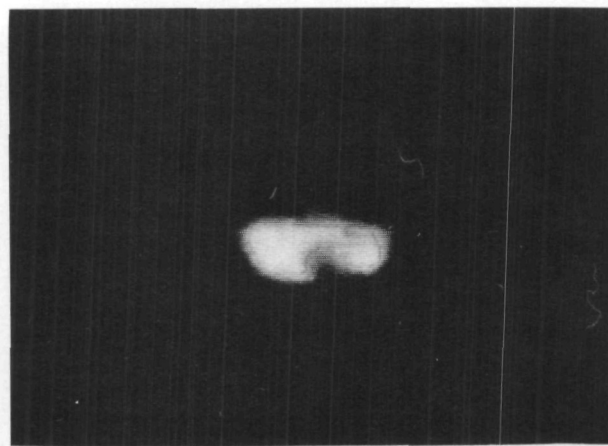
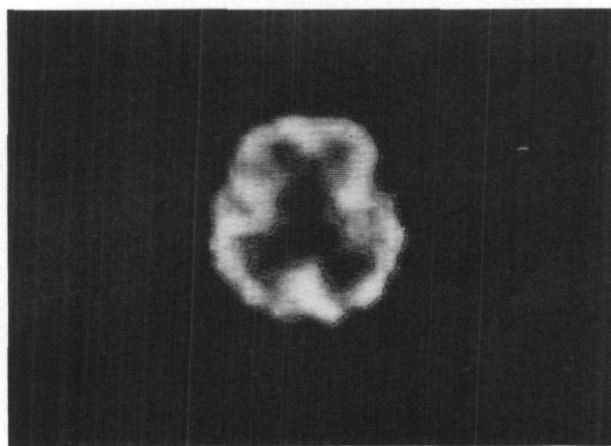


FIGURE 2. Cerebral blood flow, measured nine days after onset, was normal in the supratentorial regions (A) but markedly reduced in the left cerebellar cortical region (B). High blood flow is shown with an increase in lightness.

interpreted as a landmark to define complex anatomical pathways of the cerebrocerebellar system.^{8,9} However, this designation of various CT lesions as the locations interrupting cortico-cerebellar pathways should be interpreted with caution. It is difficult to determine whether ataxia or dysmetria are actually cerebellar in type when ipsilateral hemiparesis is also present. Neither specific clinical criteria nor established laboratory tests are available for diagnosing cerebellar deficits. It is difficult with currently available knowledge to estimate whether clinically suspected cerebellar symptomatology may be caused by infarcts in such areas as internal capsule or corona radiata. In spite of a number of anatomical and physiological studies in animals and humans concerning the cerebrocerebellar communication system,¹¹⁻¹³ present knowledge of the location of pathways for cortico-ponto-cerebellar and cerebello-thalamo-cortical projections in humans is not yet established to confirm our clinical interpretation of patients with the syndrome of ataxic hemiparesis.

With the advent of positron or single-photon emission computed tomography, we are now able to define regional cerebral function by mapping in three-dimensions regional cerebral blood flow and metabolism. These methods provide important insights to clarify such clinical controversies as the nature of ataxic hemiparesis and should contribute to improved understanding of cerebro-cerebellar connections. Recent reports on crossed cerebellar diaschisis by positron emission computed tomography¹⁴⁻¹⁶ have provided additional information, but functional knowledge accumulated to date on cortico-cerebellar pathways are incomplete and controversial. There has been no report of measurements of crossed cerebellar diaschisis in patients with the clinical syndrome of ataxic hemiparesis from supratentorial lesions. Damage to the cortico-pontine system at the level of the internal capsule or corona radiata has been posed as a cause of ataxic hemiparesis, but this must be confirmed by measuring reductions of cerebellar blood flow or metabolism in well described clinical cases with the syndrome. If, on the other hand, efferent cerebellar pathways are involved, CBF reductions reflecting these functional changes should be seen in the ventral thalamus and possibly cortical projections. Accumulation of data may be necessary to settle the issue of the localization in ataxic hemiparesis.

The present report emphasizes functional neuroimaging methods which add further clinico-pathophysiological correlations to the conventional clinical and pathological observations.

Acknowledgments

Drs K. Ishii and K. Nakazawa provided assistance in the measurements of cerebral blood flow. Prof. J.S. Meyer, Director CBF Laboratory VA Medical Center and Baylor College of Medicine (Houston, Tx, U.S.A.), assisted in preparing the manuscript.

References

1. Fisher CM: Ataxic hemiparesis: a pathologic study. *Arch Neurol* **35**: 126-128, 1978
2. Fisher CM, Cole M: Homolateral ataxia and crural paresis: a vascular syndrome. *J Neurol Neurosurg Psychiat* **28**: 48-55, 1965
3. Sakai T, Murakami S, Ito K: Ataxic hemiparesis with trigeminal weakness. *Neurology(Ny)* **31**: 635-636, 1981
4. Ichikawa K, Tsutsumishita A, Fujioka A: Capsular ataxic hemiparesis: a case report. *Arch Neurol* **39**: 585-586, 1982
5. Iragui VJ, McCutchen CB: Capsular ataxic hemiparesis. *Arch Neurol* **39**: 528-529, 1982
6. Sage JI, Lepore FE: Ataxic hemiparesis from lesions of the corona radiata. *Arch Neurol* **40**: 449-450, 1983
7. Bendheim PE, Berg BO: Ataxic hemiparesis from a midbrain mass. *Ann Neurol* **9**: 405-407, 1981
8. Huang CY, Lui FS: Ataxic-hemiparesis, localization and clinical features. *Stroke* **15**: 363-366, 1984
9. Mori E, Yamadori A, Kudo Y, Tabuchi M: Ataxic hemiparesis from small capsular hemorrhage: computed tomography and somatosensory evoked potentials. *Arch Neurol* **41**: 1050-1053, 1984
10. Kuhl DE, Barrio JR, Huang SC, Selin C, Ackermann RF, Lear JL, Wu JL, Lin TH, Phelps ME: Quantifying local cerebral blood flow by N-isopropyl-p-[123 I]iodoamphetamine: (IMP) Tomography. *J Nucl Med* **23**: 196-203, 1982
11. Everts EV, Thach WT: Motor mechanisms of the CNS: Cerebro-cerebellar interrelations. *Ann Rev Physiol* **31**: 451-498, 1969
12. Allen GI, Tsukahara N: Cerebrocerebellar communication systems. *Physiol Rev* **54**: 957-1006, 1974
13. Brodal P: The corticopontine projection in the rhesus monkey: origin and principles of organization. *Brain* **101**: 251-283, 1978
14. Baron JC, Bousser MG, Comar D, Duquesnoy N, Sastre J, Castaigne P: "Crossed cerebellar diaschisis": a remote functional depression secondary to supratentorial infarction of man. *J Cerebral Blood Flow Metab* (suppl 1): S500-501, 1981
15. Kushner M, Alavi A, Reivich M, Dann R, Burke A, Robinson G: Contralateral cerebellar hypometabolism following cerebral insult: a positron emission tomographic study. *Ann Neurol* **15**: 425-434, 1984
16. Martin WRW, Raichle ME: Cerebellar blood flow and metabolism in cerebral hemisphere infarction. *Ann Neurol* **14**: 168-176, 1983

Ataxic hemiparesis with reductions of ipsilateral cerebellar blood flow.

F Sakai, S Aoki, S Kan, H Igarashi, T Kanda and Y Tazaki

Stroke. 1986;17:1016-1018

doi: 10.1161/01.STR.17.5.1016

Stroke is published by the American Heart Association, 7272 Greenville Avenue, Dallas, TX 75231

Copyright © 1986 American Heart Association, Inc. All rights reserved.

Print ISSN: 0039-2499. Online ISSN: 1524-4628

The online version of this article, along with updated information and services, is located on the
World Wide Web at:

<http://stroke.ahajournals.org/content/17/5/1016>

Permissions: Requests for permissions to reproduce figures, tables, or portions of articles originally published in *Stroke* can be obtained via RightsLink, a service of the Copyright Clearance Center, not the Editorial Office. Once the online version of the published article for which permission is being requested is located, click Request Permissions in the middle column of the Web page under Services. Further information about this process is available in the [Permissions and Rights Question and Answer](#) document.

Reprints: Information about reprints can be found online at:
<http://www.lww.com/reprints>

Subscriptions: Information about subscribing to *Stroke* is online at:
<http://stroke.ahajournals.org/subscriptions/>