

Fulminant Reversible Cerebral Vasoconstriction Syndrome in Breakthrough COVID 19 Infection

Somdatata Ray, DM,^a Vikram V. Kamath, DM,^a Arjun Raju P, MD,^b
Rajesh KN, DM,^a and Shalini N, DA^c

COVID 19 infection continues to afflict people worldwide. Neurological complications of COVID infection are common. We report a case of fulminant reversible cerebrovascular constriction syndrome (RCVS) in a patient with breakthrough COVID 19 infection who was fully vaccinated. A 64 year old lady, fully vaccinated 2 months back, presented with headache, drowsiness, partial seizures, visual impairment and quadriplegia. Her nasopharyngeal swab was tested positive for SARS COV2 on real time PCR assay. MRI brain FLAIR images showed multifocal hyperintensities with MR angiogram showing arterial vasoconstriction suggestive of RCVS. Despite initiation of nimodipine, patient's symptoms worsened and she succumbed to sepsis. RCVS following COVID infection has been reported to have a benign outcome. However, despite vaccination, fulminant RCVS following a breakthrough COVID infection was observed in our patient.

Key Words: Fulminant—RCVS—Post vaccination—COVID 19—Breakthrough infection

© 2021 Elsevier Inc. All rights reserved.

Introduction

Following the first infection in Wuhan province in China in December 2019, 18 months later, COVID 19 infection continues to leave a catastrophic trail worldwide at an inexorable rate. Neurological complications in COVID infection have been attributed either to direct effect SARS CoV-2 virus or via an immune mediated impact post- infection.¹

Reversible cerebral vasoconstriction syndrome (RCVS) in the setting of COVID 19 infection has been rarely described.^{2,3} We report a case of fulminant RCVS in a patient

with breakthrough COVID 19 infection who was fully vaccinated.

Case report

A 64 year old lady with long standing history of migraine and recently diagnosed hypertension on amlodipine, presented with history of continuous excruciating headache and vomiting of 10 days duration. Five days after onset of headache, she developed drowsiness and difficulty in walking. She had received two doses of COVISHIELD (AstraZeneca, ChAdOx1) vaccine, 2 months back. Patient presented to the hospital casualty in a bed-bound state. On examination, patient was conscious and oriented, had elevated blood pressure (136/84-150/106) and significant vision impairment in both eyes with normal pupillary reflexes, quadriplegia and recurring focal seizures involving right upper limb.

MRI done 3 days prior to admission showed few discrete T2/ FLAIR white matter hyperintensities in bilateral centrum semiovale but no evidence of blooming or diffusion restriction. Her nasopharyngeal swab was tested positive for SARS COV2 on real time PCR assay. In view of

From the ^aDepartment of Neurology, Trustwell Hospital, Bangalore, Karnataka, India; ^bDepartment of Imaging, Trustwell Hospital, Bangalore, Karnataka, India; and ^cDepartment of Anaesthesia, Trustwell Hospital, Bangalore, Karnataka, India.

Received October 11, 2021; revision received November 17, 2021; accepted November 20, 2021.

Corresponding author at: Department of Neurology, Trustwell Hospital, J.c Road, Bengaluru-560002, Karnataka, India. E-mail: somray227@gmail.com.

1052-3057/\$ - see front matter

© 2021 Elsevier Inc. All rights reserved.

<https://doi.org/10.1016/j.jstrokecerebrovasdis.2021.106238>

quadriplegia, MRI brain was repeated that revealed bilateral cortical and subcortical frontal, parietal and occipital cortical white matter hyperintensities with hemorrhages and diffusion restriction, findings consistent with Posterior Reversible Encephalopathy Syndrome (PRES) (Fig. 1). MR angiogram showed widespread vasoconstriction of intracranial blood vessels suggestive of Reversible Cerebral Vasoconstriction Syndrome (RCVS).

CSF analysis was normal. Although patient was diagnosed with COVID 19, patient did not complain of cough, breathlessness or fever. Oxygen saturation in room air was 92% and CT chest showed mild basal ground glass opacities. Hence, no steroids were administered and patient was started on low molecular weight heparin in view of high D dimer levels and given oxygen supplementation as treatment for COVID infection. Patient was also initiated on oral nimodipine 60 mg Q4 hours and telmisartan and intravenous levetiracetam and admitted to intensive care unit. She went on to develop status epilepticus that was controlled with a combination of antiepileptics (levetiracetam, clobazam and valproate). Patient's sensorium deteriorated further. Repeat MRI brain showed increase in size of lesions with hemorrhagic transformation and significant edema. The MRI intracranial angiogram revealed persisting vasospasm in all vessels. Patient succumbed to aspiration pneumonia and sepsis ten days after admission.

Discussion

RCVS is considered as a monophasic illness and is traditionally associated with a benign prognosis with 90-

95% of the patients demonstrating near complete recovery within weeks and mortality has been seldom reported.⁴ A fulminant course of RCVS has been reported in 5-10% of the patients.⁵ In one study describing a cohort of 191 patients with RCVS, 3 patients died following progression of RCVS.⁶

The pathophysiology of RCVS in COVID is probably due to effect of SARS COV2 mediated downregulation of ACE receptors. The downregulation of ACE-2 receptors by SARS COV2 leads to sympathetic and/or renin angiotensin overactivity leading to vasoconstriction⁷ triggering blood pressure spikes that subsequently impairs cerebral autoregulation³

RCVS in the background of COVID infection has responded favourably to nimodipine and aspirin.² However, fulminant RCVS shows poor response to nimodipine.⁸ Fulminant RCVS has not been previously published in the setting of COVID-19 infection. This patient developed RCVS after developing COVID following completion of vaccination. Breakthrough infection following Covid vaccination have been associated rarely with severe symptoms requiring hospitalisation with most of the patients developing asymptomatic or mild illness.⁹ This patient presented with symptoms during the surge of second wave wherein the infections were predominantly mediated by the delta variant.¹⁰ The delta variant has been associated with higher likelihood of hospitalisation¹¹ although vaccination (both COVISHIELD and COVAXIN) has been effective in decreasing the disease mortality and morbidity in delta variant breakthrough infections.¹⁰ Despite vaccination, severe

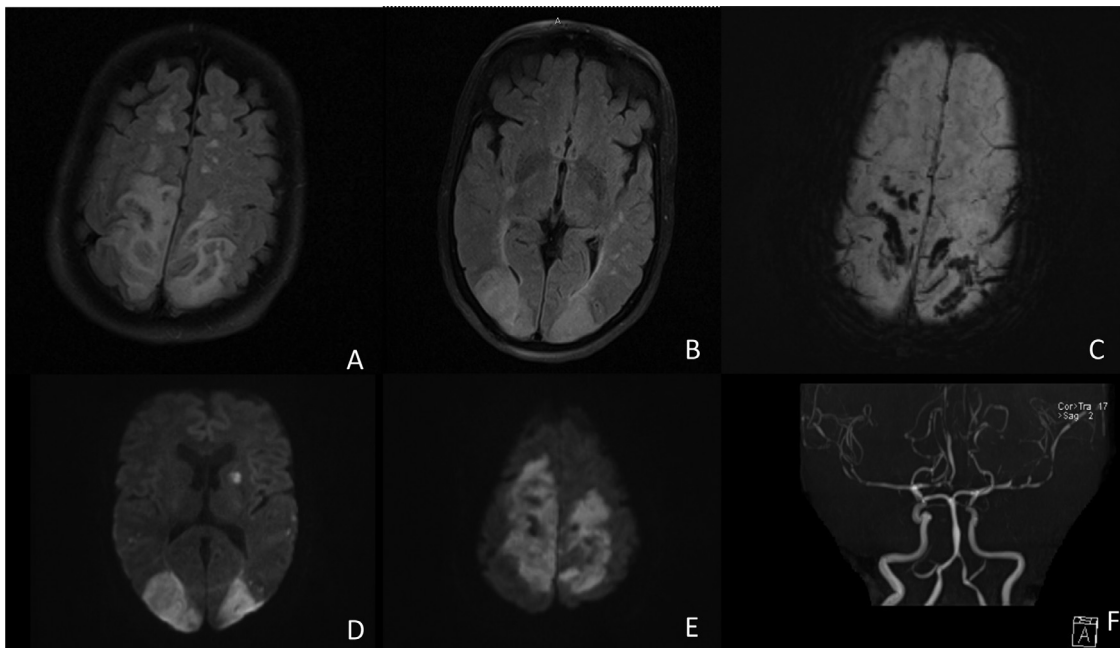


Fig. 1. MRI brain (A) and (B) FLAIR sequences show grey and white matter hyperintensities in parieto occipital, fronto parietal region. (C) Susceptibility weighted image sequence shows haemorrhagic transformation of the lesions. (D) and (E) Diffusion weighted image sequences show diffusion restriction of bilateral occipital, fronto parietal and left capsuloganglionic region. (F) Intracranial MR angiogram shows widespread arterial vasoconstriction.

complications in breakthrough COVID infection such as fulminant RCVS in our patient, are prevalent. Further reports from larger cohorts providing pathological insights will be required to strengthen the association between COVID infection and RCVS and confirm the hypothesis of COVID infection as a definite cause of RCVS in these patients.

Compliance with ethical standards

Informed consent has been taken from the patient's relative.

Declaration of Competing Interest

None of the authors have any financial disclosure to make or have any conflict of interest.

References

1. Ellul MA, Benjamin L, Singh B, Lant S, Michael BD, Easton A, Kneen R, Defres S, Sejvar J, Solomon T. Neurological associations of COVID-19. *Lancet Neurol* 2020.
2. Mansoor T, Alsarah AA, Mousavi H, Eliyas JK, Girotra T, Hussein O. COVID-19 associated reversible cerebral vasoconstriction syndrome successfully treated with nimodipine and aspirin. *J Stroke Cerebrovasc Dis* 2021;30(7):105822.
3. Dakay K, Kaur G, Gulko E, Santarelli J, Bowers C, Mayer SA, Gandhi CD, Al-Mufti F. Reversible cerebral vasoconstriction syndrome and dissection in the setting of COVID-19 infection. *JStroke Cerebrovasc. Dis.* 2020;29(9):105011.
4. Singhal AB, Hajj-Ali RA, Topcuoglu MA, Fok J, Bena J, Yang D, Calabrese LH. Reversible cerebral vasoconstriction syndromes: analysis of 139 cases. *Arch Neurol* 2011;68(8):1005-1012.
5. Miller TR, Shivashankar R, Mossa-Basha M, Gandhi D. Reversible cerebral vasoconstriction syndrome, part 1: epidemiology, pathogenesis, and clinical course. *Am J Neuroradiol* 2015;36(8):1392-1399.
6. John S, Singhal AB, Calabrese L, Uchino K, Hammad T, Tepper S, Stillman M, Mills B, Thankachan T, Hajj-Ali RA. Long-term outcomes after reversible cerebral vasoconstriction syndrome. *Cephalalgia* 2016;36(4):387-394.
7. Vieira C, Nery L, Martins L. Downregulation of membrane-bound angiotensin converting enzyme 2 (ACE2) receptor has a pivotal role in COVID-19 immunopathology. *Curr Drug Targets* 2020. Oct 20.
8. Breville G, Bailly A, Fisch L, Kulcsar Z, Pugin D, Carrera E. Case report and review of the literature: fatal reversible cerebral vasoconstriction syndrome. *Front Neurol* 2021 Feb 15;12:81.
9. Tyagi K, Ghosh A, Nair D, Dutta K, Bhandari PS, Ansari IA, Misra A. Breakthrough COVID19 infections after vaccinations in healthcare and other workers in a chronic care medical facility in New Delhi, India. *Diabetes Metab Syndr* 2021;15(3):1007-1008.
10. Sowpati DT, Munigela A, Banu S, Siva AB, Sasikala M, Nutalapati C, Kulkarni A, Mukherjee P, Zaveri L, COVID C, Tallapaka KB. clinical outcomes in vaccinated individuals hospitalized with Delta variant of SARS-CoV-2. *medRxiv* 2021.
11. Sheikh A, McMenamin J, Taylor B, Robertson C. SARS-CoV-2 Delta VOC in Scotland: demographics, risk of hospital admission, and vaccine effectiveness. *Lancet North Am Ed* 2021.