

Functional brain imaging with I123-amphetamine. First experience in the Netherlands

Collaborative study I123-IMP working group:

J.F. de Bruïne, E.A. van Royen, F. van Weeren, F.A. v.d. Weel, S. Reiffers, B.W.J. Verbeeten jr, H. Krens, A. Hijdra, and M. Limburg

Introduction

Brain scintigraphy has declined considerably after the introduction of computed tomography. The scintigraphic images cannot compete with the high resolution images of anatomic brain structures provided by CT scans.

In ischemic brain disease both CT and Tc99m pertechnetate brain scintigraphy do not visualize infarcted tissue in the first days after its onset since both the contrast medium used for CT and Tc99m pertechnetate do not pass the intact blood brain barrier. Nuclear medicine, as an essentially functional technique is able to provide information on regional cerebral blood flow (rCBF). In the past rCBF has been investigated with Xe133, which only records CBF in superficial cortical tissue, and in more recent years with Positron Emission Tomography (PET) and Single Photon Emission Computed Tomography (SPECT). The latter may find much more clinical application than the PET technique which is mainly confined to a few research centres. The SPECT technique employs widely available rotating gamma cameras and conventional radionuclides, instead of positron emitting nuclides which require cyclotron facilities on site. Tomographic imaging of rCBF with SPECT requires highly lipophilic radiopharmaceuticals which pass the intact blood brain barrier. Lipophilicity of a

Summary

Single Photon Emission Computed Tomography (SPECT) has been used in the last five years as a method for cerebral bloodflow imaging, especially in cerebral infarction. In this study the first experiences in the Netherlands are presented. In 57.6% of our patients lesions, defined by SPECT were larger than those found by CT. This was not only seen in patients with cerebral infarction but also in hematoma. In 33.3% the size of the lesions were comparable. In 10 out of 14 patients with a solitary lesion in one hemisphere a decreased perfusion was seen in the contralateral cerebellar hemisphere. This phenomenon is called crossed cerebellar diaschisis. One patient with probably Alzheimer disease, showing a specific flowpattern, is discussed.

Key words: SPECT, CT, cerebral infarction

pharmakon and its clearance by the brain as a consequence is represented by a high octanol/water partition coefficient. A high octanol/water partition coefficient results in an almost 100% clearance of the agent after a single circulatory brain passage, which is obligatory in the measurement of rCBF. Thereafter a stable level of brain retention should occur for at least about 30 min, in order to obtain SPECT images. After i.v. injection, the ideal radiopharmakon

Academic Medical Center, Amsterdam; Hospital 'De Stadsmaten', Enschede; Hospital 'De Weezenlanden', Zwolle; Hospital 'Het Nieuwe Spitaal', Warnsfeld; Cygne, Technische Hogeschool, Eindhoven.

Address for correspondence and reprint requests: E.A. van Royen, Department of Nuclear Medicine, Academisch Medisch Centrum, Meibergdreef 9, 1105 AZ Amsterdam.

Accepted 9.9.86

Clin Neurol Neurosurg 1986. Vol. 88-4

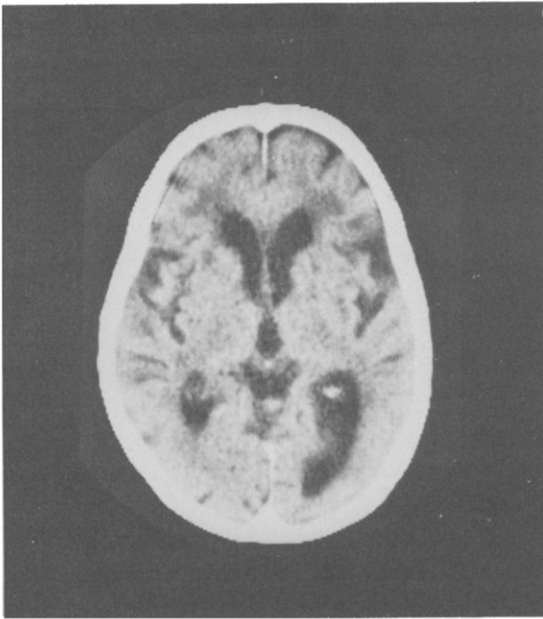


Fig. 1a

Fig. 1: Transversal CT (a) and SPECT (b) slice. CT shows cortical atrophy and slightly enlarged ventricles. The asymmetry of the occipital horns is also seen on the SPECT image.

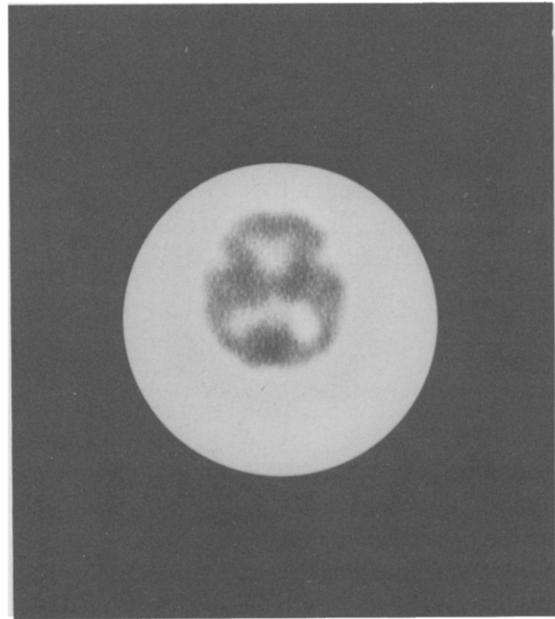


Fig. 1b

for rCBF imaging must distribute instantaneously to the various brain structures and stick there like microspheres injected into the carotid arteries, resulting in a 'frozen image' of rCBF at the time of injection.

Winchell developed N-isopropyl-123I-P-Iodoamphetamine (123I-IMP)^{1,2}, which is highly lipophilic and has a high extraction rate in the first pass. I123-IMP shows also a constant brain activity between 20 and 60 min. after intravenous injection³. It has been stated therefore that I123-IMP images of the brain represent rCBF. Fig. 1a shows an example of a transversal slice with a CT image on the same level (Fig. 1b). In recent years several reports have appeared on I123-IMP SPECT studies of the brain in various disorders⁴⁻¹².

The present study reports on the first experiences with I123-IMP/SPECT brain imaging in the Netherlands.

Materials and Methods

In order to achieve greater uniformity between studies, the four participating institutes agreed upon a more or less standardized procedure.

In Table 1 the different gamma camera systems, computers and acquisition parameters are listed. All departments use a 360 degree acquisition and reconstruction employing filtered backprojection.

Patient studies

A total of 48 studies were performed, 24 patients were male and 24 female. 73% of the patients were between 50 and 80 years old. The various disorders of the patients are listed in Table 2. The largest group (36) consisted of patients with ischaemic cerebrovascular disease.

After a 30 min. rest with a low background level of noise and light, 3-5 mCi I123-IMP (Cygne, TH Eindhoven) was injected in the antecubital vein, while the patient was lying in supine position. After 15-30 minutes, acquisition of the SPECT images were started. In about one fifth of the studies, patients were given 10 mgr diazepam per os before the I123-IMP injection (Het Nieuwe Spitaal, Warnsveld). Every patient underwent also a CT study. In 44% both examinations were made within a period not exceeding 5 days. In 4 cases SPECT and CT were performed on the same day, while in 23 cases first the CT and in 21 cases first the SPECT study was done. In 12.5% (6 cases) the period between both studies exceeded 20 days, the

Table 1. Type of gamma camera's, computers and acquisition parameters used by the participating institutes.

METHODS AND MATERIALS	ZWOLLE	ENSCHEDÉ	AMSTERDAM	WARNSVELD
gamma camera	Gen.Electr. 400 T	Gen.Electr. 400 T	Technicare Omega 500	Technicare Omega 500
collimator	low energy parallelhole	low energy 30 slanthole	300 KeV parallelhole	300 KeV parallelhole
computer	Digital PD 11/34	Informatec 1502	Technicare MCS 560+AP	Technicare MCS 560+AP
total imaging time (min.)	30	37	27	30
slice thickness (pixel, mm)	(2, 12.6)	(1, 6.3)	(2, 11.2)	(2, 11.6)
filter type	modified Shepp-Logan	Parzen	Butterworth 0.35/4	Butterworth 0.35/4

maximum was 40 days. In 33.3% of the cases the period between the onset of the disease and the first study was less than one week. In 25% this period was between one and six weeks, while in 41.7% this period was more than six weeks.

CT and SPECT images were reviewed independently by experienced representatives of the radiology and nuclear medicine departments of the participating institutes. Number and size of the hypodense and in case of hemorrhagic area's the hyperdense areas on the CT were compared with number and size of the areas with diminished activity on SPECT. In SPECT studies of ischemic brain disease special attention was given to a reduced uptake in the contralateral cerebellar hemisphere, a phenomenon called crossed cerebellar diaschisis (CCD). This was only performed in patients with lesions confined to one hemisphere. This phenomenon has been described both in the SPECT literature⁸ as in the PET literature¹³ and is due to a diminished cerebellar bloodflow contralateral to the infarcted hemisphere.

Results

Forty-seven CT studies showed 64 hypodense or hyperdense areas, while 58 areas with diminished activity were recognized on the SPECT studies. Thirty-three of these areas were comparable regarding the localization (Table 3). The patient with the multiple metastasis was

Table 2. List of diagnosis of the examined patients.

Diagnosis	male	female	total
Cerebrovascular disease	(19)	(17)	(36)
- infarction M.C.A.	6	8	14
- infarction posterior watershed area	3	-	3
- multiple infarctions	5	7	12
- brain stem infarction	2	1	3
- TIA/RIND	3	-	3
- basilar insufficiency	-	1	1
Hematoma (without trauma)	1	1	2
Trauma	2	-	2
Epilepsy	1	2	3
Dementia	0	2	2
Migraine Accompanee	0	1	1
Metastasis	1	0	1
Unknown	0	1	1
Total	24	24	48

Table 3. Comparison of the hypo- and hyperdense areas on CT and the areas with diminished activity on SPECT.

hypo/hyperdense areas on CT	64
areas with diminished activity on SPECT	58
CT area < SPECT area	19 (57.6%)
CT area = SPECT area	11 (33.3%)
CT area > SPECT area	3 (9.1%)

one patient was excluded (multiple metastasis)

Table 4. Comparison of SPECT and CT area's subdivided in vascular regions.

Vascular area	hypo/hyperdense area (CT)	area diminish. act. (SPECT)	CT area < SPECT area	CT area = SPECT area	CT area > SPECT area
ant.cerebral artery	3	1	-	1	-
middle cerebr. artery					
- superficial	16	17	4	4	2
- deep	22	4	3	1	-
- combined	8	9	4	3	-
post.cerebral artery	2	3	1	1	-
ant.water-shed area	4	2	1	-	-
post.water-shed area (bilateral, no of patients)	8 (1)	22 (4)	6	1	1
brain stem	1	-	-	-	-

excluded (of the 5 rather small metastases on enhanced CT, only one with a large area of oedema was recognized on SPECT as a cold spot).

In 57.6% of the cases the SPECT showed a larger area of diminished uptake, in 33.3% both areas had an equal size, while in 9.1% the CT area was larger, when compared to the SPECT area.

The hypodense areas on CT and the areas with diminished activity on SPECT were classified according to the known vascular areas, the anterior (ACA), the middle (MCA) and the posterior cerebral artery (PCA).

The MCA area was subdivided in a superficial, deep and combined superficial and deep area. The watershed areas and the brain stem were classified separately. The results are given in Table 4.

Most striking was the lower sensitivity of the SPECT study in the deep areas. On the other hand SPECT revealed more lesions in the posterior watershed area. In general, if lesions corresponded, SPECT lesions were larger than those found by CT.

The occurrence of crossed cerebellar diaschisis (CCD) related to the diagnosis is

shown in Table 5. Fourteen cases with single lesions could be studied. In 10 patients a CCD was found, in 3 patients the activity in both cerebellar hemispheres was equal and in 1 case the ipsilateral cerebellar hemisphere showed a decrease in activity compared to the contralateral one.

Cerebrovascular disease

Thirty-six patients were suffering from cerebrovascular disease. Fourteen patients had a MCA infarction. In 7 cases the SPECT area was larger when compared to the CT area, while in 2 cases the SPECT and CT area were equal in size. In none of the cases the CT area appeared larger.

In two cases CT was positive while SPECT showed no abnormalities, while in one case SPECT showed an area with diminished activity, with a normal CT. In two cases both SPECT and CT were abnormal, but the areas were not comparable. Of the 14 patients with MCA infarction in 9 cases the cerebellum was included in the study. Seven SPECT studies showed a positive CCD, one cerebellum was normal and in one case the ipsilateral cerebellum showed a decrease in activity (Fig. 2a + b).

Table 5. The occurrence of crossed cerebellar diaschisis related to the diagnosis.

Diagnosis	CCD+	CCD-	diminished activity in ipsilateral cerebellar hemisphere	total
MCA infarct	7	1	1	9
post. watershed infarct	1	1	-	2
hematoma, parietal	2	-	-	2
hematoma, frontal	-	1	-	1
TOTAL	10	3	1	14

The patients with multiple lesions were excluded

Three patients had a posterior watershed area infarction. In all 3 cases the area on SPECT was larger. In two cases the cerebellum was included in the study of which one had a positive CCD. No patients were studied with a solitary infarction of the ACA, PCA or in the anterior watershed region.

Twelve patients were studied with *multiple infarctions*. CT showed 36 hypodense areas, while 19 cases with diminished activity were seen with SPECT. Of the 13 comparable areas 5 were larger on SPECT, 5 were equal in size and in 3 cases the CT lesion was larger.

Brain stem infarction was seen in 3 patients. Only one was positive on CT. In this patient the SPECT study showed an area of decreased activity

in the right MCA area. One of the other patients showed a decreased activity in both posterior watershed regions. In the third patient both SPECT and CT were normal. Two patients with *TIA's* were investigated. One patient had a lacunar infarction on CT in the basal ganglia of the left side, while SPECT showed a decrease in activity in the posterior watershed area on the right. The other patient had a decreased activity in the PCA region with a normal CT. One patient suffered from a RIND of the right MCA, SPECT was positive while CT revealed no abnormalities.

Basilar insufficiency was seen in one patient. CT was normal while SPECT showed an area of decreased activity in the left MCA region. CCD was present.

We studied two patients with a *spontaneous intracerebral* hematoma of which one was caused by a ruptured saccular aneurysma. In both cases the SPECT area with diminished activity, localized in the left parietal region, was

Fig. 2: Case 2; streaklike hypodense area on CT (a) in the parietal region, probably in the external capsula or claustrum (arrow). SPECT shows a very large area of decreased activity on the same side (b). CCD is clearly shown (arrowhead).

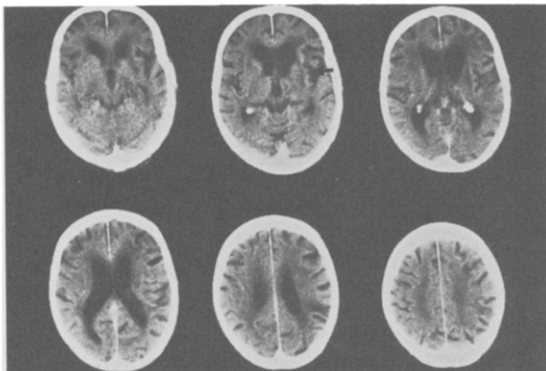


Fig. 2a

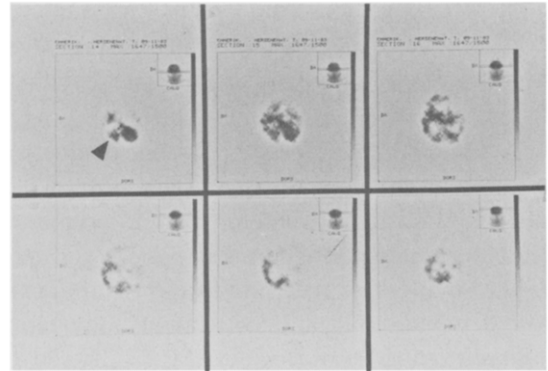


Fig. 2b

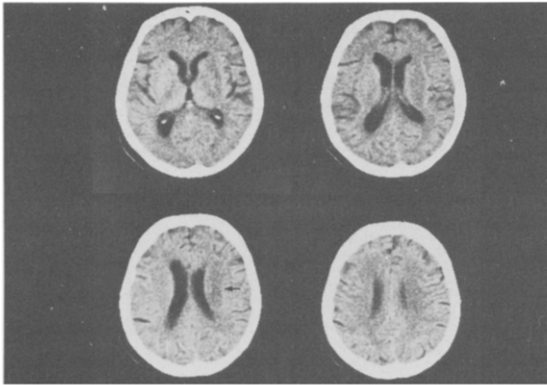


Fig. 3a

Fig. 3: Case 1; hypodense area in the right parietal region (a), SPECT (b) shows a much larger area of reduced uptake on the right side (arrows). CCD is present (arrowhead).

larger when compared to the hematoma on CT. A crossed cerebellar diaschisis was present in both cases.

Two *trauma* patients were examined. One patient had a left sided contusion on CT in the deep parietal region, SPECT showed a decrease in cortical activity uptake on the same side. The other trauma patient revealed a frontal hematoma with an equal sized area of reduced activity on SPECT. In this case no CCD was present.

Epilepsy. One patient was examined who underwent a craniotomy in 1962 for an arteriovenous malformation and presented recently with seizures. On CT hypodense areas were seen in the right sided MCA and PCA regions. These were equal in size when compared to the areas seen on the SPECT study.

Two other patients with seizures were examined. One had a normal CT and an area with decreased activity in the right MCA region on the SPECT study. The third patient showed no abnormal findings on CT or SPECT. All patients were examined at an interictal phase.

Two patients with *dementia* were studied. A 57-year-old female presented with progressing forgetfulness. A diagnosis of presenile dementia was made (Alzheimer disease). CT was normal. SPECT showed a bilateral parieto-occipital decrease in activity. The other patient was an 80-year-old female suffering from multi infarction dementia. On CT cortical atrophy and enlarged ventricles were seen. SPECT showed a

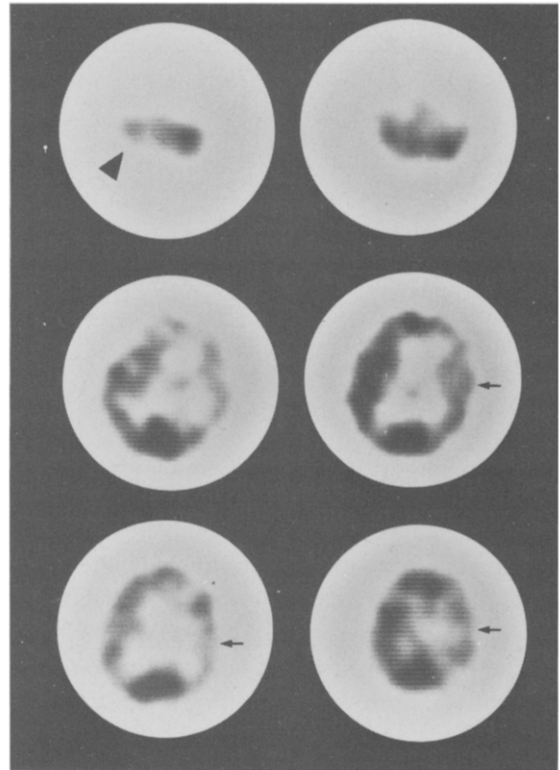


Fig. 3b

small rim of activity accumulation in the cortical areas.

One patient with *migraine* accompagnée was examined. Both CT and SPECT were normal. The patient was painfree during SPECT.

In one patient with doubtful neurological symptoms no diagnosis could be established. No focal abnormalities were found with CT or SPECT.

Case studies

Case 1. A 66-year-old female presented with an acute leftsided hemiparesis. CT was performed 13 days after onset and showed a small hypodense area on the right side deep parietal, with asymmetry of the ventricles due to compression. SPECT was performed the next day and revealed a large cortical area with diminished activity on the right side (Fig. 3a, b). The left cerebellar hemisphere showed diminished activity when compared to the right hemisphere (positive CCD).

Case 2. A 79-year-old male underwent both a CT and a SPECT study 3 months after the onset of a rightsided hemiparesis and aphasia. The CT

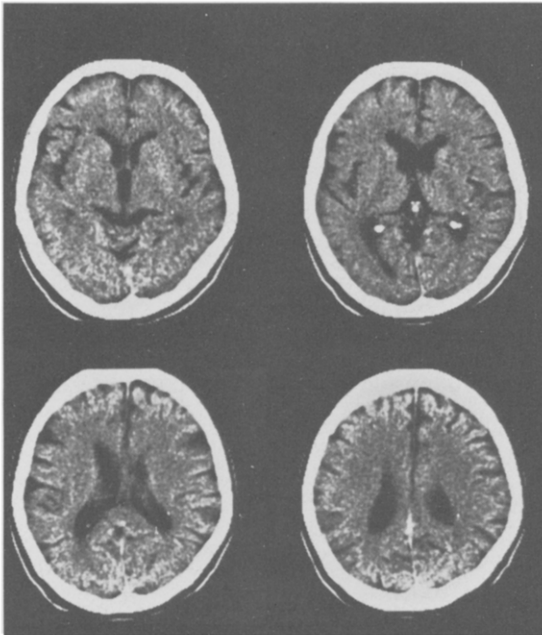


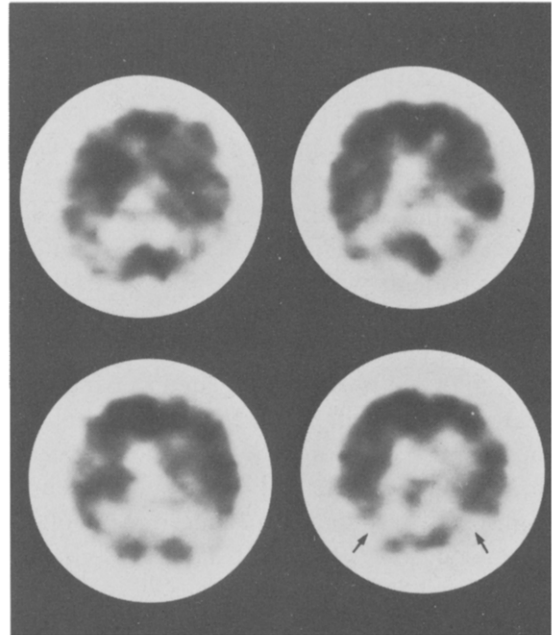
Fig. 4. Case 3; CT shows some cortical tissue loss (a), while SPECT reveals bilateral areas of reduced uptake in the parietooccipital regions suggesting Alzheimer's disease (b).

study showed loss of cortical tissue and enlarged ventricles (Fig. 2a, b). Hypodense areas were found surrounding the anterior horn of the lateral ventricles possibly representing leucoencephalomalacia. Another hypodense area was seen lateral of the left basal ganglia. The SPECT study revealed a large cortical lesion on the left side with diminished activity, which included most of the region. The CCD phenomenon was also positive in this patient.

Case 3. A 57-year-old female was admitted to the hospital suffering from a slowly progressive loss of memory. She could not manage daily housekeeping and did irresponsible purchases. Neurological examination revealed no abnormality. A diagnosis of probable Alzheimer disease was made. CT study showed some loss of cortical tissue without focal disorders (Fig 4a, b). On the SPECT study bilateral reduced activity was seen in the parietal region which did not correspond with any abnormality on the CT scan.

Discussion

I123-IMP is taken up by the brain tissue almost



completely during the first pass, whereafter it is retained for a period of 20-60 min. Therefore its distribution is highly flow dependent and when no further uptake or redistribution occurs, the injection represents the flow pattern at the time of injection. This resembles a 'frozen image' of cerebral bloodflow (CBF) obtained after the intracarotid injection of microspheres. Probably this hypothesis is only valid for I123-IMP uptake in normal brain tissue, since uptake and retention may be influenced by amine receptors, pH changes and metabolism⁶. Lee *et al*⁶ were unable to show focal hyperemia, 'luxurious perfusion', in any of their stroke patients. This may be due to alteration of the infarcted tissue, so that uptake and retention are diminished in spite of increased flow. Also in our study we did not observe luxurious perfusion. Another argument that retention of I123-IMP does not depend fully on CBF is posed by the decreased uptake of I123-IMP in brain tumours^{4,8,17}. In 57.6% of our patients lesions defined by SPECT were larger than those found by CT. This phenomenon was also reported by others^{3,6,9,10} and may be due to the 'penumbra' effect¹⁰.

In acute stroke CT shows often little or no abnormalities in the first days, while the perfusion defects, shown by I123-IMP can be demonstrated immediately after the onset.

The SPECT study proved to have a substan-

tially lower sensitivity for small and deeply localized lesions. While CT demonstrated 22 deep MCA lesions only 4 were found by SPECT, probably because of the low spatial resolution of the present rotating gamma cameras.

Crossed cerebellar diaschisis (CCD) proved to be a frequent finding. In 71.4% (10 out of 14) of our patients with solitary lesions CCD was present. This phenomenon was not confined to stroke patients but also observed in hematoma and tumors. It is probably related to a reduced neuronal activity in the cerebellum hemisphere caused by a deprivation of input of impulses from the contralateral infarcted cerebral hemisphere resulting in a reduced metabolism and blood flow¹³. Diaschisis has also been described in the contralateral hemisphere and the ipsilateral thalamus to a cortical infarction¹³.

The localization of epileptic foci registered by EEG, may be very difficult especially in case of deep lesions. CT is only helpful if morphologic changes are present. Localization of the focus may be of interest when stereotactic or surgical intervention is considered. If 123I-IMP is injected during a seizure, a SPECT study may be performed afterwards. Then the focus may still be present as an area of increased activity caused by the increased blood flow during the seizure^{6,9,18,19,20}. If the injection is administered during the postictal or interictal state, the focus may present as a cold area due to a decreased blood flow of the focus. We studied two patients in an interictal fase, with both normal CT's. One case showed an area of decreased activity on SPECT, which might represent the focus. The other patient showed no abnormalities on SPECT.

The differential diagnosis of dementia may be difficult, especially in the early phase. In non-vascular forms, employing SPECT a symmetrical decrease in cerebral blood flow in the temporo-parietal-occipital areas has been described^{20,21}, while in multi-infarction dementia SPECT may reveal discrete multiple asymmetrical gray matter defects. Decreased activity in the parieto-occipital areas was observed in case 3 suffering from Alzheimer disease. More experience has to be gathered before conclusions can be drawn as to the value of SPECT in the differential diagnosis of dementia.

In summary single photon emission computed tomography offers a complementary method when functional disorders, particularly concerning CBF, are present. In acute stroke SPECT may be the method of choice to monitor ischemia in intervention studies aimed to diminish the loss of neurons in the 'penumbra' area. When stereotactic or surgical intervention in patients with epilepsy is considered, the focus can be detected with SPECT when 123I-IMP is injected during the epileptic fit. Moreover SPECT may add considerably to the differential diagnosis of dementia.

References

- 1 WINCHELL HS, BALDWIN RM, LIN TH. Development of I-123-labeled amines for brain studies, localisation of I-123 Iodophenylalkylamines in rat brain. *J Nucl Med* 1980; 21:940-6.
- 2 WINCHELL HS, HORST WD, BRAUN L, OLDENDORF WH, HATTNER R and PONKER H. N-Isopropyl-[I-123]-P-iodoamphetamine: single pass brain uptake and washout, binding to brain synaptosomes, and localisation in dog and monkey brain. *J Nucl Med* 1980; 21:947-52.
- 3 HOLMAN BL, HILL TC, LEE RGL, ZIMMERMAN RE, MOORE SC, ROYAL HD. Brain imaging with radiolabeled amines. *Nucl Med Annual* 1983, Raven Press NY, p. 131.
- 4 LA FRANCE ND, WAGNER JR HN, WHITEHOUSE, P, CORLEY E, DUELFER T. Decreased accumulation of Isopropyl-Iodoamphetamine (I-123) in brain tumors. *J Nucl Med* 1981; 22:1081-3.
- 5 LEE RG, HILL TC, HOLMAN BL, UREN R, CLOUSE ME. Comparison of N-isopropyl (I123)-p-Iodoamphetamine brain scans using anger camera and single photon emission tomography. *Radiol* 1982; 145:789-93.
- 6 LEE RG, HILL TC, HOLMAN BL, CLOUSE ME. N-isopropyl (I123)-p-Iodoamphetamine brain scans with single photon emission tomography: discordance with transmission computed tomography. *Radiol* 1982; 145:795-9.
- 7 KUHL DE, BARRIO JR, HUANG SC, SELIN C, ACKERMAN RF, LEAR JL, WU JL, LIN TH, PHELPS ME. Quantifying local cerebral blood flow by N-isopropyl-(I123)-p-Iodoamphetamine (IMP) tomography. *J Nucl Med* 1982; 23:196-203.
- 8 MORETTI JL, ASKIENARRY S, RAYNAUD C, LASSEN N, SANABRIA E, SOUSSALINE F, BARDY A, LE POUCCIN-LAFITTE M, CARON JP, CHODKIEWICZ JP. N-isopropyl-I123-p-Iodoamphetamine: an agent for brain imaging with single photon emission computerized tomography: Functional radionuclide imaging of the brain edited by Philip Magistretti, Raven Press, NY 1983, 231-46.
- 9 ELL PJ, CULLUM I, DONAGHY M, LUI D, JARRIT PH, HARRISON MJG. Cerebral blood flow studies with Iodine-123 labeled amines. *The Lancet* 1983; I:1348-52.
- 10 HILL TC, MAGISTRETTI PL, HOLMAN BL, LEE RGL, O'LEARY DH, ZEN RF, ROYAL HD, MAGMAN CI, KOLODNY GM, CLOUSE ME. Assesment of regional cerebral blood flow (rCBF) in stroke using SPECT and N-isopropyl-(I-123)-p-iodoamphetamine (IMP). *Stroke* 1985; 15:40-5.

- ¹¹ LEE RGL, HILL TC, HOLMAN BL, ROYAL HD, O'LEARY DH, CLOUSE ME. Predictive value of perfusion defect size using N-isopropyl (I-123)-P-iodoamphetamine emission tomography in acute stroke. *J Neurosurg* 1984; 61:449-52.
- ¹² VON SCHULTHESS GK, KETZ E, SCHUBIGER PA, BEKIER A. Regional quantitative noninvasive assesment of cerebral perfusion and function with N-isopropyl (123I)-p-iodoamphetamine. *J Nucl Med* 1985; 26:9-16.
- ¹³ MARTIN WRW, RAICHLER ME. Cerebellar blood flow and metabolism in cerebral hemisphere infarction. *Ann Neurol* 1983; 14:168-76.
- ¹⁴ KUHL DE, PHELPS ME, KOWELL AP et al. Effects of stroke on local cerebral metabolisms and perfusion: mapping by emission computed tomography of 18 FDG and 13 NH3. *Ann Neurol* 1980; 8:47-60.
- ¹⁵ KUHL DE, WU JL, LIN TH et al. Mapping local cerebral blood flow by means of emission computed tomography of N-isopropyl-p-(123I)-Iodoamphetamine. *J Nucl Med* 1982; 22:16.
- ¹⁶ LASSEN NA, HENRIKSEN L, HOLM S, BARRY DI, PAULSON OB, VORSTRUP S, RAPIN JR, LE POUICIN-LAFITTE M, MORETTI JL. Cerebral bloodflow tomography Xenon-133 compared to isopropyl-amphetamine iodine 123. *J Nucl Med* 1982; 7:487-93.
- ¹⁷ GERHARDS W, BORNER W, EILLES C, REINERS C, BOMHARD G v. 123I-amphetamine in the diagnosis of cerebrovascular diseases and cerebral space-occupying lesions: 123I-amphetamine: proceeding of a colloquium held at Wurenlingen, Switzerland, oct. 28, 1983. Edt. [Roche], Basel, Switzerland.
- ¹⁸ MAGISRETTI PL, UREN RF, ROYAL HD, PARKER AJ, FROUT D, HOLODNY GM. N-Isopropyl-123-p-Iodoamphetamine imaging in epilepsy. *Functional radionuclide imaging of the brain*, ed. Philippe L. Magistretti, Raven Press, NY, 1983.
- ¹⁹ MAGISRETTI P, UREN R, SHOMEN D, BLUME H, HOLMAN B, HILL TC. Emission tomographic scans of cerebral blood flow using I123 Iodoamphetamine in epilepsy. *Proc. Third World Congress of Nucl. Medicine and Biology*. Pergamon Paris 139-43, 1982.
- ²⁰ DEVOUS SR MD, STROKELY EM, BOUTE FJ. Quantitative imaging of regional cerebral blood flow by dynamic single photon tomography. *Radionuclide imaging of the brain*. Ed. B. Leonard Holman, Churchill Livingstone 1985, 135.
- ²¹ COHEN MB, GRAHAM LS, LAKE R, METTER EJ, FITTEN J, KULKARNI MK, SEVRIN R, YAMADA L, CHANG CC, WOODRUFF N, and KLING AS. Diagnosis of Alzheimer's disease and multiple infarct dementia by tomographic imaging of Iodine-123 IMP. *J Nucl Med* 1986; 27:769-74.