

Unusual case of dolichomegavertebro-basilar anomaly. CT and angiographic picture.

Case report

L. Casentini**, D. Curri**, A. Benedetti**, P. Dettori*,
L. Bernardi*, A. Alexandre**

* Istituto di Neuradiologia, Ospedale Civile di Vicenza/Italy

** Divisione di Neurochirurgia, Ospedale Civile Vicenza/Italy

Summary

We recently observed a patient affected by DMVB anomaly, whose clinical and neuroradiological findings are quite unusual.

Ein ungewöhnlicher Fall einer dolichomegavertebrobasilären Anomalie und deren Darstellung im CT und Angiogramm – Fallbericht

Bericht über einen Patienten mit einer dolichomegavertebrobasilären Anomalie bei auffallend ungewöhnlichen klinischen und radiologischen Befunden.

Key-Words: vertebrobasilar anomaly – CT – angiography

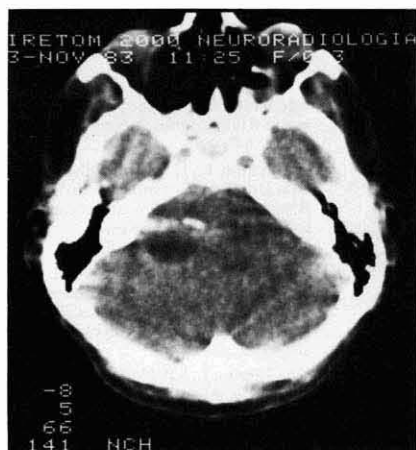

Fig. 1a

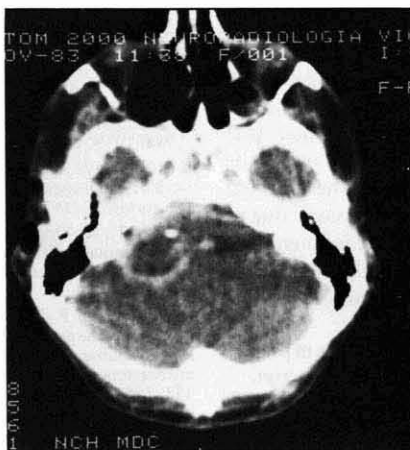

Fig. 1b

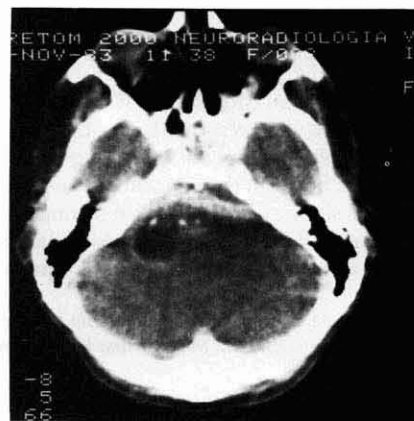


Fig. 1c

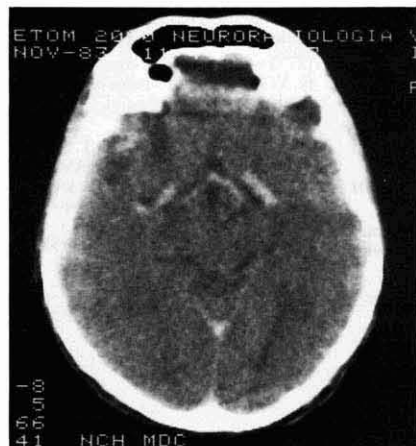

Fig. 1d

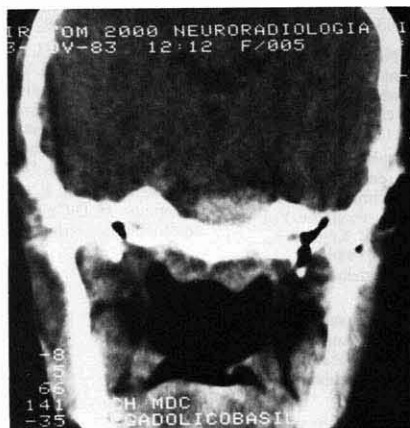


Fig. 1e

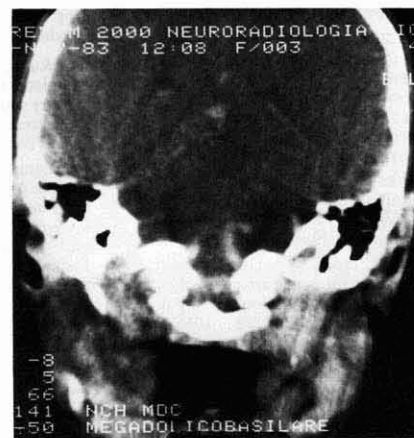


Fig. 1f

Fig. 1

a: Axial CT scan without contrast medium. In the region of the left cerebello-pontine angle a hypodense area with hyperdense borders and calcification is detectable.

b, c: Same scan after contrast medium. Enhancement of the borders and visualisation of the hyperdense median band with typical vascular appearance.

d: Note the ectatic carotid siphons.

e, f: Coronal views.

Since CT scan is a widely employed diagnostic measure, several cases of dolichomegavertebro-basilar (DMVB) anomaly have been reported, in which the diagnosis was possible with the aid of CT and was then confirmed by angiography (2, 4, 5, 6, 7). The CT picture is generally quite peculiar, as described by other authors (6).

Case report

A 32-year-old man presented a sudden left hemiparesis, dysphagia and speech disorders.

At the age of two he had been treated surgically for a congenital cleft of the soft palate; no dysphagia or speech disorders were noted thereafter. Two years before admission to our hospital, the patient experienced sudden paraesthesiae of right limbs with slight right dysmetria. In a few days the symptoms disappeared; cerebral scintigram was negative.

On admission the neurological examination revealed: paresis of the left limbs, left facial paresis with preservation of the muscles of the upper part of the face, marked dysphonia with absence of arching of the palate on the left side and paresis of the left hemilarynx, dysphagia, slight deviation of the tongue toward the left side, impairment of the strength

of the left sternomastoid and trapezius muscles. Left miosis without ptosis and enophthalmos with preservation of pupillary reaction to light were also noted.

Hearing loss, nystagmus, disorders of ocular movements and papilloedema were not detectable. Sensation was preserved.

Computed tomography without contrast medium showed a rounded area of low attenuation with hyperdense rim and calcification in the region of the left cerebello-pontine angle (Fig. 1a). No mass effect on the fourth ventricle nor dilatation of the ventricular system was detectable. Cavum Vergae was also present.

CT scan with bolus enhancement and coronal sections revealed a ring-like structure in the left-cerebello-pontine angle and a large, hyperdense band crossing the midline in the prepontine cisterns (Fig. 1b, c, e, f).

An enlargement of the carotid siphons was also present (Fig. 1d). Bilateral vertebral and carotid angiography were performed. The calibre of the four vessels was increased. The left and the right vertebral arteries were elongated and tortuous; both formed a large loop at the level of the left cerebello-pontine angle. The basilar artery was very ectatic and elongated; its proximal segment crossed the pons transversely from one side of the cerebello-pontine angle cisterns to the other (Fig. 2).

The cerebellar and posterior cerebral arteries, as well as intracranial branches of the carotid arteries, were dilatated and tortuous.

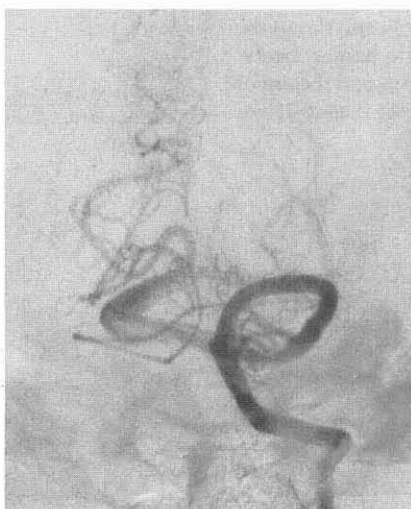

Fig. 2a

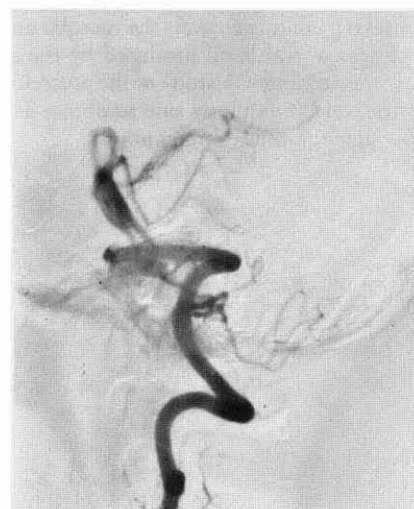

Fig. 2b

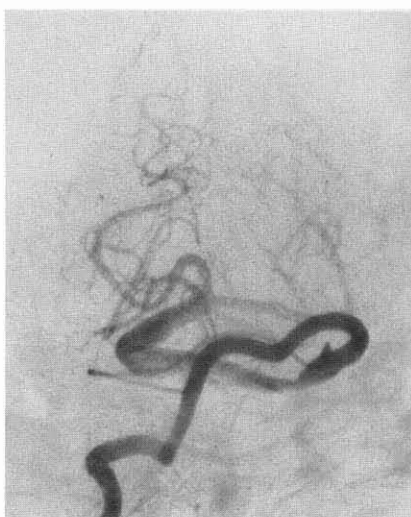


Fig. 2c

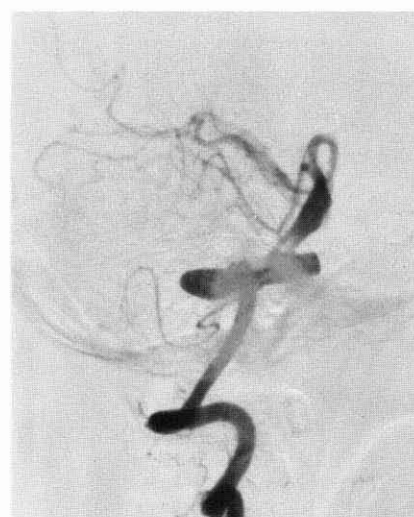

Fig. 2d

Fig. 2

a, b: Left vertebral angiography.

c, d: Right vertebral angiography.

Pictures clearly show the loop formed by the vertebral arteries in the left cerebello-pontine region and the ectatic basilar artery.

Discussion

In this case the symptoms are quite typical: in fact involvement of cranial nerves is associated with long tract signs (3, 5). The abrupt onset of the symptoms observed in our patient is probably due to sudden haemodynamic disturbances caused by the malformation. However several cases of the literature are characterised by a long clinical history (1, 2, 5, 7).

The young age and the absence of arterial hypertension, as well as the association of other malformation (cleft palate) or anomalies (cavum Vergae, bilateral megadolichocarotid system) are quite uncommon and suggest the existence of a complex dysplastic condition rather than an atheromatous aetiology suspected in the other cases previously reported (5).

From a radiological point of view, our case emphasises the importance of a correct CT scan evaluation: the entire posterior fossa must be carefully examined (6) and contrast medium must be given. In fact incomplete scanning of the posterior fossa allows one to detect only partially the complex malformation, leading to misdiagnosis. In our case CT scan before contrast medium displays a hypodense area surrounded by hyperdense borders with calcifications: this picture mimics a cystic tumour of the cerebello-pontine region. The hypodensity is probably caused by a dilated cistern in the cerebello-pontine angle.

Contrast medium enhances the vascular anomaly and shows the thick transversal band produced by the ectatic basilar artery. Only the accurate CT study of the posterior fossa and the use of contrast medium allows one to obtain a correct diagnosis without angiographic examinations.

We believe that in patients in whom a DMVB anomaly is suspected, digital venous angiography could be usefully and more safely performed to avoid the classical vertebral angiography (2): in fact the possibility of complications after vertebral angiography cannot be excluded in patients in whom haemodynamic alterations of cerebral circulation exist.

References

- (1) Azar-Kia, B., E. Palacios, M. Spak: The megadolichobasilar artery anomaly and expansion of the internal auditory meatus. *Neuroradiology* 11 (1976) 109–111
- (2) Corkill, G., M. Sarwar, C. Virapongse: Evolution of dolichoectasia of the vertebrobasilar system as evidenced by serial computed tomography. *Surg. Neurol.* 18 (1982) 262–266
- (3) Frasson, F., G. Ferrari, C. Fugazzola, A. Fiaschi: Megadolichobasilar anomaly causing brain stem syndrome. A case report. *Neuroradiology* 13 (1977) 279–281
- (4) Martelli, A., F. Rognone, G. Bono, L. Gozzoli, A. Cecchini, G. Nappi: Dolichomegavertebrobasilar anomaly: diagnosis by CT. *Acta Neurol. (Napoli)* 37 (1982) 62–67
- (5) Moseley, I. F., I. M. Holland: Ectasia of the basilar artery: the breadth of the clinical spectrum and the diagnostic value of computed tomography. *Neuroradiology* 18 (1979) 93–97
- (6) Peterson, N. T., P. M. Duchesneau, E. L. Westbrook, M. A. Weinstein: Basilar artery ectasia demonstrated by computed tomography. *Radiology* 122 (1977) 713–715
- (7) Scotti, G., C. De Grandi, A. Colombo: Ectasia of the intracranial arteries diagnosed by computed tomography. Megadolichobasilar artery: CT diagnosis. *Neuroradiology* 15 (1978) 183–184

L. Casentini
Divisione di Neurochirurgia
Ospedale Civile di Vicenza
Vicenza/Italy