

Regional Cerebral Glucose Metabolism in Aphemia: A Case Report

MICHAEL KUSHNER, MARTIN REIVICH, ABASS ALAVI, JOEL GREENBERG,
MATT STERN, AND ROBERT DANN

*Departments of Neurology and Radiology, Cerebrovascular Research Center, University
of Pennsylvania School of Medicine*

Local cerebral metabolism was determined in a patient suffering aphemia following cerebral infarction using the ^{18}F FDG-PET technique. The syndrome was characterized by profound ictal nonfluency with sparing of other language functions. Speech subsequently improved so that content and grammar were appropriate but mild dysprosody persisted. Conventional CT showed no lesion of the left hemisphere while PET revealed a discrete focus of hypometabolism on the left which partially resolved on serial studies. The metabolic lesion could be localized to the region of the inferior precentral gyrus and the adjacent subcortical space.

© 1987 Academic Press, Inc.

INTRODUCTION

Aphemia is a disturbance of speech in which vocalization alone is affected while writing and other language functions remain unimpaired (Bastien, 1898). This condition occurs infrequently and is found in about 1.0% of traumatic aphasia (Russell, 1962) and 1-2% of aphasias of ischemic origin (Basso, 1978; Benson, 1979). While the anatomic localization of this disorder is not known precisely, attention has been directed toward the periopercular region (Dejerine, 1914; Benson, 1979). Some authors have pointed to lesions of Broca's area as being responsible for aphemia (Dejerine, 1914; Ruff, 1981). Others have cited lesions of the primary motor cortex which spare Broca's area (Lecours, 1976). Uncertainty in the localization of this syndrome has arisen in part from both its rarity and its clinical benignity. These attributes have contributed to the dearth of postmortem or other structural data concerning aphemia.

Supported by USPHS Program Project Grant NS-14867-08. Dr. Kushner is the recipient of Clinical Investigator Development Award 1 K08 NS00999-02. Reprint requests should be addressed to Michael Kushner, M.D., Assistant Professor of Neurology, Cerebrovascular Research Center, Rm. 429, Johnson Pavilion, 36th and Hamilton Walk, Philadelphia, PA 19104.

and its clinical benignity. These attributes have contributed to the dearth of postmortem or other structural data concerning aphemia.

A recently developed technique employing position emission tomography (PET) and the tracer ^{18}F -FDG has provided a new approach with which to study the workings of the brain (Reivich, 1979). PET imaging yields *in vivo* three-dimensional representations of functional neural parameters. These data already have proven useful in the study of cerebral metabolism during normal physiological states (Greenberg, 1981; Phelps, 1981; Mazziotta, 1984). PET has documented disturbances of cerebral metabolism in some pathological states even when no corresponding structural abnormality could be demonstrated by CT or MRI (Kuhl, 1980; Kushner, 1984). This approach provides a novel means for clinical-anatomic correlation and cerebral localization. We have studied local cerebral glucose consumption using PET in a patient with aphemia of ischemic origin during the ictal and recovery phases. PET imaging revealed a discrete metabolic abnormality while conventional CT failed to disclose a corresponding structural lesion. This aphemic syndrome occurred in association with dysmetabolism in the region of the left primary motor cortex and the underlying subcortical space.

CASE REPORT

A 74-year-old right-handed man entered the hospital with several hours of "difficulty speaking." He was well that morning but later he experienced the abrupt onset of inability to speak in other than monosyllables. Family members reported no lack of comprehension, loss of consciousness, or motor disturbance. There was a 50 pack-year history of cigarette smoking but no history of hypertension, diabetes mellitus, cardiac disease, stroke, or TIA. He was a retired cook and had completed the seventh grade. The blood pressure was 150/90 mm Hg and the pulse was 74 and regular. The remainder of the general physical examination was normal.

Neurological examination showed a mild +4/5 right hemiparesis affecting face, arm, and leg equally. Gait was uneffected. The tendon reflexes were more prominent on the right; pathological reflexes were absent. Tests of sensation and cerebellar function were normal. Except for the mild right facial weakness the cranial nerve functions including phonation and other lingual and pharyngeal functions were normal. Ideomotor and buccolingual apraxia were absent. The "mini-mental state" score was 27 (Folstein, 1975).

In addition to routine bedside tests, higher cortical function and language ability was assessed by a formal battery. This included the Wechsler Adult Intelligence Scale (Matarazzo, 1972), Halstead-Reitan battery (Russell, 1970), and the Boston Diagnostic Aphasia Examination (BDAE) (Goodglass, 1972). Temporal orientation was normal. The digit span was five forward and three backward. Simple trail making was intact as was

visual reproduction. The patient's arthric disorder precluded use of the Wechsler Memory Scale and some other test elements. He could remember two of three objects at 5 min consistently. The BDAE rating scale profile was consistent with profound nonfluency. Verbal and reading comprehensions were intact. Confrontation object identification was normal. Spontaneous writing, copying, and dictation produced script of normal morphology and content. Spelling and grammar were correct. The speech output was slow, hesitant, labored, and "breathy." It consisted mostly of monosyllables and infrequent word pairs. Literal paraphasias were present about 40% of the time. Neologistic distortions and verbal paraphasias were absent. Repetition was impaired in a similar fashion. Reading aloud and reciting automatic sequences resulted in fewer paraphasic errors but profound nonfluency persisted. He frequently self-corrected and he became frustrated easily.

Normal laboratory tests included complete blood count, liver function tests, serum electrolytes, blood glucose, electrocardiogram, chest radiograph, and erythrocyte sedimentation rate. CT without and with contrast was performed the day following the ictus (Fig. 1). No abnormality was noted in the left hemisphere. A circumscribed wedge-shaped lucency was present in the right midparietal region. This lesion did not enhance following contrast administration and was not accompanied by edema or mass effect. A repeat CT without and with contrast was performed 12 days later and showed no change. The right parietal lucency was thought to represent an area of prior cerebral infarction that had been undetected clinically.

Thirty days after the ictus the right hemiparesis persisted but was of much milder degree; very mild right facial weakness persisted. The hyperflexia on the right was more pronounced. Speech remained labored but output was increased and consisted of short terse word series spoken "telegraph style." Sixty days after the ictus the hesitations and paraphasias were less frequent. Short phrases with the correct use of participles and appropriate verb tenses were produced. At 90 days prosody and intonation were normal and paraphasias were infrequent. At this time the major speech defects consisted of persistent hesitations, mostly on the first syllables of words, and an overall reduction in speech output. Gradual improvement continued for the next several months. The examinations 9 and 20 months after the ictus were similar. At this time BDAE aphasia severity rating was 4. The BDAE rating scale profile showed only the characteristics of mild articulatory impairment. The melodic line was normal (BDAE score 7, range 1-7), phrase length was 7 words (score 7), the articulatory agility was occasionally impaired (score 5), and the grammatical form was in the normal range (score 7). All other language functions remained intact. The patient continued to manage his own affairs throughout.

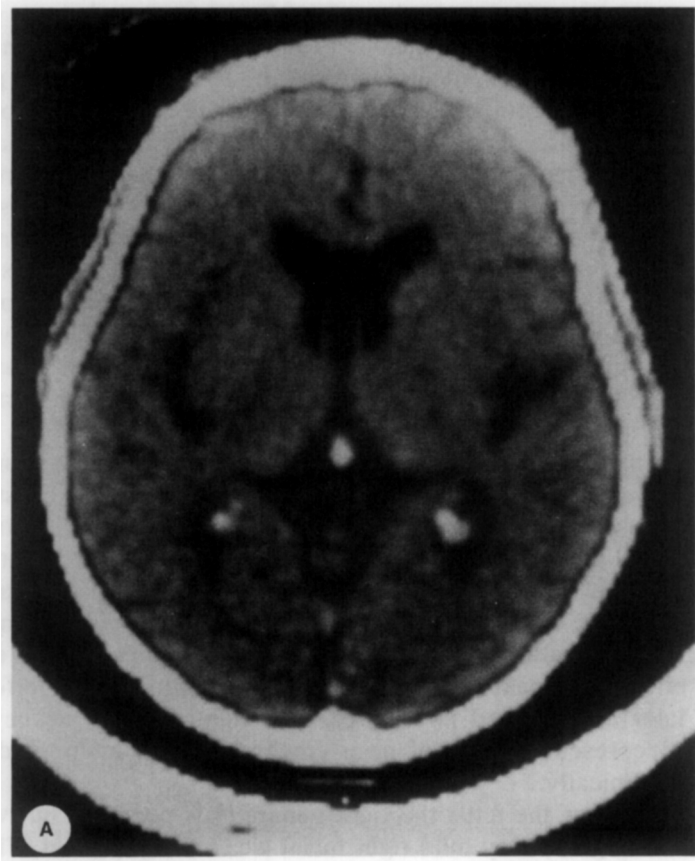

FIG. 1. This initial CT at the approximate level of the PET images shown in Fig. 2 discloses no abnormality of the cortical and subcortical structures of the left hemisphere (A). The left hemisphere is to the viewer's left. The hypodensity in the right parietal lobe was not altered after contrast administration and remained unchanged 11 days later (B).

METHOD OF METABOLIC IMAGING

After informed consent was obtained from the patient, images of local cerebral glucose metabolism using ^{18}F -fluorodeoxyglucose (FDG) were obtained 4, 11, and 72 days after the ictus. This technique has been fully described previously (Reivich, 1979). Quantitative metabolic data were derived using the operational equation of Sokoloff et al. (1977). The lumped constant has been measured in our laboratory and found to be 0.542 (Reivich, 1985). During the prescan isotope uptake period of 40 min the patient lay supine with eyes and ears unencumbered. Ambient noise and activity of personnel in the scan room were kept to a minimum and dim fluorescent light was present. A modified version of the PETT V imaging system was employed (Ter-Pogossian, 1978). This system has an intrinsic design resolution of 11.5 mm, an effective image resolution of 16.5 mm, and generates simultaneously seven cross-sectional images of brain (width 17.4 mm) along the rostrocaudal axis. Two 16- to 20-min scans yielded a total of 14 "slices" of brain per session. A minimum of one

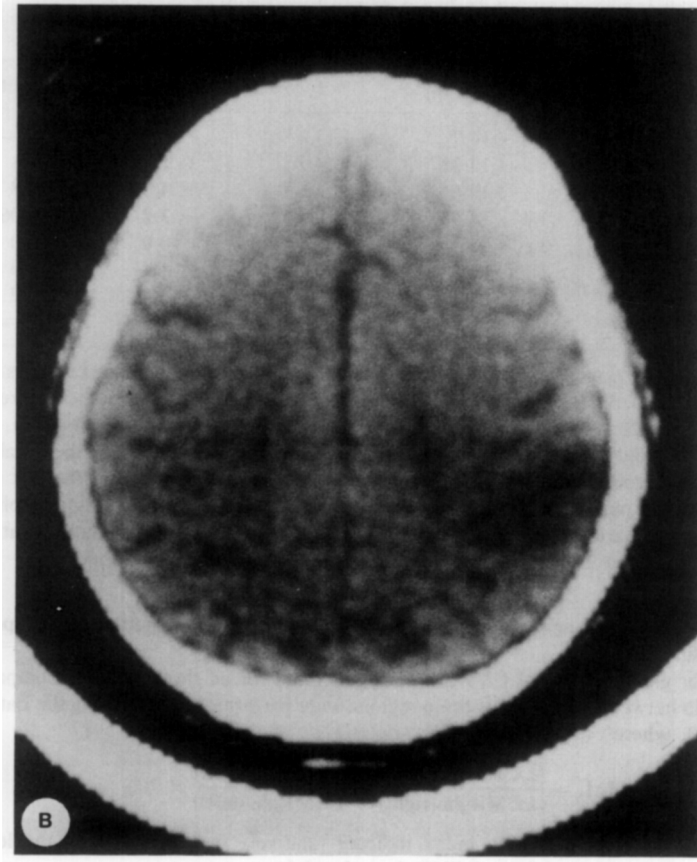


FIG. 1—Continued.

million counts per slice were collected. Between the first and second scans the patient was displaced relative to the scanner along the rostrocaudal axis so that the seven images from each scan were intercalated by one-half of a slice thickness. The procedures employed for image reconstruction and machine calibration have been described elsewhere (Kushner, 1984).

Localization of cortical and subcortical regions of interest was accomplished by comparing the PET images with routine diagnostic CT scans, and standardized human brain atlases (Matsui, 1978; Adair, 1981; Dann, 1983). Landmarks such as the subcortical gray masses, maximum cranial dimensions, and ventricular configuration were used to relate each PET image to the corresponding CT and brain atlas levels. For each PET image the relative spatial relationships of the cortical and subcortical regions of interest aided in localizing these regions to locations on the lateral and horizontal views of the brain. The resulting data set comprised of the metabolic images and the global and regional rates for CMRglu were analyzed both qualitatively and quantitatively.

The metabolic images were reviewed by independent observers. The presence of focal disturbances of local glucose consumption in the metabolic images was sought by comparing suspect regions with homologous brain regions and by comparing the metabolic images

TABLE 1
REGIONAL CEREBRAL GLUCOSE METABOLISM (L.I.)

Region	1	2	3	Controls
Left ischemic core	+14.7	+13.4	+23.8	—
Caudate	+12.3*	+14.2*	+1.0	-3.1 (1.9)
Thalamus	+10.6*	+15.9*	+4.0	+1.8 (2.2)
Inferior frontal cortex	+14.6*	-0.1	-3.2	+3.06 (1.4)
Insular cortex	+13.2*	+8.0*	0.0	+3.0 (1.1)
Frontal pole	+2.2	-3.0	-1.4	0.0 (1.1)
Occipital pole	-1.1	-4.8	-2.3	-0.2 (1.8)
Right parietal lesion	-40.4	-49.0	-38.7	—

Note. This table compares asymmetries in CMRglu between homologous regions in the two cerebral hemispheres. Mean values in the laterality index (L.I.) for the controls are presented in the last column along with the SEM in parentheses. A positive L.I. value indicates a relatively lower value for CMRglu on the left. Early asymmetries in the metabolism of structures surrounding the ischemic core had resolved by the time of the last study. Asymmetries did persist in the region of the acute left-sided lesion while metabolism in the chronic right parietal hypodensity seen on CT remained unchanged throughout.

* Lies beyond the 95% cutoffs anticipated from the normal distribution.

with those derived from aged-matched controls. These reviews were performed independent of the CT findings.

Values for global and local CMRglu were generated for all three studies. Comparisons of LCMRglu between homologous brain regions were performed by analyzing the Laterality Index (L.I.), where

$$L.I. = \frac{[LCMRglu (right) - LCMRglu (left)]}{[LCMRglu (right) + LCMRglu (left)]} \times 200.$$

Positive values of the laterality index indicate relatively less LCMRgl on the left and negative numbers relatively less LCMRgl on the right.

These results were compared with pooled data from 20 healthy elderly normal controls (Chawluk, 1985). Perturbations in the normal metabolic "landscape" were sought by examining the regional L.I. values over all three studies and by comparing the patient L.I. values with those of the controls.

RESULTS

Glucose consumption in homologous brain regions was generally symmetric in the control subjects with values of L.I. ranging from +7.85 to -5.36 in 48 selected regions of interest (Table 1). Similar degrees of symmetry have been previously described for younger controls in reports from this and other laboratories (Greenberg, 1981; Mazziotta, 1982).

Average whole brain glucose metabolism over the three studies was 4.4 mg \pm 1.0 (SEM) mg/100 g/min. A well-demarcated zone of marked hypometabolism centered just superior to the left lenticular nucleus was apparent on the initial scan (Fig. 2). Here metabolism remained depressed over all studies as compared to the homologous region (Table 1). Medially, this hypometabolic zone included the head of the caudate and lateral

thalamus. Laterally, metabolism was depressed in the inferior frontal cortex, and inferiorly, in the superior insular cortex (Fig. 2). Eleven days after the ictus hypometabolism persisted but was of lesser spatial extent (Fig. 2). Metabolism in the surrounding subcortical gray masses at the periphery of the lesion remained depressed but the hypometabolism in the adjacent overlying cortical regions had lessened (Table 1). At 72 days a mild irregular area of decreased metabolism persisted at the initial ischemic core but metabolism in the surrounding structures was no longer depressed compared to homologous regions. Metabolism in the anterior frontal, posterior temporal, inferior parietal, and occipital regions was symmetric throughout all studies. The right parietal lucency noted on CT was also demonstrated on each PET study (Fig. 2). Metabolism in this region remained profoundly depressed as compared to the contralateral brain region through all three studies. The appearance of this lesion and that of adjacent structures remained stable throughout the multiple CT and PET studies. Corresponding lateral and horizontal schematic views of the brain are presented in Fig. 3. The hypometabolic focus could be localized to the junction of the posterolateral inferior frontal cortex, the superior insular cortex, and the adjacent subcortical space.

DISCUSSION

Bastien (1898) first differentiated between two states in which speech is nonfluent while writing and other language functions are preserved. The first syndrome, which he termed aphemia, is characterized by recovery of appropriate word usage and correct grammar following a variable period of hypophonia. In the second, termed motor aphasia, agrammatisms and inappropriate word usage persist as does profound nonfluency. This categorization has been espoused in one form or another by most later authors (Goldstein, 1948; Bay, 1962; Brown, 1972). Several synonymous and closely related terms denote these syndromes and these include pure word mutism, pure anarthria, and peripheral or subcortical motor aphasia (Lecours, 1976). This multiplicity of terms has caused some lack of clarity in nomenclature. The available structural data from autopsy and CT reports indicate that aphemia arises from relatively limited lesions of anterior periopercular structures (Benson, 1979; Lecours, 1976). Marie (1906) suggested that "anarthria" results from lesions in the region of the lenticular nucleus and internal capsule, the so-called "quadrilateral space." Damage to Broca's area or its disconnection from associated speech areas has also been suggested as an etiology (Dejerine, 1914; Ruff, 1981). This view has not been supported by the few available autopsy reports where involvement was limited to the inferior aspect of the precentral gyrus, Broca's area being spared (Dejerine, 1906; Lecours, 1976; Masdeu, 1982). On the other hand, syndromes of motor aphasia and mutism have been associated with Broca's area lesions, both alone

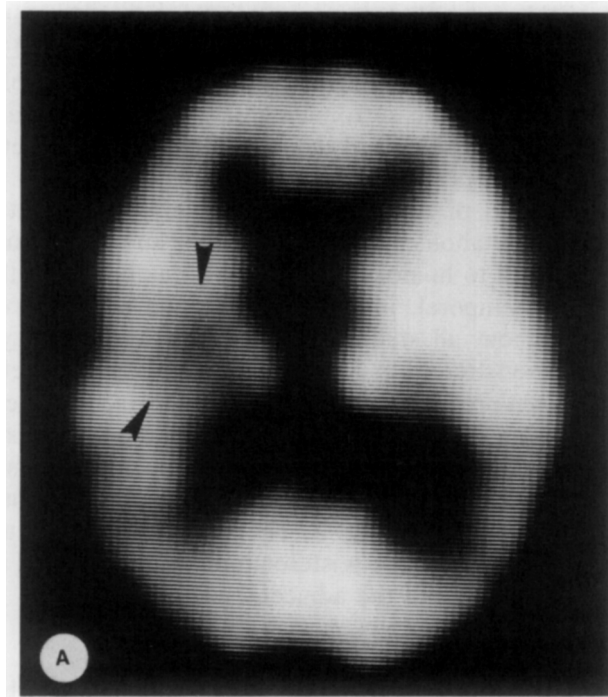


FIG. 2. Selected cross-sectional images from each PET session. The left hemisphere is on the viewer's left. The degree of brightness reflects local glucose consumption on a continuous gray scale. (A) Day 4. A circumscribed area of hypometabolism is located deep in the left hemisphere (arrows). Metabolism is depressed in the overlying cortex and nearby basal ganglia and thalamus. (B) Day 11. The deep hypometabolism persists (arrow) but the degree of metabolic depression has lessened in the surrounding cortical and subcortical gray matter. (C). Day 72. The angle of this image differs slightly from that of (A) and (B) above. The right parietal lesion is clearly defined on this view (arrows). A subcortical metabolic abnormality persists on the left (arrow).

and in combination with adjacent cortical involvement (Dejerine, 1906; Symonds, 1953). Mohr (1978) found that isolated lesions of Broca's area produce acute mutism rather than the typical nonfluent speech of Broca's aphasia. Alajouanine (1939) described what he considered to be a subtype of aphemias which he termed "pure phonetic disintegration". In this syndrome the speech is marked by distortion of phonemes, literal paraphasias, and hesitations. Lecours (1976) reported the autopsy findings in one of Alajouanine's later cases. He found the pathology to be limited to the base of the precentral gyrus; Broca's area was uninvolved. The relatively benign features of the current case are consistent with those found in pure phonetic disintegration.

As in the case of Lecours, the abnormality in our case lay near the

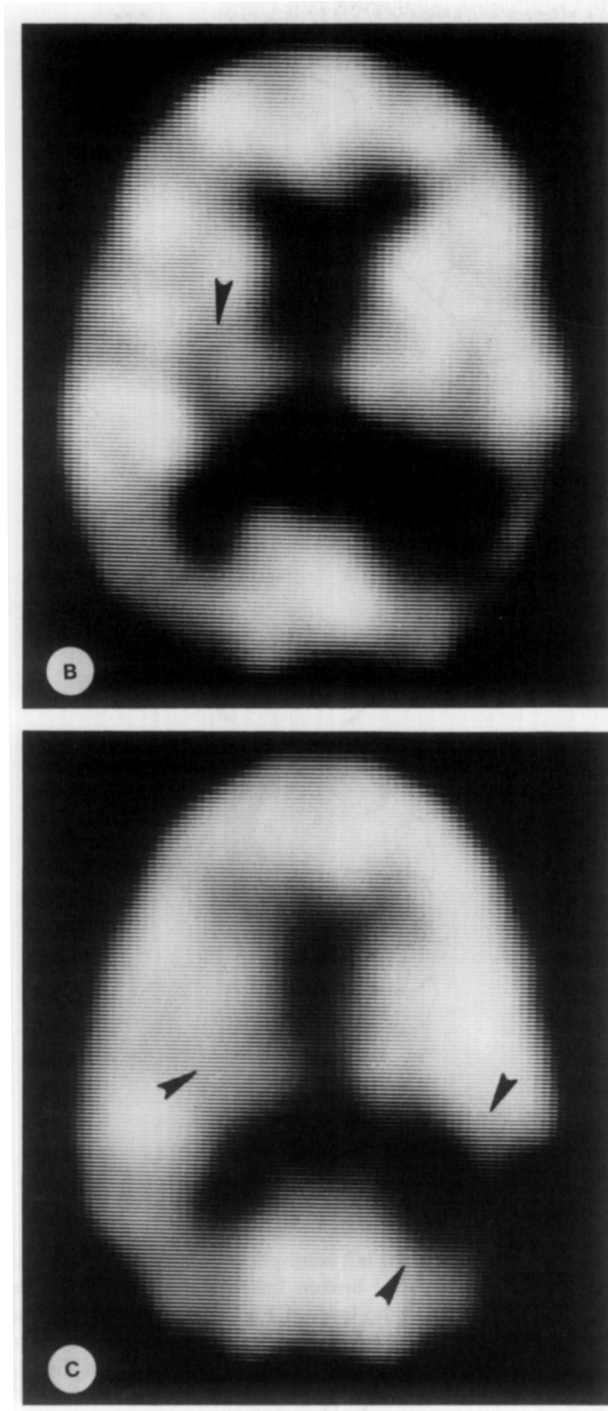


FIG. 2—Continued.

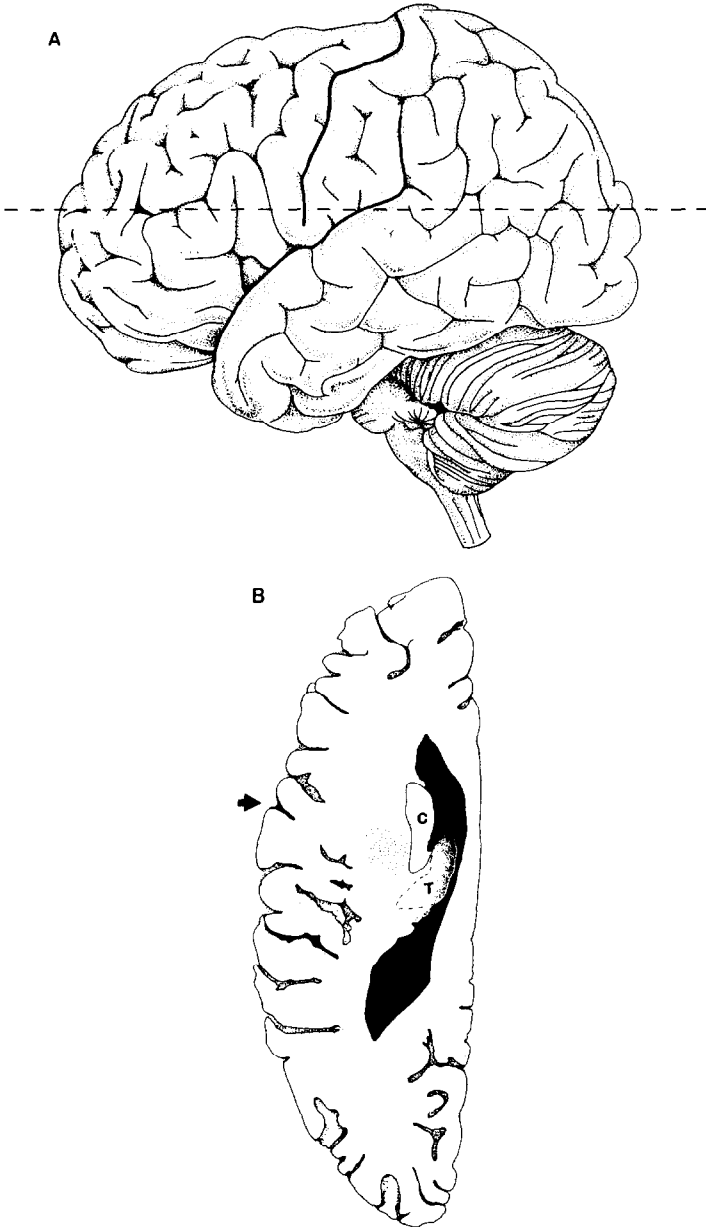


FIG. 3. Schematic lateral view of the left hemisphere (A); the central sulcus and Sylvian fissure are outlined in heavy ink. The broken line corresponds to the plane of scan. Schematic brain cross-section (B) at the level of Fig. 2A. Arrow denotes central sulcus (heavy ink); anterior lies the precentral gyrus. The heavy stippling in the subcortical space represents the location of the maximal metabolic depression seen in Fig. 2A. Adjacent frontal cortex and superior insular cortex along with caudate (C) and the thalamus (T) exhibited reversible metabolic depression. The thalamus is outlined in broken lines to denote the partial volume averaging of thalamic tissue counts in the slice thickness of image Fig. 2A.

inferior aspect of the precentral gyrus (Fig. 3); Broca's area was removed from the region of hypometabolism. The PET studies showed that in addition to hypometabolism in the cortex, subjacent gray and white structures also were involved. The meaning of this is uncertain since subcortical involvement of a similar extent has not been described pathologically.

Some caution must be exercised in the interpretation of the PET data in this case. Uncertainty may arise from various physiologic, physical, and biochemical factors and these deserve brief discussion. While stroke is experienced primarily by the aged, the current experience with PET techniques is weighted toward younger normals. Inhomogeneous delivery of substrate in ischemic regions (arising from disrupted perfusion patterns) as well as perturbation in the kinetic rate constants or the lumped constant of the operational equation could alter measured glucose metabolism (Metter, 1981; Wise, 1983). Also the spatial resolution of the current PET imaging cameras imposes limitations on precise anatomic localization (Hoffman, 1979). In this analysis relative laterality values of glucose consumption were studied rather than the absolute levels of LCMRglu. Transforming the data in this manner serves to reduce the rather large variances found in the absolute values for CMRglu (Clark, 1985). In young controls the mean coefficient of variation for such relative metabolic values was 5.9%, whereas for the absolute metabolic rates in the same regions it was 15.2%. This parallels the variability in the global CMRglu of these subjects (14.7%) and agrees well with published data (Duara, 1985). A strictly quantitative analysis also was hampered by the fact that the second and third scans were performed using a source of isotope different from the first. In normal young male controls we have found up to a 10% difference in mean global CMRglu, depending upon the source of the isotope (7.2 ± 1.1 , $N = 6$, versus 6.49 ± 1.59 , $N = 7$). The magnitude of error inherent in comparing results gained from studies using different isotope sources has been addressed (Reivich, 1985). Despite these caveats, including those concerning image resolution, the current quantitative and qualitative results documented the evolution of a dynamic metabolic disturbance at the junction of the inferior precentral and peri-insular regions which spared Broca's area and the posterior cortical speech areas.

The extent of the ictal hypometabolism in the current case is somewhat unanticipated, given the minimal physical signs and the absence of a corresponding CT lesion. The exact nature of these remote metabolic effects remains unclear. Recent PET studies have demonstrated abnormalities in excess of those that might be anticipated given the clinical and CT findings as well as abnormalities far removed from the primary lesion (Metter, 1981; Heiss, 1983; Kushner, 1984). Possible mechanisms for these phenomena include transneuronal inactivation, local humoral

disturbances, or the effects of incomplete ischemia. Further study will be required before these issues are resolved.

These results suggest that an upper motor neuron lesion of the articulatory apparatus, very likely involving the base of the precentral gyrus and adjacent structures, is responsible for aphemia. This is in accord with some prior speculations (Lecours, 1976). It is uncertain whether the profound ictal hypophonia is due to reversible dysfunction in this locale or to concomitant but reversible involvement of other speech areas (or their interconnections). In this case, regression of the spatial extent of the metabolic abnormalities roughly paralleled the clinical improvement. This suggests that reversal of involvement of other related speech areas contributed to recovery.

Increasing attention is being paid to the role of subcortical lesions in less common aphasic syndromes (Naeser, 1982; Damasio, 1982). While our PET results showed involvement of subcortical structures, the limits of resolution prohibit assertions as to the exact site of maximal involvement (e.g., putamen, opercular cortex, internal capsule). While it is possible that disconnection of the left and right articulatory centers played some role in this syndrome, the lack of demonstrable apraxia provides no support for this. Rather these findings suggest primacy of the left hemisphere in the control of articulation (Damasio, 1982).

REFERENCES

- Adair, T., Karp, P., Stein, A., et al. 1981. Computer assisted analysis of tomographic images of the brain. *Journal of Computer Assisted Tomography*, **5**, 929-932.
- Alajouanine, T., Ombredane, A., & Durand, M. 1939. *Le syndrome de desintegration phonetique dans l'aphasie*. Paris: Masson.
- Basso, A., Taborelli, A., & Vignolo, L. A. 1978. Dissociated disorders of speaking and writing in aphasia. *Journal of Neurology, Neurosurgery and Psychiatry*, **41**, 556-563.
- Bastien, H. C. 1929. *Aphasia and other speech defects*. London: HK Lewis.
- Bay, E. 1962. Aphasia and non-verbal disorders of language. *Brain*, **85**, 411-426.
- Benson, D. F. 1979. *Aphasia, alexia, and agraphia*. New York: Churchill Livingstone.
- Brown, J. W. 1972. *Aphasia, apraxia and agnosia*. Springfield, IL: Thomas.
- Chawluk, J., Alavi, A., Hurtig, H., et al. 1985. Altered patterns of regional cerebral glucose metabolism in aging and dementia. *Journal of Cerebral Blood Flow Metabolism*, **5** (Suppl. 1), 121-122.
- Clark, C., Carson, R., Kessler, R., et al. 1985. Alternative statistical models for the examination of clinical positron emission tomography/fluorodeoxyglucose data. *Journal of Cerebral Blood Flow Metabolism*, **5**, 142-150.
- Damasio, A. R., Damasio, H., & Rizzo, M. 1982. Aphasia with nonhemorrhagic lesions in the basal ganglia and internal capsule. *Archives of Neurology*, **39**, 15-20.
- Dann, R., Muehlechner, G., & Rosenquist, A. 1983. Computer aided data analysis of ECT data. *Journal of Nuclear Medicine*, **24**(5), 82.
- Dejerine, J. 1906. L'aphasie motrice: Sa localization et son anatomie pathologique. *Press Medicale*, **14**, 453-457.
- Dejerine, J. 1914. *Semiologie des affections de systeme nerveux*. Paris: Masson.
- Duara, R., Barlar, W., Apicella, A., et al. 1985. Resting cerebral glucose metabolism:

- Intraindividual versus interindividual variability in young and elderly subjects. *Neurology* **35**, 138.
- Folstein, M. F., Folstein, S. E., & McHugh, P. R. 1975. "Mini mental state": A practical method for grading the cognitive state of patients for the clinician. *Journal of Psychiatric Research*, **12**, 189-198.
- Greenberg, J. H., Reivich, M., & Alavi, A. 1981. Metabolic mapping of functional activity in human subjects with the (18F) fluorodeoxyglucose technique. *Science*, **212**, 678-680.
- Goldstein, K. 1948. *Language and language disturbance*. New York: Grune and Stratton.
- Goodglass, H., & Kaplan, E. 1972. *The assessment of aphasia and related disorders*. Philadelphia: Lea & Febiger.
- Heiss, W. D., Pawlik, G., Wagner, H. W., et al. 1983. Functional hypometabolism of noninfarcted brain regions in ischemic stroke. *Journal of Cerebral Blood Flow and Metabolism*, **3**, (Suppl. 1), S582-S583.
- Hoffman, E. T., Huang, S. C., & Phelps, M. E. 1979. Quantitation in positron emission computed tomography. I. Effect of object size. *Journal of Computer Assisted Tomography*, **3**, 299-308.
- Kuhl, D. E., Phelps, M. E., Kowell, A. P., et al. 1980. Effect of stroke on local cerebral metabolism and perfusion. *Annals of Neurology*, **8**, 47-60.
- Kushner, M., Reivich, M., Alavi, A., et al. 1984. Contralateral cerebellar hypometabolism following cerebral hemispheric insult: a positron emission tomographic study. *Annals of Neurology*, **15**, 425-434.
- Lecours, A. R., & L'Hermitte, F. 1976. The "pure form" of the phonetic disintegration syndrome (pure anarthria): Anatomico-clinical report of an historical case. *Brain and Language*, **3**, 88-113.
- Marie, P. 1906. Revision de la question de l'aphasie. *Semaine Medicine*, **26**, 241-249.
- Masdeu, J. L., & O'Hara, R. J. 1982. Broca's area and precentral operculum: Language disturbances resulting from discrete infarcts of either region. *Neurology*, **32**, (No. 5, Part 2), 90.
- Matarazzo, J. D. 1972. *Wechsler's measurement and appraisal of adult intelligence*, ed 5. Baltimore: Williams and Wilkins.
- Matsui, T., & Hirano, A. 1978. *Atlas of the human brain for computed tomography*. Tokyo: Iguko-Shuin.
- Mazziotta, J. C., Phelps, M. E., & Carson, R. E. 1982. Tomographic mapping of human cerebral metabolism: sensory deprivation. *Annals of Neurology*, **12**, 435-444.
- Metter, E. J., Wasterlain, C. G., & Kuhl, D. E. 1981. 18FDG positron emission computed tomography in a study of aphasia. *Annals of Neurology*, **10**, 173-183.
- Mohr, J. P., Pessin, M. S., & Finkelstein, M. D. 1978. Broca aphasia pathological and clinical. *Neurology*, **28**, 311-324.
- Naeser, M. A., Alexander, M. P., & Helm-Estabrooks, N. H. 1982. Aphasia with predominantly subcortical lesion sites. *Archives of Neurology*, **39**, 2-14.
- Phelps, M. E., Mazziotta, J. C., Kuhl, D. E., et al. 1981. Tomographic mapping of human cerebral metabolism: Visual stimulation and deprivation. *Neurology*, **31**, 517-529.
- Reivich, M., Kuhl, D., Wolf, A., et al. 1979. The (18F) fluorodeoxyglucose method for the measurement of local cerebral glucose utilization in man. *Circulation Research*, **44**, 127-137.
- Reivich, M., Alavi, A., Wolf, A., et al. 1985. Glucose metabolic rate kinetic model parameter determination in man: The lumped constants and rate constants for 18F-fluorodeoxyglucose and 11C-deoxyglucose. *Journal of Cerebral Blood Flow and Metabolism*, **5**, 179-192.
- Ruff, R. L., & Arbit, E. 1981. Aphemia resulting from a left frontal hematoma. *Neurology*, **31**, 353-356.

- Russell, W. R., & Espir, M. L. E. 1962. *Traumatic aphasia*. London: Oxford Univ. Press.
- Russell, W. R., Neuringer, C., & Goldstein, G. 1970. Assessment of brain damage: A neuropsychological key approach. New York: Wiley.
- Sokoloff, L., Reivich, M., Kennedy, C., et al. 1977. The (¹⁴C) deoxyglucose method for the measurement of local cerebral glucose utilization: Theory, procedure and normal values in the conscious and anesthetized albino rat. *Journal of Neurochemistry*, **28**, 897-916.
- Symonds, C. 1953. Aphasia. *Journal of Neurology, Neurosurgery and Psychiatry*, **16**, 1-6.
- Ter-Pogossian, M. M., Mallani, N. A., & Hood, J. T. 1978. Design considerations for a positron emission transverse tomograph (PETT V) for imaging of the brain. *Journal of Computer Assisted Tomography*, **2**, 539-544.
- Wise, R. T., Rhodes, C. G., Gibbs, T. M., et al. 1983. Disturbance of oxidative metabolism of glucose in recent human cerebral infarcts. *Annals of Neurology*, **14**, 627-637.