

Case Report

Focal Asterixis Caused by a Small Putaminal Hemorrhage

José M. Trejo, Santiago Giménez-Roldán, and Angel Esteban

Department of Neurology and Division of Clinical Neurophysiology, Hospital Provincial, Madrid, Spain

Summary: Unilateral asterixis and mild pure motor hemiparesis contralateral to a small putaminal hemorrhage were observed in a 74-year-old hypertensive man. The motor deficit proved to be rapidly reversible, but the focal asterixis remained for some time as the only sign of the intracranial hemorrhage. This case suggests that altered striopallidal inhibitory input to the thalamus probably disturbed the circuit subserving the maintenance of postural tone. **Key Words:** Asterixis—Putamen—Pure motor hemiparesis—Intracranial hemorrhage.

Asterixis is a brief lapse of postural tone that is most commonly observed while the patient holds his hands outstretched. The phenomenon is usually bilateral when there is an underlying metabolic disorder. Unilateral asterixis occurs after focal damage to any of a number of brain structures, including the mesencephalon, thalamus, frontal and parietal lobes, as well as the pons and internal capsule (1,2). It has been postulated that these structures subserve a cortico-subcortical circuit that is involved in the maintenance of postural tone (3). To the authors' knowledge, however, focal asterixis secondary to a putaminal lesion has not been described previously and would implicate the striatum as a functional member of this circuit.

CASE REPORT

A 74-year-old hypertensive man was admitted 24 h after the sudden onset of weakness of his right limbs and slight speech impairment. He was fully alert and could express himself without aphasic speech, although he did exhibit some articulatory defects. On examination, he had a minimal right hemiparesis and could walk without help. There was some flattening of the right nasolabial fold, and the

Address correspondence and reprint request to Dr. S. Giménez-Roldán at Department of Neurology, Hospital Provincial, Doctor Esquerdo 42, Madrid-28007, Spain.

right plantar response was extensor. The findings on sensory examination were normal, including proprioception, and there was no evidence of neglect. With hands outstretched, rapid and brief lapses of posture of his right hand were revealed by a downward falling movement; this was observed with the hand either in a supine or a prone position. The abnormal movement was not rhythmic and occurred at a frequency of about 40 per minute. This frequency remained unchanged when the patient's eyes were closed, and even though he was fully aware of the involuntary jerks, he was unable to prevent them.

An electrophysiological examination by means of surface electrodes on the flexor and extensor muscles of the forearm showed that during the postural lapses, there was complete interruption of muscle activity, involving both agonist and antagonist muscle groups. Such periods when electrical activity was absent were irregular, lasting up to a maximum of 100 ms. They were not recorded in the biceps and triceps muscles of the ipsilateral limb. Cortical somatosensory evoked potentials to median nerve stimulation were normal bilaterally.

Any systemic metabolic abnormality was excluded by appropriate laboratory tests. A computed tomography (CT) scan of the head demonstrated a small hemorrhage that was mostly confined to the left putamen, though slightly extending into the globus pallidus as well. It was about 1 cm in transverse diameter, with minimal surrounding edema and no midline shift. Three weeks later, it had been completely reabsorbed, leaving a small area of hypodensity (Fig. 1).

Forty-eight hours after its onset, the hemiparesis began to subside, and 7 days later, muscle strength was back to normal, though the patient still exhibited some slowness of his right hand in opposing the thumb to the other fingers. The focal asterixis, however, persisted, decreasing over the following 2 weeks and disappearing 2 months after onset. By that time, he had fully recovered manual dexterity.

DISCUSSION

This patient suffered from a pure motor hemiparesis that was secondary to a small contralateral putaminal hemorrhage (4). In most cases, putaminal hemorrhages are fatal or leave severe focal motor deficits, particularly when their size is large (5). Neurological deficits associated with small hemorrhages may be completely reversible (6,7). We believe that the slight initial motor impairment in our patient, followed by rapid recovery, was a precondition for the focal asterixis to manifest itself in the limbs involved; presumably, it might have been absent in a dense hemiplegia. Other authors have reported the appearance of asterixis in parallel to recovery of the associated motor deficit (8), and in a number of instances, focal asterixis was not associated with any motor deficit (9,10). It is interesting to note that for some weeks the focal asterixis was the only demonstrable neurological abnormality resulting from the intracranial hemorrhage. Encroachment into the thalamus and internal capsule by the hemorrhage itself is therefore an unlikely explanation for the asterixis in this case (11,12).

The most common sites at which a focal lesion produces unilateral asterixis are

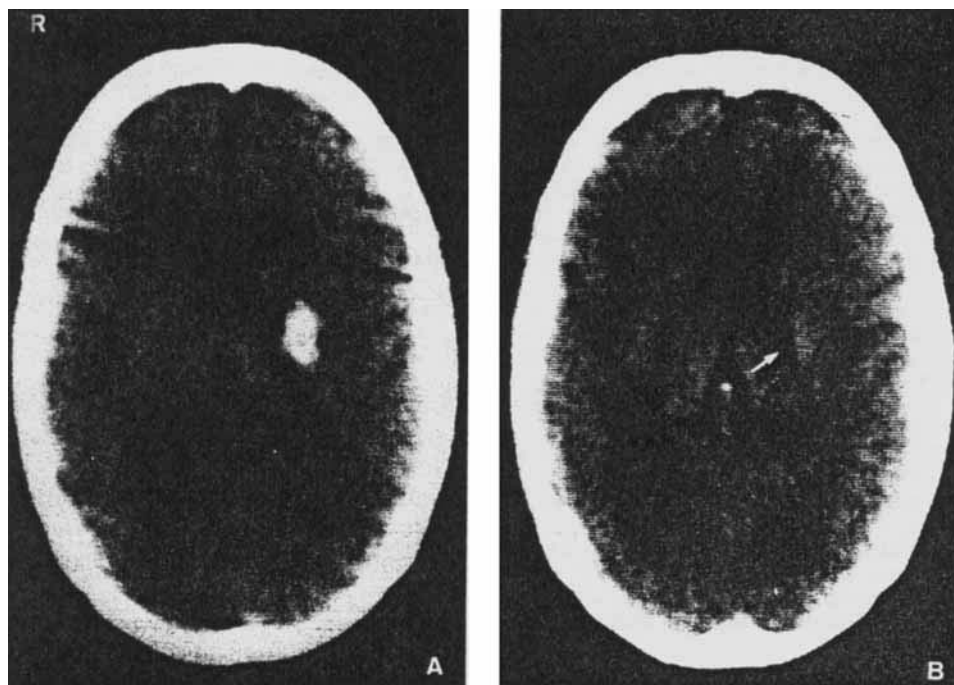


FIG. 1. A small left-sided hemorrhage, mainly involving the putamen, as found on admission, is shown in A. Three weeks later, it has been completely reabsorbed, leaving a small low-density area (arrow) (B).

the mesencephalon (13), the thalamus (11,12) and the parietal and frontal lobes (1). Shahani and Young (1) postulated that these interconnected brain structures comprise a circuit necessary for the maintenance of postural tone. Our observations would indicate that the striatum is also involved in this system and participates in maintaining postural tone. Limited damage to the striopallidal complex probably impaired GABAergic inhibitory output to the thalamus and from there to the motor cortex. Some authors (9), on the other hand, interpret focal asterixis as a localized inattention failure secondary to a disturbance of sensory integration in the mesencephalon, thalamus, or parietal cortex. This mechanism is unlikely in our patient, as careful examination disclosed no sensory deficit and the somatosensory evoked potentials were also in keeping with an undamaged sensory pathway.

Focal asterixis may be encountered after localized damage to the central nervous system, involving any of a number of different structures, and the putamen should be considered another potential site. In the present case, the associated motor deficit regressed, while the focal asterixis remained for some time as the only neurological impairment secondary to the lesion caused by the putaminal hemorrhage.

REFERENCES

1. Young RR, Shahani BT. Asterixis: One type of negative myoclonus. *Adv Neurol* 1986;43:137-55.
2. Kudo Y, Fukai M, Yamadori A. Asterixis due to pontine haemorrhage. *J Neurol Neurosurg Psychiatry* 1985;48:487-9.
3. Shahani BT, Young RR. Asterixis: a disorder of the neural mechanism underlying sustained muscle contraction. In: Shahani M, ed. *The motor system: neurophysiology and muscle mechanisms*. Amsterdam: North Holland, 1977:301-6.
4. Tapia JF, Kase CS, Sawyer RW, et al. Hypertensive putaminal haemorrhage presenting as pure motor hemiparesis. *Stroke* 1983;14:505-6.
5. Hier DB, Davis KR, Richardson EP Jr, et al. Hypertensive putaminal haemorrhage. *Ann Neurol* 1977;1:152-9.
6. Brusa A, Piccardo A, Meneghini S, et al. Cerebral haemorrhages presenting as reversible clinical entities. *Ital J Neurol Sci* 1982;4:333-7.
7. Scott WR, Miller BR. Intracerebral haemorrhage with rapid recovery. *Arch Neurol* 1985;42:133-6.
8. Davalos A, Titus F, Cervera J, et al. Asterixis unilateral: un signo de lesiones focales cerebrales. *Rev Neurol (Barcelona)* 1982;10:127-31.
9. Degos JD, Verroust J, Bouchareine A, et al. Asterixis in focal brain lesions. *Arch Neurol* 1979;36:705-7.
10. Santamaria J, Graus F, Martínez J, et al. Asterixis en lesiones focales del sistema nervioso central. *Rev Clin Esp* 1983;168:37-9.
11. Donat JR. Unilateral asterixis due to thalamic hemorrhage. *Neurology* 1980;30:83-4.
12. Massey EW, Goodman JC, Stewart C, et al. Unilateral asterixis: motor integrative dysfunction in focal vascular disease. *Neurology* 1979;29:1188-90.
13. Brill V, Sharpe JA, Ashby P. Midbrain asterixis. *Ann Neurol* 1979;6:362-4.