

Cerebral Venous Thrombosis as a Cause of Neonatal Seizures

Victor K. Wong, MD, James LeMesurier, MD, Ralph Franceschini, MD, Moosa Heikali, MD, and Rebecca Hanson, MD

Intracranial venous thrombosis has been described in newborns, but there have been no reports of intractable neonatal seizures due to this condition. We report cortical venous sinus thrombosis in two term neonates who presented with seizures in the first 24 hours of life. The diagnosis was made by cranial computed tomography and was confirmed by cerebral angiography. Both patients improved clinically after the intracranial venous thrombosis resolved. These patients demonstrate that intracranial venous thrombosis should be considered in the differential diagnosis of neonatal seizures.

Wong VK, LeMesurier J, Franceschini R, Heikali M, Hanson R. Cerebral venous thrombosis as a cause of neonatal seizures. *Pediatr Neurol* 1987;3:235-7.

Introduction

Intracerebral venous thrombosis has been described in all age groups, including newborns, but there have been no reports of intractable seizures in the first 24 hours of life due to this condition. We report two term neonates who presented with seizures in the first 24 hours of life; cortical venous sinus thrombosis was diagnosed by cranial computed tomography (CT) and was confirmed by cerebral angiography.

Case Reports

Patient 1. This female newborn was the product of a normal spontaneous vaginal delivery at 41 weeks gestational age to a 35-year-old gravida 1, para 0 mother. Poor tone and weak respiratory effort were observed initially with Apgar scores of 5 at 1 min and 7 at 5 min. On physical examination she was mildly tachypneic with poor peripheral perfusion. Neurologically, there was decreased tone with a weak Moro reflex. The remainder of the physical examination was unremarkable.

Initial complete blood count, serum electrolytes, serum glucose, and chest radiograph were within normal limits. A lumbar puncture yielded bloody cerebrospinal fluid (CSF) with 13,600

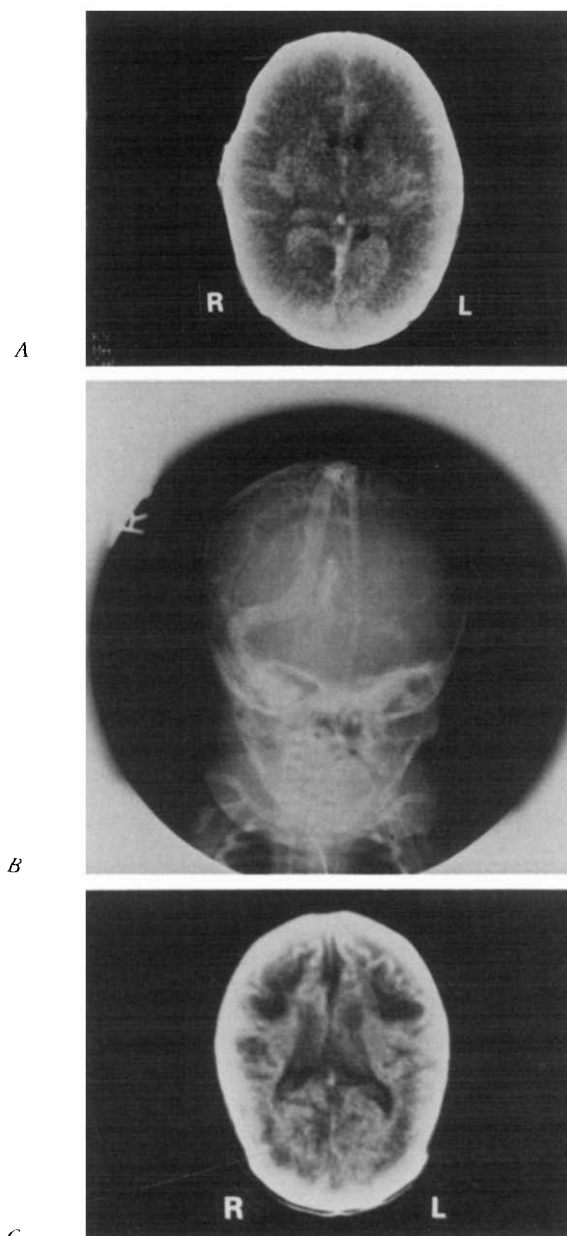
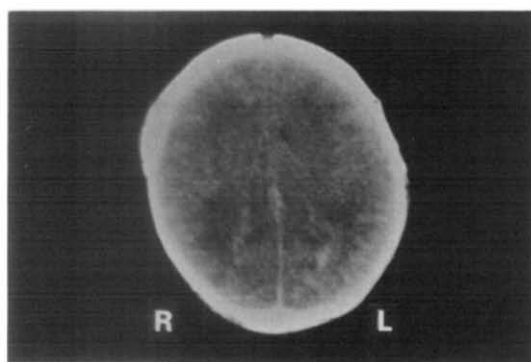


Figure 1. (A) CT demonstrating extensive symmetric low-density white matter of both cerebral hemispheres. High density within sagittal and straight sinuses and vein of Galen suggesting stasis of thrombosis. (B) A venogram demonstrating marked filling delay of venous sinuses with multiple medullary veins draining in a retrograde fashion suggesting impedance of flow secondary to intraluminal sinus thrombosis. (C) Subsequent CT at 2 months of age demonstrating extensive infarction and cerebral atrophy.

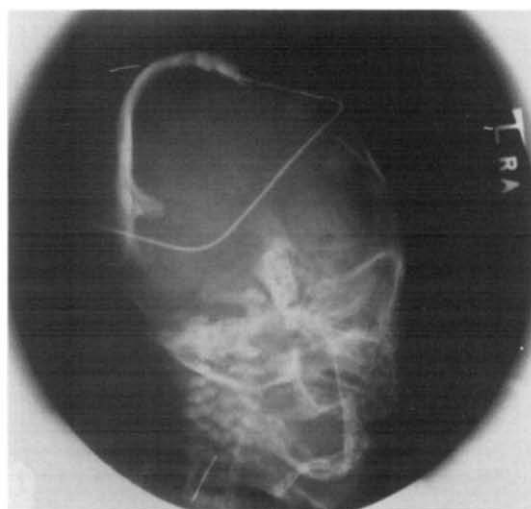
erythrocytes/mm³, 76 leukocytes/mm³ (28% segmented neutrophils and 72% monocytes); glucose was 150 mg/dl, total protein 163 mg/dl, and there were no organisms on Gram stain. An arterial blood gas on 40% hood oxygen revealed a pH of 7.08, Pco₂ of 24 torr, Po₂ of 64 torr, bicarbonate of 7.3 mEq/L, and base excess of -21.9.

From the Southern California Permanente Medical Center; Los Angeles, California.

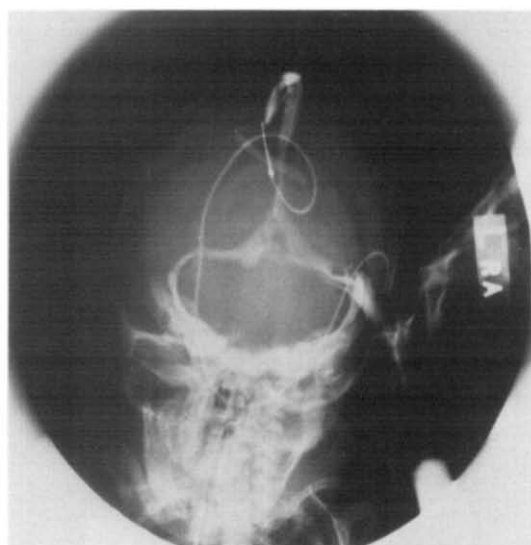
Communications should be addressed to:
Dr. Franceschini; Kaiser Foundation Hospital; Division of Pediatrics-Neonatology; 4867 Sunset Boulevard; Los Angeles, CA 90027.
Received June 15, 1987; accepted June 30, 1987.



A



B



C

Figure 2. CT with symmetric periventricular hemorrhage of both cerebral hemispheres; prominent sagittal and lateral sinuses suggesting marked stasis or thrombosis in the dural sinuses. (B) Venogram demonstrating complete occlusion of left lateral sinus, delayed filling of sagittal and right lateral sinuses, and numerous filling defects representing thrombi. (C) Subsequent venogram after urokinase infusion demonstrating patency of sagittal and lateral sinuses; a prominent filling defect still is observed in the left lateral sinus.

Volume expansion and slow infusion of sodium bicarbonate corrected the metabolic acidosis and poor peripheral perfusion. At 8 hours of age she developed episodes of tonic-clonic movements which initially were controlled with phenobarbital. Seizure activity recurred within hours despite therapeutic serum levels.

Cranial ultrasound was unremarkable, but cranial CT suggested sagittal sinus thrombosis with diffuse venous sinus congestion (Fig 1A). Arteriography confirmed the presence of intraluminal thrombosis in the sagittal sinus and jugular veins (Fig 1B). Phenytoin was added to the antiepileptic drug regimen along with hyperventilation and fluid restriction.

An electroencephalogram (EEG) at 2 days of age revealed left central and left midtemporal sharp waves and spikes, and a right arm clonic seizure concomitant with a left hemispheric 1 Hz spike-wave discharge. The patient's prothrombin time (PT), partial thromboplastin time (PTT), anti-thrombin-III (AT-III), and protein C levels all were within normal limits.

On subsequent examination at 2 months of age, the patient appeared well with the exception of mild spasticity, poor head growth, and weight gain. Cranial CT revealed extensive bilateral cerebral infarctions with cerebral atrophy (Fig 1C). At 56 weeks of age, the patient had an average developmental score of 48.5 weeks and a developmental quotient of 86 by the Gesell Developmental Test. Her head circumference, length, and weight were less than the 5th percentile. At 22½ months of age, the patient remained microcephalic with moderately severe language delay and maladaptive behavior. She had no seizures and subsequent EEGs demonstrated no abnormalities.

Patient 2. This male newborn was the product of a vaginal delivery at 42 weeks gestational age to a 24-year-old gravida 1, para 0 mother. The amniotic fluid was meconium-stained at the time of delivery. Apgar scores were 6 at 1 min and 7 at 5 min. The physical examination was normal except for moderate respiratory distress.

Initial complete blood count and chest radiograph were normal. A lumbar puncture yielded grossly bloody CSF with 3,888 erythrocytes/mm³, 22 leukocytes/mm³ (10% segmented neutrophils and 80% monocytes), glucose of 38 mg/dl, total protein of 256 mg/dl, and no organisms on Gram stain. An arterial blood gas in room air revealed pH of 7.22, Pco₂ of 13 torr, Po₂ of 130 torr, and base excess of 19.4.

The patient's acidosis was slowly corrected with sodium bicarbonate and at 8 hours of age he exhibited right-sided twitching which then progressed to generalized convulsions. Despite the administration of phenobarbital, the seizure activity continued. An EEG revealed a normal background and a prolonged burst of bitemporal rhythmic 1-2 Hz delta activity mixed with spikes.

CT at 22 hours of age disclosed symmetric parasagittal hemorrhage with increased density of the sagittal and lateral sinuses, suggesting thrombosis in the dural sinuses (Fig 2A). This diagnosis was confirmed by angiography (Fig 2B). Urokinase was infused locally into the venous sinus, 500 U/cc at 2 cc/hour. PT, PTT, anti-thrombin III, and protein C were obtained prior to the urokinase infusion and all were within normal limits.

The patient received 30 hours of urokinase therapy with establishment of left transverse sinus blood flow as observed on venograms obtained at 13 hours and 30 hours of therapy (Fig 2C). The remainder of the hospital course was one of gradual improvement with control of seizures obtained by phenobarbital. No neurologic deficits were observed at the time of discharge. Subsequent EEGs have demonstrated no specific abnormality, although a follow-up CT showed leukoencephalopathy with atrophy and resolving cortical hemorrhage. At 18 months of age, his cognitive development was normal, but he was nonambulatory due to a spastic diplegia.

Discussion

Neonatal seizures may result from a variety of causes, including perinatal asphyxia, metabolic imbalance, intracranial hemorrhage, developmental anomalies, in-

tracranial infections, and drug withdrawal [1].

There have been occasional reports of the association of intracerebral venous thrombosis (ICVT) and neonatal seizures, but none with the onset of seizure activity or the diagnosis established on the day of birth [2,3].

The pathophysiology of ICVT in neonates, as well as in adults, remains unclear. Imai et al. [4] reported associations which included altered cerebral hemodynamics, sepsis, trauma, acidosis, thrombocytosis, and hypercoagulable states (e.g., anti-thrombin III deficiency, protein C deficiency, oral birth control pills, and pregnancy).

It has been suggested that superior sagittal sinus (SSS) blood flow velocities are markedly affected by turning the newborn's head [5], and that calvarial molding also may affect SSS blood flow [6].

Current radiographic modalities employed to diagnose SSS thrombosis include CT [7,8], technetium 99m pertechnetate brain scan [9], digital subtraction angiography [10], cerebral arteriography, and most recently magnetic resonance imaging [11].

In the patients reported here, the cause of ICVT was not apparent.

The optimal management of newborns with ICVT is unknown because the use of anticoagulants and thrombolytic agents has been reported only in a small number of patients [2,12]. The use of anticoagulant therapy (heparin) in adults with SSS thrombosis has been more widespread, but controversy still exists [2,13]. In Patient 1, thrombolytic agents were not employed in view of a partially patent SSS. Intracerebral pressure was lowered by conservative fluid management and hyperventilation. Repeat angiography on day 5 demonstrated improved SSS blood flow (Fig 2B). In Patient 2, the finding of complete occlusion of the left lateral sinus prompted institution of urokinase therapy with subsequent thrombolysis and re-establishment of venous drainage over a 24 hour period.

Seizure activity resolved in both patients with the re-establishment of cerebral vessel patency.

Although seizures of unclear etiology in the newborn

infant are frequently attributed to "birth asphyxia," our experience suggests that ICVT may be a more common event than was suspected previously. In term newborns with intractable seizures and no apparent etiology, the presence of intracranial venous thrombosis should be considered.

We thank Drs. G. Hieshima and E. Helmer for their assistance and interpretation of the radiographic findings. We also thank Maryann McCarthy for her clerical assistance.

References

- [1] Volpe JJ. Neonatal seizures. *N Engl J Med* 1973;289(8):413-6.
- [2] Marciniak E, Wilson HD, Marlar RA. Neonatal purpura fulminans: A genetic disorder related to the absence of protein C in blood. *Blood* 1985;65(1):15-20.
- [3] Scotti LN, Goldman RL, Hardman DR, Heinz ER. Venous thrombosis in infants and children. *Radiology* 1974;112:393-9.
- [4] Imai WK, Everhart FR, Sanders JM. Cerebral venous sinus thrombosis: Report of a case and review of the literature. *Pediatrics* 1982;70:965-70.
- [5] Cowan F, Thoresen M. Changes in superior sagittal sinus blood velocities due to postural alterations and pressure on the head of the newborn infant. *Pediatrics* 1985;75(6):1038-47.
- [6] Newton TH, Gooding CA. Compression of superior sagittal sinus by neonatal calvarial molding. *Radiology* 1975;115:635-40.
- [7] Patronas NJ, Duda EE, Mirfakharee M, Wollman RL. Superior sagittal sinus thrombosis diagnosed by computed tomography. *Surg Neurol* 1981;15(1):11-4.
- [8] Zilkha A, Daiz AS. Computed tomography in the diagnosis of superior sagittal sinus thrombosis. *J Comput Assist Tomogr* 1980;4(1):124-6.
- [9] Go RT, Chiu CL, Neumann LA. Diagnosis of superior sagittal sinus thrombosis by dynamic and sequential brain scanning: Report of one case. *Neurology* 1973;23:1199-204.
- [10] Barnes BD, Brant-Zawadzki M, Mentzer W. Digital subtraction angiography in the diagnosis of superior sagittal sinus thrombosis. *Neurology* 1983;33:508-10.
- [11] Hanigan WC, Rossi LJ, McLean JM, Wright RM. MRI of cerebral vein thrombosis in infancy: A case report. *Neurology* 1986;36:1354-6.
- [12] Gettelfinger DM, Kokmen E. Superior sagittal sinus thrombosis. *Arch Neurol* 1977;34:2-6.
- [13] Castaigne P, Laplane D, Bousser MG. Superior sagittal sinus thrombosis. *Arch Neurol* 1977;34:788-9.